



Outcome analysis of endoscopic skull base surgery: An institutional experience

Authors

Mishra Sarita Kumari¹, Singh Rakesh Kumar^{2*}, Sinha Richi³, Sharma Vandana⁴
Roy Ansuman⁵

Department of Otorhinolaryngology, Indira Gandhi Institute of Medical Sciences, Patna, India

*Corresponding Author

Singh Rakesh Kumar

Professor and Head, Department of Otorhinolaryngology, Indira Gandhi Institute of Medical Sciences, Sheikhpura, Patna, India Zip code: 800014

Email: rkstent5@gmail.com, Mobile: +91 7781912005

Abstract

Endoscopic skull base surgery is one of the striking advancement in the field of Otolaryngology and Neurosurgery. It significantly improved the surgical outcome of the lesion of anterior skull base with minimum mortality and morbidity. Hence, this method is now a day's included as major surgical outfit in most of the high-grade institutions of the world. Here we are sharing our institutional experience of endoscopic skull base surgery of various lesions of the anterior skull base.

Keywords: *Endoscopic, skull base, outcome.*

Introduction

The base of skull is one of the most inaccessible anatomical regions in human body. Traditionally the lesions of this area were managed by neurosurgeons via various open transcranial approaches, which often required extensive neurovascular manipulation often associated with significant morbidity and mortality. After invention of nasal endoscopic system, related instruments and the better understanding of various corridors through which, one can easily reach at, below or above the skull base. The menacing and terrifying thought to treat these lesions has become much easier. However, performing surgery for skull base lesions with favourable outcome requires a team effort of both otolaryngologist and neurosurgeon. Here we are sharing our institutional experience of endoscopic skull base surgery of various lesions in this region.

Material and Methods

In this study retrospective data analysis was done for all the patients with anterior skull base lesion, who were operated via extended endoscopic approach during March 2017 to March 2018 at the Department of ENT, Indira Gandhi Institute of Medical Sciences, Patna. There were total of 17 cases that include 1 case of frontal lobe meningioma, 3 cases of meningoencephalocele, one craniopharyngioma, two macroadenoma of pituitary, one CSF Rhinorrhoea and 9 cases of angiofibroma with intracranial extension.

All these cases were operated using rigid nasal endoscope and high definition spine camera manufactured by Karl Storz, Germany. In all cases navigation system was not used.

For meningoencephalocele nasal part was excised with Arthocare, USA, made coblation system. The defect was identified and was closed with fat,

cartilage and Hadad’s flap. Similar technique was applied to close the cribriform defect for CSF rhinorrhoea. Two cases of pituitary adenoma and craniopharyngioma were excised using Transnasal- transsphenoidal approach with two nostril four hand technique. Post excision repair was done using abdominal fat and Hadad’s flap. The angiofibromas were accessed via modified Denker’s approach and were dissected out using cobaltor. In most of the cases of angiofibroma with intracranial extension, the vidian canal, cavernous sinus and part of middle cranial fossa were involved. Most of the cases were of Fish’s stage III, the prior operative embolization was not done in any cases. However, the maxillary artery were cauterised in pterygo-palatine fossa in each and every cases. All these procedures were done by using Karl Storz made endoscopic system and Coblator. The average blood loss in angiofibroma

surgery was found to be 600 ml. The recurrence of three cases of angiofibroma was noted in the follow up period of six months.

Results

There were 2 females and 15 male patients included in our study. The age group ranged from 15 to 56 years with an average of 35.5 years. The extended endoscopic approach was utilized to excise all the lesions in anterior skull base. Complete excision of all the lesions was achieved, which was confirmed by post operative radiological studies. [fig-1,2] There were no complications like CSF rhinorrhoea, vision loss, meningitis or excessive bleeding; however one patient of frontal lobe meningioma had anosmia post operatively. Among patients of angiofibroma 3 of them had a recurrence during the follow up period of 1 year.

Table -1 presents the summary of results obtained in this study.

Diagnosis	No of Patient	Age	Sex	Clinical feature	Surgical approach	Complications
Meningioma	1	19	M	Headache	Trans nasal trans cribriform endoscopic	Anosmia
Meningoencephalocele	3	16 21 25	M M M	Recurrent meningitis	-do	None
CSF rhinorrhoea	1	56	F	Watery nasal discharge	do	None
Pituitary macroadenoma	2	45 53	M F	Headache, blurring of vision	Trans nasal -trans sphenoidal	None
Craniopharyngioma	1	40	M	Headache	Trans nasal -trans sphenoidal	none
Angiofibroma	9	15- 20	M	Nasal bstruction & bleeding	Trans nasal endoscopic Modified Denker’s	Recurrence of lesion in 3 cases

Figure:-1 pre and post operative MRI showing complete removal of pituitary adenoma

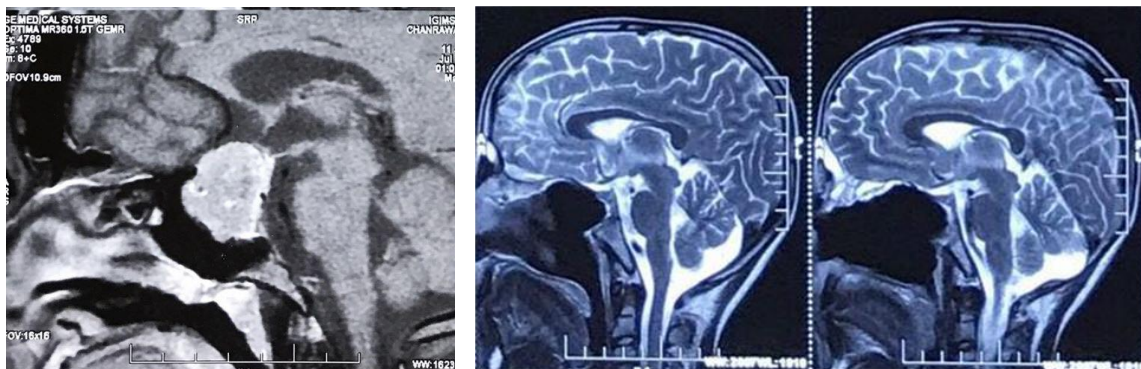
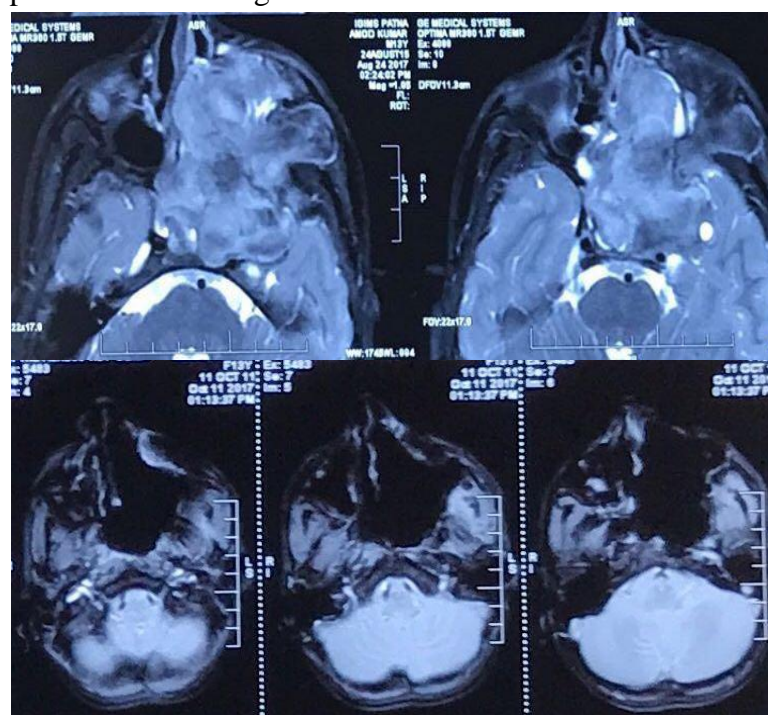


Figure -2 pre and post operative MRI of angiofibroma

Discussion

The evolution of endoscopic skull base surgery is closely associated with development of techniques for removal of pituitary adenomas. The first report of transphenoidal excision of pituitary adenoma was given by Schloffer et al in 1906.^[1] Cushing described the sublabial trans-septal trans sphenoidal approach to avoid facial scar.^[2] Cushing's technique was perfected by Hardy with introduction of microscope in 1962.^[3] With development of endoscopic system and instruments and better understanding of different trans nasal corridors in recent years the endoscopic approach has become the most preferred. In 1992 Jankowski proposed the first fully endoscopic approach for pituitary adenoma excision.^[4] Earlier there were reservations regarding the endoscopic approach for fear of infection as the nasal cavity is unsterile but these concerns have been proved futile. Even though the microscopic approach provides a good depth perception the field of vision is very narrow tunnel vision which can result in incomplete resection of tumor and also injury to vital structure in the lateral aspect. The endoscope provides a more panoramic view and use of angled

scope can further facilitate visualisation. Gao et. al. in their study also concluded that endoscopic transphenoidal approach is safer than microscopic approach for pituitary adenoma surgery.^[5]

Jho and Carrau, a neurosurgeon and otorhinolaryngologist, respectively, from the University Of Pittsburgh Medical Centre, are widely recognized as the pioneers of the pure endoscopic endonasal approach for the treatment of pituitary adenomas. They started using the endoscope as an adjunct to the microscopic technique, and then moved on to a pure endoscopic technique. In 1997, they reported a study of 50 patients who were treated through a pure endoscopic approach.^[6]

In more recent times advancement in technology of endoscopes and accessories has facilitated development of the "Extended Endoscopic Approaches". Giorgio Frank and Ernesto Pasquini, a neurosurgeon and an otorhinolaryngologist, respectively, from Bologna, developed the ethmoid-pterygoid-sphenoid (EPS) endoscopic approach for the treatment of cavernous sinus lesions. They have also applied the pure endoscopic technique for resection of

suprasellar lesions, performing an extended transplanum sphenoidale approach.^[7,8]

The most common complication associated with skull base surgery is CSF rhinorrhoea which can be repaired endoscopically using various free and pedicled flaps. In 2006 Gustavo Hadad, Luis Bassagasteguy of Argentina described a neurovascular septal mucoperiostum and mucoperichondrium flap based on the nasoseptal artery, a branch of posterior septal artery.^[9] In our study also we have used the same septal flap for reconstruction of skullbase defects and there were no incidence of CSF leak post operatively.

Endoscopic excision of juvenile nasopharyngeal angiofibromas needs special consideration because of its nature of extension into infratemporal fossa, orbit and cavernous sinus. Endoscopic approaches can easily be applied for excision of even large angiofibromas. Onceri et.al. in their study in 2003 have concluded that endoscopic techniques can be used with good results for both low and high stage tumours (minimal intra cranial extension) with limitation being extension into cavernous sinus and extensive extension to middle cranial fossa where combined approach will be more successful.^[10] In our study also we were able to completely excise tumours extending into infratemporal fossa and extra dural spread to middle cranial fossa.

Pre operative embolization in case of angiofibroma has been advocated to reduce blood during surgery but there are certain limitations to this view. In a country like ours where advanced radiological facilities are not readily available the feasibility and cost also becomes a limiting factor. There has been report of blindness due to inadvertent embolization of retinal artery^[11]. Following good surgical technique and use of Coblator for dissection reduces the incidence of blood loss. In our study none of the patients with angiofiroma had intraoperative bleeding more than 600 ml and no post operative blood transfusion were required.

Conclusion

Skull base surgery is now a days the most rapidly advancing surgical speciality in the field of otolaryngology and neurosurgery; it is now the most preferred approach do treat lesions of anterior skull base with minimal morbidity. Advent of accessories like navigation and USG Doppler have made the approach even safer. In our study also we have found that the endoscopic approach to skull base gives better results without major complications.

References

1. Schloffer H: Zur Frage der Operation en an der Hypophyse. Beitr Klin Chir 50:767, 1906
2. Cushing H: Partial hypophysectomy for acromegaly: With remarks on the function of the hypophysis. Ann Surg 50: 1002, 1909
3. Hardy J: Transsphenoidal removal of pituitary adenomas. Union Med Can 1962, 91:933- 945.
4. Jankowski R, Auque J, Simon C, Marchal JC, Hepner H, Wayoff M: Endoscopic pituitary tumor surgery. Laryngoscope 1992, 102:198–202.
5. Gao et al. Endoscopic versus microscopic transsphenoidal pituitary adenoma surgery: a meta-analysis World Journal of Surgical Oncology 2014, 12:94.
6. Carrau RL, Jho HD, Ko Y: Transnasal-transsphenoidal endoscopic surgery of the pituitary gland. Laryngoscope 106:914–918,1996.
7. Frank G, Pasquini E: Approach to the cavernous sinus, in de Divitiis E, Cappabianca P (eds): Endoscopic Endonasal Transsphenoidal Surgery. Wien: Springer-Verlag, 2003, pp 159–175
8. Cappabianca P, Frank G, Pasquini E, de Divitiis O, Calbucci F: Extended endoscopic endonasal transsphenoidal approaches to the suprasellar region, planum sphenoidale and clivus, in de

- Divitiis E, Cappabianca P (eds): Endoscopic Endonasal Transsphenoidal Sugery. Wien: Springer-Verlag, 2003, pp 176–187.
9. Gustavo Hadad, Luis Bassagasteguy, Ricardo L. Carrau, Juan C. Mataza , Amin Kassam, Carl H. Snyderman, Arlan Mintz, Laryngoscope Volume116, Issue 10, October 2006 Pages 1882-1888.
10. T. Metin Önerci, Ö. Taşkın Yücel, Oğuz Öğretmenoğlu, Endoscopic surgery in treatment of juvenile nasopharyngeal angiofibroma, International Journal of Pediatric Otorhinolaryngology (2003) 67, 1219—1225
11. Alireza Ramezani, Hamidreza Haghghatkhah, Habibollah Moghadasi, Morteza S Taheri, and Hiva Parsafar A case of central retinal artery occlusion following embolization procedure for juvenile nasopharyngeal angiofibroma Indian J Ophthalmol. 2010 Sep-Oct;58(5):419–421.