



Results of displaced radial neck fractures in children treated by Intramedullary elastic nail

Authors

Mohd Iqbal Wani, Hilal Ah Kotwal, Raja Rameez Farooqi

Postgraduate Department of Orthopaedics, Govt. Medical College Srinagar J&K, India

Abstract

Objective: The aim of this study was to report the clinical and radiological results of patients having displaced Judet type 3 radial neck fracture of and fixed with intramedullary elastic nail within 24 hours of trauma.

Methods: There were a total of 15 patients with Judet type 3 severely displaced radial neck fracture. The mean age of the study group was 9.32 years, ranging from 7 to 11 years. Females constituted 60% of the study group. Closed reduction was achieved by Metaizeau technique using percutaneous K-wire in all cases and fixation done with elastic intramedullary nail passed from distal end of radius. Patients were followed at regular intervals to look for fracture healing and complications if any. Functional evaluation was done at the end of 12 months by elbow range of motion and Mayo Elbow Performance Score (MEPS).

Results: The mean MEPS score increased from 20 points preoperatively to 90 points postoperatively (range, 12 to 95 points). Radiological evaluation revealed that all fractures healed with excellent or good alignment. At the final follow up, mean flexion was 145 degree (range, 140 to 150), extension 2 degree (range, 0 to 4), supination 82 degree (range, 80 to 90), and pronation 84 degree (range, 80 to 90).

Conclusion: Reduction and osteosynthesis of radial neck fractures by intramedullary nailing with the help of percutaneous K-wire manipulation appears to be a simple, safe and effective treatment method in children.

Level of evidence: Level IV, Therapeutic study.

Introduction

Radial head and neck fractures represent only 1 to 5% of all pediatric elbow fractures^[1]. The highest prevalence is between 9 and 12 years^[2]. They are mostly caused by fall on the outstretched arm with the elbow extended. Displaced radial neck fractures with severe angulation need to be reduced to achieve optimum results^[1 2 3 4 7 8 14]. Reduction can be achieved either with manipulation with hand or percutaneous Kirschner wires or with open means in difficult and

comminuted fractures^[5,6]. Intramedullary fixation using technique ESIN technique was described by Metaizeau in 1993^[7,8]. The aim of our study was to report the clinical and radiological results of displaced radial neck fractures (Judet type 3) treated with intramedullary elastic nailing after closed reduction by percutaneous K-wire (Metaizeau technique).

Material and Methods

Between January 2014 and November 2015, 15 children with isolated Judet type 3 radial neck fractures of the extremity were treated by Intramedullary elastic nail at Bone and Joint Hospital Srinagar Kashmir (Table 1). According to Judet classification system, type 3 fractures are those fractures where the angle between a line perpendicular to the articular surface of the radial head and a line drawn through the center of the radial shaft make an angle of 30 to 60 degrees (Fig. 1)^[9,10]. The mean angulation in our group was 48 degree (range, 40 to 57). However all the fractures were either type 1 or 2 based on Salter Harris classification of epiphyseal injuries. All the children in our study had fracture due to fall on an outstretched arm. There were 6 boys and 9 girls with a mean age of 9.32 (range, 7-11 years). The fractures were more common on the left side (60%) compared to right side (40%). All fractures were caused by falling onto outstretched arm from a height. Any of the patient with associated fracture around ipsilateral elbow were not taken up for the study and hence excluded. None of the patients in the study group had associated fracture around the ipsilateral shoulder and wrist region.

All the patients were operated under general anesthesia within 24 hours of trauma. Reduction of the displaced radial head was performed with the help of percutaneous K-wire. Using the standard technique, fixation was done with elastic intramedullary nail passed from distal radius just 2 cm proximal to the physis. The reduction and fixation was checked under fluoroscopy and any adjustment whatever necessary was done before skin closure. The forearm was immobilized in supination in a cast padding for 2 weeks after which elbow mobilization exercises were started. The patients were followed up at 1 week, 2 weeks, 6 weeks, 12 weeks and thereafter at 3- monthly intervals with the final follow up at 12 months. Nail was removed at a mean time of 24 weeks (range, 20 to 28 months). Any possible complication was documented. The final follow up was done to assess elbow passive and active

range of motion (ROM) by goniometer and functional results using Mayo elbow performance score (MEPS)^[11]. The reduction was considered excellent when it healed in the anatomical position, and good when the radial neck angle was less than 20.

Table 1

Patient characteristics in the study group	
Mean Age (years)	9.32 (range 7 -11)
Male /Female	6:9
Right /Left	6:9
Mean Angulation	48 degree
Mean MEPS	20

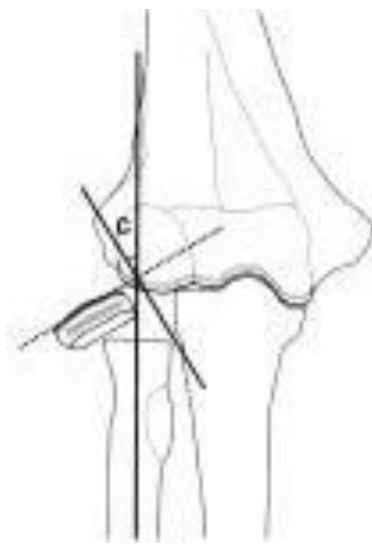


Fig 1 Demonstrates the method to calculate the angular deformity in radial neck fracture

Results

The mean MEPS score was increased from 20 points preoperatively to 90 points postoperatively (Table 2). According to MEPS, 11 patients had excellent, 4 patients had good clinical results. All fractures healed in excellent and good alignment. ROM evaluation is reported that the mean flexion was measured 145 degree (range, 140 to 150), extension was measured 2 degree (range, 0 to 4), supination was measured 82 degree (range, 80 to 90), pronation was measured 84 degree (range, 80 to 90). No patients had possible complications such as nonunion, avascular necrosis, infection, posterior interosseous nerve (PIN) injury, heterotopic ossification or radioulnar synostosis.

Table 2

Post operative results of the study group	
Mean MEPS	90 points
Excellent (>90 Points)	11 (73%)
Good (75 -89 Points)	4 (27%)
Mean Angulation	48 degree

Discussion

Fractures of the radial head or neck usually occur as a result of fall onto an outstretched hand with the elbow in extension and valgus. The techniques of fixation vary from simple immobilization to open reduction and internal fixation^[12,13]. Most of the authors agree that less than 30 angulation and 2 mm translation is acceptable at any age for the conservative treatment. However more than 60 angular deformity is not acceptable at any age thus requiring surgery. Between 30 and 60, opinion varies as there is no consensus of the best treatment modality^[14,15,16]. Vocke et al reported that conservatively treated radial neck fractures with an angulation up to 50 in children under the age of 10 are corrected spontaneously^[17]. However, Al-Aubaidi et al found excellent results with surgical reduction and fixation in patients with an angulation over 30^[18]. Similarly we also found excellent results by surgical intervention of judet type 3 radial neck fractures with an angular deformity of 40 to 57 degree. It is clear that the Metaizeau technique has reduced the need for open reduction and internal fixation^[7,8,14,19]. Although it is stated i that percutaneous K-wire manipulation could damage to the proximal radial physis^[3], we did not have any complication about the physeal damage after lever arm manipulation by K-wire. All patients in our study had excellent or good results which are in line with the literature^[2 4 5 8].

The head of the radius and its blood supply can be damaged by the injury itself and by surgical manipulation such as in open reduction. Hence, most of the surgeons do not prefer open reduction to prevent avascular necrosis of the radial head^[5]. Most of the studies have reported higher rates of avascular necrosis, premature epiphyseal fusion

and heterotopic ossifications after open reduction compared to closed reduction^[4,20]. Similarly, Aubaidi et al^[18] reported inferior results in those cases managed by open reduction. In our study none of the patients needed open reduction. Any residual tilt more than 20 degrees is related with the poor outcomes, which could affect functional results adversely. None of our patients had angular deformity of more than 20 degrees. In our study, all reductions were anatomical giving us excellent results in most of the patients. Radial neck fracture as such is rare than common injuries around elbow. Hence the small number of patients may be the limitation of our study. Nevertheless, the results are agreed with the current literature and hence may contribute to the published literature on management of radial neck fractures.

Conclusion

Results of this study showed that closed reduction and distal intramedullary nail fixation of the radial neck fractures in children were in line with the literature by clinically and radiologically. We thought that flexible intramedullary nailing in radial neck fractures was a good option with the simple and reliable application in children.

References

1. Prathapkumar KR, Garg NK, Bruce CE. Elastic stable intramedullary nail fixation for severely displaced fractures of the neck of the radius in children. *J Bone Jt Surg Br.* 2006 Mar;88(3):358e361.
2. Gagliardi Ida C, Mouraria GG, Funayama B, Kikuta FK, Cruz MA, Zoppi A. Evaluation of children with radial neck fractures treated with flexible intramedullary nail. *Acta Ortop Bras.* 2016 MareApr;24(2):81e84.
3. Ugutmen E, Ozkan K, Ozkan FU, Eceviz E, Altintas F, Unay K. Reduction and fixation of radius neck fractures in children with intramedullary pin. *J Pediatr Orthop B.* 2010 July;19(4):289e293.

4. Ursei M, Sales de Gauzy J, Knorr J, Abid A, Darodes P, Cahuzac JP. Surgical treatment of radial neck fractures in children by intramedullary pinning. *Acta Orthop Belg.* 2006 Apr;72(2):131e137.
5. Tarallo L, Mugnai R, Fiacchi F, Capra F, Catani F. Management of displaced radial neck fractures in children: percutaneous pinning vs. elastic stable intramedullary nailing. *J Orthop Traumatol.* 2013 Dec;14(4):291e297.
6. Steele JA, Graham HK. Angulated radial neck fractures in children. A prospective study of percutaneous reduction. *J Bone Jt Surg Br.* 1992 Sep;74(5): 760e764.
7. Metaizeau JP. Reduction and osteosynthesis of radial neck fractures in children by centromedullary pinning. *Injury.* 2005 February;36(suppl 1):75e77.
8. Metaizeau JP, Lascombes P, Lemelle JL, Finlayson D, Prevot J. Reduction and fixation of displaced radial neck fractures by closed intramedullary pinning. *J Pediatr Orthop.* 1993 MayeJun;13(3):355e360.
9. Judet J, Judet R, Lefranc J. Fracture of the radial head in the child. *Ann Chir.* 1962 Sep;16:1377e1385.
10. Judet H, Judet J. Fractures and orthopedique de l' enfant. Paris: Maloine; 1974: 31e39.
11. Morrey BF, An KN, Chao EYS. Functional evaluation of the elbow. In: Morrey BF, ed. *The Elbow and Its Disorders.* 2nd ed. Philadelphia: WB Saunders; 1993: 86e89.
12. Cossio A, Cazzaniga C, Gridavilla G, Gallone D, Zatti G. Paediatric radial neck fractures: one-step percutaneous reduction and fixation. *Injury.* 2014 Dec;45(suppl 6):80e84.
13. Radomisli TE, Rosen AL. Controversies regarding radial neck fractures in children. *Clin Orthop.* 1998 August;353:30e39.
14. Pring ME. Pediatric radial neck fractures: when and how to fix. *J Pediatr Orthop.* 2012 Jun;32(suppl 1):14e21.
15. Schmittenebecher PP, Haevernick B, Herold A, Knorr P, Schmid E. Treatment decision, method of osteosynthesis, and outcome in radial neck fractures in children: a multicenter study. *J Pediatr Orthop.* 2005 JaneFeb;25(1):45e50.
16. Pring ME, Wenger DR, Rang M. Elbowdproximal radius and ulna. In: Rang M, Pring ME, Wenger DR, eds. *Rang's Children's Fractures.* Philadelphia: Lippincott Williams & Wilkins; 2005:119e134.
17. Vocke AK, Von Laer L. Displaced fractures of the radial neck in children: longterm results and prognosis of conservative treatment. *J Pediatr Orthop B.* 1998 July;7(3):217e222.
18. Al-Aubaidi Z, Pedersen NW, Nielsen KD. Radial neck fractures in children treated with the centromedullary Metaizeau technique. *Injury.* 2012 Mar;43(3): 301e305.
19. Okcu G, Aktuglu K. Surgical treatment of displaced radial neck fractures in children with Metaizeau technique. *Ulus Travma Acil Cerrahi Derg.* 2007 April;13(2): 122e127.
20. Tan BH, Mahadev A. Radial neck fractures in children. *J Orthop Surg (Hong Kong).* 2011 Aug;19(2):209e212.