



The effect of Pterygopalatine Canal Injection with Local Anaesthetic and Adrenaline on Bleeding during Functional Endoscopic Sinus Surgery

Authors

Rohit Bhardwaj, MS¹, Gul Motwani, MS², Rajeev Kumar Verma³,
Ms Namrata Yadav⁴, Sandeep Trehan⁵

^{1,4,5}Junior Resident, Department of Otorhinolaryngology, VMMC and Safdarjung Hospital,

²Professor & Head, Department of Otorhinolaryngology, VMMC and Safdarjung Hospital

³Senior Resident, Department of Otorhinolaryngology, VMMC and Safdarjung Hospital

New Delhi-110029, India

Corresponding Author

Dr Rajeev Kumar Verma

Krashi Upaz Mandi Roadm Srimadhpor, Distt. Siker (Rajasthan) India

Email: drrajeevkumar85@gmail.com, Mob: 08802317004

Abstract

Introduction: Control of bleeding is important for a safe and effective procedure, as it improves visualization of intranasal anatomy & decreases the risk of complications. Mucosal bleeding is increased in presence of inflammation as seen in chronic rhino-sinusitis during FESS. This study was done to assess the effect of pterygopalatine canal injection with xylocaine and adrenaline on intraoperative surgical field bleeding, surgery duration & overall blood loss during FESS in comparison to opposite side.

Methods: Prospective single blind randomized controlled trial was performed including 30 patients in a tertiary care Centre. Symmetrical chronic rhinosinusitis (based on Lund-Mackay CT Scoring) patients, undergoing FESS were included. Each served his/her own control since injection containing 2 mL of xylocaine with 1:100000 adrenaline was injected in pterygopalatine canal on one side only. Injection side was decided by lottery method for which operating surgeon was kept blind. Surgical field bleeding graded every 15 minutes based on 6 point scale used by Boezaart et al. Surgery was completed on one side first. Total blood loss, surgery duration was computed separately for both sides.

Results: 29 out of 30 patients showed beneficial results of pterygopalatine block in terms of improvement in intra operative surgical field bleeding, reducing surgery time & overall blood loss. Average bleeding grade at 45 and 60 minutes on control arm represented by median (interquartile range) 3 (3-3) & 3 (2-3) respectively and on intervention arm 2 (2-2) & 2 (2-2) having P value of < 0.0001 for both is statistically significant. Surgery time in intervention arm showed significant improvement in comparison with control side having p value of 0.007. Improvement was noted in overall blood loss favoring intervention arm (p value < .0001).

Conclusion: Injection of the pterygopalatine canal resulted in improvement in surgical field bleeding, shortened surgery time and reduced overall blood loss in intervention arm.

Keywords: Pterygopalatine Canal, Bleeding, FESS, Adrenaline, Local Anaesthetic, Rhinosinusitis, Surgery Duration.

Introduction

Chronic rhinosinusitis (CRS) is a group of disorders characterized by inflammation of the mucosa of the nose and para nasal sinuses of at least 12 consecutive weeks duration. Medical treatment used in chronic rhinosinusitis includes allergen and/or irritant avoidance, douching, corticosteroids, decongestants, antibiotics, antileukotrienes, aspirin, immunotherapy. Functional endoscopic sinus surgery (FESS) is the treatment of choice for chronic rhinosinusitis when maximal medical treatment fails. Nasal cavity and paranasal sinuses have a rich blood supply derived from the terminal branches of the maxillary artery and ethmoidal arteries. Control of bleeding during FESS is of primary importance for a safe and effective procedure, because mucosal bleeding may compromise visualization of the intranasal vital structures. The risk of complications like Skull base injury, orbital penetration with possible damage to the extra-ocular muscles and the optic nerve, intracranial injury, chances of post-operative synechiae formation and re-obstruction of sinus ostia increases when there is poor visualisation of surgical field due to excessive bleeding.¹ Various methods have been tried to reduce intra operative bleeding during FESS like induced hypotension with sodium nitroprusside, use of preoperative nasal decongestion with oxymetazoline, phenylephrine hydrochloride and cocaine, elevation of the patient's head (15-degree reverse Trendelenburg position) to reduce the venous return, use of bipolar cautery, premedication with beta blockers, intravenous anaesthesia to achieve controlled hypotension.²⁻⁶ Even with the use of all these techniques some patients still have significant amount of bleeding during FESS. This study aims to assess the effect of pterygopalatine canal injection with xylocaine and adrenaline on intraoperative surgical field bleeding and overall loss during FESS by inducing vasoconstriction of sphenopalatine artery.

Materials and Methods

Total 30 patients who had symmetrical disease were included in the study. The disease symmetry was determined based on CT findings as per Lund- Mackay CT Scoring.⁷ All of them were more than 18 years of age. Patients with a difference of three or less points between two sides were considered to have symmetric disease and were included. Study design: A prospective, single blinded, randomised controlled study was performed after obtaining Ethical clearance certificate from ethics committee of the institute from October 2015 to march 2017.

All the patients were subjected to Endotracheal balanced general anaesthesia. The greater palatine foramen was identified by using a ball probe 3-5 mm anterior to the junction of the hard and soft palate near molar tooth. Using the technique described by Mercuri, the pterygopalatine infiltration was performed.⁸ A needle was inserted in the pterygopalatine canal at a depth of 10-25 mm and an angle of 45 degree.⁹ Xylocaine (2ml of 2%) with 1:100000 adrenaline was injected into the pterygopalatine canal on one side which was decided with Lottery method. The other side was not injected which served as the control. All injections were performed by co-investigator. The sphenopalatine canal & agger nasi region was infiltrated with xylocaine and adrenaline on both sides. Surgery was started on injected side after 2 minutes of xylocaine and adrenaline infiltration. Surgeon evaluating the bleeding was blinded about the side of injection. The operating surgeon estimated the intensity of bleeding in the operative field every fifteen minutes according to the 6 point scale used by Boezaart et al¹⁰ (Table 1). Surgery on the first side was completed prior to starting surgery on the second side. All blood loss was collected and total blood loss was recorded on each side separately. Total blood loss was calculated by subtracting the amount of fluid used for wash and fluid used in microdebrider from total collection in suction jars. Surgery was started on the other side after installing new collection jars and the collections were calculated at

commencement of surgery. Comparison was done for both the sides.

Statistical analysis was done using Statistical Package for Social Sciences (SPSS) version 21.0.

Results

Total 30 patients were included (17 males and 13 females). The Age of patients participating in study ranges from 19 to 58 years (mean age 36.5 year). Surgical field bleeding grade at 45 min and 60 minutes showed statistically significant improvement in favor of intervention. Average bleeding grade at 45 minutes on control arm median (interquartile range) 3 (3-3) & on intervention arm median (interquartile range) 2 (2-2) having P value < 0.0001 is statistically significant and at 60 minutes on control arm median (interquartile range) 3 (2-3) & on

intervention arm median (interquartile range) 2 (2-2) having P value < 0.0001 is also statistically significant.

The difference in overall blood loss during surgery ranges from 20 ml to 110 ml. Mean (Std. Deviation) blood loss in intervention arm is 72.6 (±23.1) mL and in the control arm is 101.6 (±29.8) mL this difference is highly statistically significant (p value <.0001) (Table 2) The difference in surgical time ranges from 2 minutes to 30 minutes. Mean (Std. Deviation) time of surgery in intervention arm is 93.9 (±17.8) minutes and in the control, arm is 107 (±18.6) minutes. This difference is statistically significant (p value- 0.007) (Table 2) Improvements in all three parameters were noted in 96.67% (29 out of 30 patients) on the side of pterygopalatine block.

Table 1: Scale for intensity of bleeding used by Boezaart et al

Grade	Description
0	No bleeding
1	Slight bleeding-no suctioning required
2	Slight bleeding-occasional suctioning required
3	Slight bleeding-frequent suctioning required, bleeding threatens surgical field a few seconds after suction is removed.
4	Moderate bleeding-frequent suctioning required bleeding threatens surgical field directly after suction is removed.
5	Severe bleeding- constant suctioning is required, surgical field severely threatened (bleeding appears faster than it can be removed by suction) & surgery usually is not possible.

Table 2: Total blood loss & duration of surgery in side with block comparing with control..

	Control side	Side with Pterygopalatine block
Sample size	30	30
Total blood loss (mL)	101.67 ± 29.84	72.6 ±23.1
Surgery time (minutes)	107 ± 18.68	93.9 ± 17.85

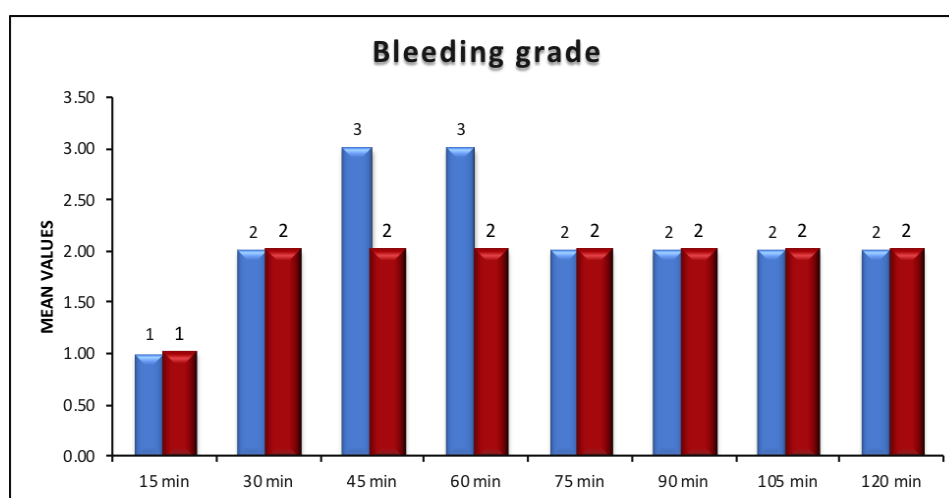


Figure 1: Comparing bleeding trends on the side with Pterygopalatine block with control side.

Discussion

For FESS to be effective, it is very important that a surgeon gets good visualisation of the surgical field throughout the surgery duration. Deterioration in surgical field quality because of bleeding has been shown to lengthen the procedure and may increase the risk of operative complications¹¹. Various methods have been tried to achieve this. This study aimed to see the effect of the pterygopalatine canal injection with local anesthetic (2% xylocaine) and 1:100000 adrenaline on bleeding during FESS. Study also assessed effect of the same on surgical field bleeding and overall surgery duration. To avoid side effects like risk of injury to the orbital contents, infraorbital nerve injury and anesthesia of the orbital nerves and intravascular injection in maxillary artery. Injection in pterygopalatine canal were given based on previously mentioned technique. This study finds a significant difference in surgical field bleeding, surgery duration and overall blood loss, favoring the injection side. Surgical field bleeding showed significant difference at 45 & 60 minutes duration whereas it remained comparable during rest of the times. The overall surgical field bleeding showed improvement on intervention arm with p value of <0.0001 for both at 45 minutes and 60 minutes. Surgery duration was also shortened by injection on intervention arm, and proved statistically significant with a p value of 0.007. The overall blood loss was also less on injection side Mean (Std. Deviation) is 72.6 (\pm 23.1) mL and in the control arm is 101.6 (\pm 29.8) mL This also proved statistically significant results having p value <.0001 favoring injection side. This study supports the concept of pterygopalatine canal injection with local anesthetic and adrenaline prior to FESS. Pterygopalatine fossa infiltration has been a method used in different procedures, including FESS, septorhinoplasty and dental regional anaesthesia.¹² A study published by Wormald PJ et al. also supports injecting pterygopalatine canal with xylocaine and adrenaline to see an improved surgical field

during endoscopic sinus surgery.¹³ Another study was done by Bhardwaj VK, Novonty GM regarding greater palatine canal injection as an alternative to posterior nasal packing and arterial ligation in epistaxis and showed result favoring the procedure.¹⁴ Gurr P et al. did a study a study in which Laser Doppler blood flowmetry measurement of nasal mucosa blood flow after injection of the greater palatine canal with 2 ml of a 0.5 per cent bupivacaine hydrochloride solution was done. They conjectured that it resulted in reduction of blood flow to the inferior turbinate.¹⁵ Although C J Valdes et al. conducted a prospective, single blinded, controlled trial using unilateral fossa injection with 1% xylocaine and 1:100000 adrenaline and concluded that pterygopalatine fossa injection prior to functional endoscopic sinus surgery did not decrease intra-operative surgical field bleeding, blood loss or duration of surgery.¹⁶

Conclusion

Presently, there are not much published studies that evaluate the role of pterygopalatine fossa injection in FESS. This study indicates that pterygopalatine fossa infiltration prior to FESS does improve intra-operative surgical field bleeding grade, decreases blood loss & shortens surgery duration and if performed carefully there are not much significant side effects due to the procedure.

"Compliance with Ethical Standards"

Funding sources: None

Conflict of interests: all authors declares that they have no conflict of interest.

Ethical approval: All procedures performed in studies involving human participants were in accordance with the ethical standards of the institutional and/or national research committee and with the 1964 Helsinki declaration and its later amendments or comparable ethical standards.

Reference

1. Stankiewicz JA. Complications of endoscopic sinus surgery. *Otolaryngol Clin North Am* 1989;22:749–58
2. Saitoh K, et al. Induced hypotension for endoscopic sinus surgery. *Masui* 51:1100–1103, 2002
3. Riegle EV, Gunter JB, Lusk RP, et al. Comparison of vasoconstrictors for functional endoscopic sinus surgery in children. *Laryngoscope* 102:820–823, 1992.
4. Hatho'n IF, Habib AR, Manji J, Javer AR. Comparing the reverse Trendelenburg and horizontal position for endoscopic sinus surgery: a randomized controlled trial. *Otolaryngol Head Neck Surg* 2013; 148:308-13
5. Nair S, Collins M, Hung P, Rees G, Close D, Wormold PJ. The effect of beta-blocker premedication on the surgical field during endoscopic sinus surgery. *Laryngoscope*. 2004 Jun;114(6):1042-6
6. Eberhart LH, Folz BJ, Wulf H, Geldner G. Intravenous anaesthesia provides optimal surgical conditions during microscopic and endoscopic sinus surgery. *Laryngoscope*. 2003 Aug;113(8):1369-73
7. Lund VJ, Kennedy DW. Staging for rhino sinusitis. *Otolaryngol Head Neck Surg* 1997 Sep;117(3 Pt 2):S35-40.
8. Mercuri LG. Intraoral second division nerve block. *Oral Surg Oral Med Oral Pathol* 1979;47:109–13
9. Douglas R, Wormald PJ. Pterygopalatine fossa infiltration through the greater palatine foramen: where to bend the needle. *Laryngoscope* 2006;116:1255–7
10. Peter John Wormald. Endoscopic sinus surgery. 3. New York: Thieme Medical Publishers; 2012
11. Schubert MS. Allergic fungal sinusitis: Pathogenesis and management strategies. *Drugs* 64:363–374, 2002.
12. Lepere AJ. Maxillary nerve block via the greater palatine canal: new look at an old technique. *Anesth Pain Control Dent* 1993;2: 195–7
13. Wormold PJ, Athanasiadis T, Rees G, Robinson S. An evaluation of pterygopalatine fossa injection with local anaesthetic and adrenaline in the control of nasal bleeding during endoscopic sinus surgery. *AmJRhinol* 2005 May-Jun;19(3):288-92
14. Bharadwaj VK, Novotny GM. Greater palatine canal injection: an alternative to the posterior nasal packing and arterial ligation in epistaxis. *J Otolaryngol* 1986;15:94–100
15. Gurr P, Callanan V, Baldwin D. Laser-Doppler blood flowmetry measurement of nasal mucosa blood flow after injection of the greater palatine canal. *J Laryngol Otol* 1996;110:124–8
16. CJ Valdes, Y AL Badaai, M Bogado, M Samaha. Does pterygopalatine canal injection with local anaesthetic and adrenaline decrease bleeding during functional endoscopic sinus surgery? *J Laryngol Otol* 2014 Sep;128(9):814-7.