



## A Study on Characterization of Breast Lesions Using Sonomammography and Comparing with Histopathology

Authors

**Deepa S<sup>1</sup>, Beena Sebastian<sup>2</sup>, Radhamani MV<sup>3</sup>, Divya S<sup>4</sup>, Kiran Ravi<sup>5</sup>**

<sup>1</sup>Senior Resident, Department of Radiodiagnosis, Govt Medical College, Kottayam

<sup>2</sup>Associate Professor, Department of Radiodiagnosis, Govt Medical College, Kottayam

<sup>3</sup>Additional Professor, Department of Obstetrics and Gynaecology, Govt Medical College, Kottayam

<sup>4</sup>Assistant Professor, Department of Community Medicine, Malabar Medical College, Kozhikode

<sup>5</sup>DNB Resident, Department of General Medicine, Baby Memorial Hospital, Kozhikode

Corresponding author

**Beena Sebastian**

Associate Professor, Department of Radiodiagnosis, Govt. Medical College, Kottayam, Kerala

Email: [deepaosler@gmail.com](mailto:deepaosler@gmail.com)

### Abstract

**Introduction:** *The changing lifestyle practices can lead to a higher number of cancer cases. Breast cancer is the most common cancer among women in India. It is very important to identify the palpable breast lump as benign or malignant. Ultrasonography is a commonly used screening imaging modality in breast lumps. The present study aims to find out the accuracy of sonomammography by comparing with histopathology.*

**Materials and Methods:** *A descriptive study was conducted among female patients for one year. It included 75 female patients above 20 years of age with palpable breast lesions and bloody discharge from the nipple. Patients with advanced carcinoma, previously treated cases and patients with history of previous breast biopsy were excluded from the study. Designed as diagnostic test evaluation, sensitivity, specificity, positive predictive value and negative predictive value of the variables in differentiation was calculated comparing with histopathological diagnosis. The features of ultrasonography was analyzed by Cohen's Kappa for statistical agreement with histopathology.*

**Results:** *With sonomammography, the sensitivity, specificity and accuracy obtained were 83.3%, 89.7% and 86.67% respectively for detection of malignancy.*

**Discussion and Conclusion:** *Sonomammography is a very useful non-invasive imaging modality having high sensitivity and specificity in diagnosing breast lesions. This study shows that ultrasonography is useful in characterization of breast masses. The requirement of biopsy for breast masses can be reduced. The kappa values for ultrasonographic diagnosis was 0.732 with P value <0.001 which indicates good agreement with histopathology.*

**Keywords:** *Benign, breast lesion, histopathology, malignant, sonomammography.*

### Introduction

The incidence of cancer is increasing day by day. In a developing country like India, because of the changing lifestyle practices including food habits, environmental and genetic factors, the number of breast cancer cases are higher. The most common cancer among women in India is breast cancer.<sup>(1)</sup>

A palpable breast lump is a very common diagnostic problem. The most important question in the case of a breast lump is whether the lesion is benign or malignant. The field of breast imaging is undergoing a rapid revolution due to improvement in the technology. Ultrasonography is a commonly used screening imaging modality

in breast lumps. It can be used in pregnant females also without the risk of radiation. The development of high frequency probes allow a high degree of accuracy in characterizing breast lumps. It is important to obtain a definitive pre-operative diagnosis because the surgical approach is different in malignant and benign lesions. Breast cancer screening helps to detect cancers at an earlier, more treatable stage, and is an important clinical procedure because approximately one in eight women will develop breast cancer over their lifetimes. The various characteristics studied are as follows:

**The characteristics suggestive of benign lesions are:**

Ellipsoid shape - Most of the small fibroadenomas have smooth, well circumscribed ellipsoid shape, suggesting benignity.

Echogenicity- Hyperechoic masses are generally benign and are confined to subcutaneous fat.

Capsule - Thin, well-circumscribed, echogenic capsule around a solid nodule suggest a benign nature of the lesion. Breast calcifications are small calcium deposits that develop in a woman's breast tissue. Certain types of breast calcifications may suggest early breast cancer. Most of the breast calcifications encountered by radiologists are benign. Radiologists must be able to identify typically benign breast calcifications that do not require biopsy to prevent unnecessary procedures and to reduce patient anxiety<sup>(2-5)</sup>.

**The characteristics suggestive of malignant lesions are:**

Greater anteroposterior diameter- when the lesion is taller than broader (AP diameter more than the transverse diameter), as explained by the fact that generally the benign lesion propagate along the tissue plane whereas the malignant lesion propagate perpendicular to the tissue plane.

Echogenicity -Presence of markedly hypo echoic nodule is characteristic of malignant lesion.

Margins -Angular margins refer to the contour of the junction between the nodule and surrounding tissue. It has highest sensitivity of the individual

findings suggesting malignancy. Presence of many microlobulations on the surface of a solid breast nodule is suggestive of malignancy. Distal shadowing - Shadowing is due to fibroelastic host response elements within the tumor. It is common with scirrhous carcinoma.

Calcifications - Presence of punctate calcifications is suggestive of malignancy although large nodular calcifications are seen in benign lesions like calcified fibroadenoma.

Lucent-centered calcifications may be spiculated, with local thickening, branching, rod-like or angular. In early stages of development, calcifications in the wall of an oil cyst may simulate malignancy<sup>(6)</sup>

Large rod like calcifications may have lucent centers if the ductal secretions undergo peripheral calcification. In general, these calcifications are coarser and larger (usually > 1 mm in diameter) than malignant calcifications. Round and punctate calcifications- Punctate calcifications are spherical calcifications that have well-defined margins. Punctate calcifications usually measure less than 0.5 mm in diameter. Round calcifications are benign spherical calcifications that may vary in size.

Distribution of breast calcifications- Breast calcifications are described in terms of type and distribution and categorized according to the Breast Imaging Reporting and Data System (BIRADS) of the American College of Radiology (ACR).

Invasive ductal carcinoma is the most common type of breast cancer. Ductal carcinomas elicit a desmoplastic reaction that produces fibrosis. In such cases, a hard, palpable mass is commonly found at examination. At US, invasive ductal carcinoma typically manifests as an irregular, hypoechoic mass with or without posterioracoustic shadowing. The second most common type of breast cancer is invasive lobular carcinoma, which accounts for 5%–10% of all malignant breast tumors<sup>(7)</sup>. Invasive lobular carcinoma is thought to arise from the terminal ductules of a breast lobule and invades the normal

breast parenchyma in a single file pattern<sup>(8)</sup>. Due to this pattern of invasion, the tumor often manifests as a subtle area of distortion or asymmetry.

Tubular carcinoma is a low grade, well-differentiated form of ductal breast cancer. Lesions are of ductal origin and are characterized by ductal cells invading normal breast tissue and forming groups in the shape of tubules<sup>(9)</sup>. Although these lesions are occasionally palpable, they more frequently go undetected until a screening test is performed.

Fibroadenoma- Fibroadenoma is one of the commonest benign breast lumps and results from excess proliferation of connective tissue. They characteristically contain glandular and fibrous connective tissue. Fibroadenomas have a spectrum of features from the well circumscribed discrete mass, to the multilobulated mass. They may contain popcorn calcification. Calcification may also present as microcalcification which makes differentiation from malignancy very difficult. On ultrasound they are typically seen as a well-circumscribed, round to ovoid, or macrolobulated mass with generally uniform hypoechogenicity.

Intramammary lymph nodes- are lymph nodes within the breast tissue. In breast imaging, they generally fall into BIRADS II lesions. On ultrasound it is usually detected as a solid reniform lesion which is hypoechoic to the remainder of the breast tissue. A hyperechoic central area resulting from the hilar fat may be seen. Sometimes a nearby blood vessel may be seen with some flow entering the hilum on colour Doppler. Enlargement of the nodes may result from dermatitis, hyperplasia, breast cancer or metastasis<sup>(10,11)</sup>.

Lipoma- On ultrasound it is most often seen as a rounded lesion that is iso-echoic or at times slightly hyperechoic to surrounding fat.

Circumscribed carcinoma- On sonography, lesion appear as hypoechoic oval or round lesion with varying degree of attenuation usually less than that of spiculated carcinoma, some of lesion show internal cystic spaces<sup>(12)</sup>. Margins are usually well

defined but some of margins are irregular or ill-defined, such a lesion should be suspicious for malignancy. Sonographic evaluation reveals area projecting from the wall of the cyst<sup>(13,14)</sup>. USS finding are nonspecific, as they are identical to those from an intracystic papilloma and a blood clot in a cyst<sup>(13)</sup>.

Lymphoma- Primary lymphoma of the breast is rare and secondary involvement is more frequent. The sonographic appearance is most often that of a solid hypoechoic mass which is again non specific and both radiologic and clinical appearance is similar to carcinoma.

Metastasis to the breast- Lymphoma and other hematologic malignancies, melanoma and lung cancer are the three most common blood-borne hematologic sources followed by ovarian cancer, soft tissue sarcomas and other gastrointestinal and genitourinary cancer<sup>(15)</sup>. Breast abscess-

Sonographic features suggestive of a breast abscess include – hypoechoic collection, mostly multiloculated, no vascularity within the collection, acoustic enhancement due to fluid content, an echogenic, vascular rim. Mammographic appearance can mimic carcinoma.

Carcinoma- A very few studies have been conducted regarding sonomammographic findings of benign and malignant breast lesions and assessing how accurately it can be used by comparing them with the findings of the gold standard technique, histopathology. This study is an attempt to evaluate the accuracy of ultrasonogram in characterizing breast lumps and comparing them with clinical findings and correlate them with histopathology results. It is very important to understand the accuracy of sonomammogram as unnecessary and several biopsy can be avoided which itself can be a risk factor for breast cancer. This study has been taken up to study the accuracy of sonomammogram in differentiating benign and malignant lesions on comparing with histopathology.

## Aim

The aim of the study was to characterize the clinically palpable breast masses into benign and malignant, based on sonomammographic findings and to assess the accuracy by comparing with histopathology, as the gold standard.

## Objectives

To determine the sensitivity, specificity, positive predictive value, negative predictive value, of sonomammography in differentiating benign from malignant breast lesion by comparing with histopathology

## Material and Methods

A descriptive study was conducted among female patients with breast lesions at the Department of Radiodiagnosis, Government Medical College, Thiruvananthapuram for one year from July 2013 to July 2014. The study sample consisted of patients referred to Department of Radiodiagnosis for ultrasonogram for evaluation of breast lesions.

All female patients above 20 years of age with palpable breast lesions and bloody discharge from the nipple were included for the study. Patients with advanced carcinoma(stage III and IV), previously treated cases, those who have not given consent for the study and with history of previous breast biopsy were excluded.

Consecutive sampling method was used for data collection using a pre-tested structured questionnaire. There were 75 patients satisfying the inclusion criteria during the study period. After obtaining the proper history, clinical examination and consent, the patients were subjected to ultrasound and compared with

histopathology which is the gold standard test. The need and aim of study were explained to the patients and informed written consent was obtained before including the subject in the study.

## Data Collection

Patients who satisfied the inclusion criteria were 75 and were subjected to undergo USS with 17mHz linear array probes and confirmed the findings with FNAC or biopsy reports. Data collection was started after obtaining the Institutional Research and Ethical Committee Clearance.

Benign criteria studied with ultrasonography are 1. Hyperechoic 2. Ellipsoid 3. <3 or few lobulations 4. Thin echogenic capsules and the malignant criteria were: 1. Anteroposterior diameter more than transverse 2. Angular margins 3. Markedly hypo echoic 4. Distal acoustic shadowing

## Data Analysis

Data was analysed using SPSS 16.0 (Statistical Package for Social Sciences, version16) and Microsoft Excel has been used to generate graph and tables. Sensitivity, specificity, positive predictive value, negative predictive value, and accuracy of sonomammogram for detection of benign and malignant breast lesions were worked out considering FNAC as the gold standard.

It is derived from 2x2 table with rows representing ultrasonography positive and negative cases as well as columns representing FNAC positive and negative cases. The features of ultrasonography was analyzed by Cohen's Kappa for statistical agreement between these and histopathology.

## Results

**Table 1.** Distribution of study population according to age and type according to FNAC

Age(in years)	Characterisation( FNAC)		Total n(%)
	Malignant n(%)	Benign n(%)	
20-29	2 (5.6%)	5(12.8%)	7 (9.3)
30-39	4(11.1%)	10(25.6%)	14 ( 18.7)
40-49	12(33.3%)	8(20.5%)	20 (26.7)
50-59	14(38.9%)	11(28.2%)	25 (33.3)
60-69	4(11.1%)	5(12.8%)	9 (12)
Total	36(100%)	39(100%)	75 (100)

The youngest patient was 23 year old and the oldest was 67 year.

**Table 2:** Distribution of patients according to clinical and FNAC diagnosis

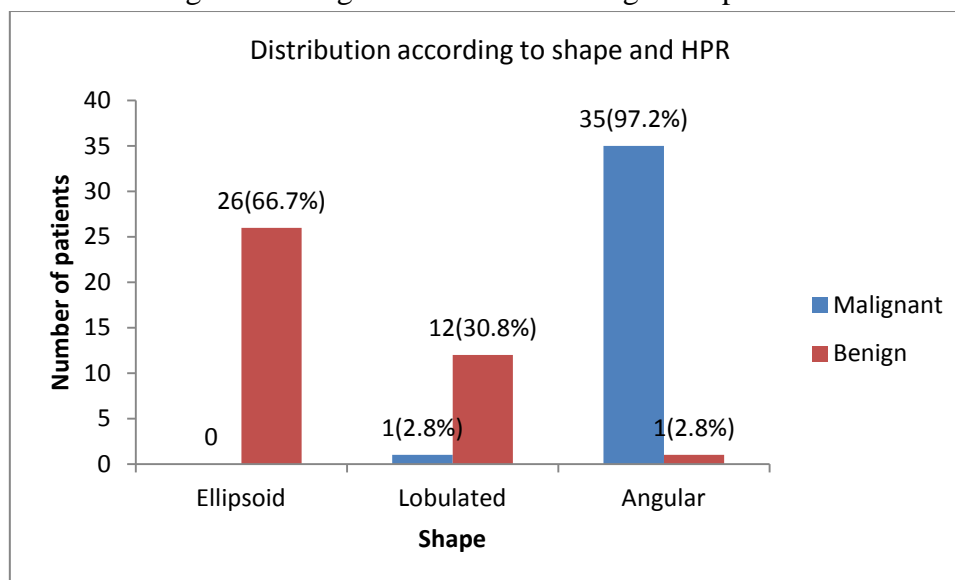
Clinical diagnosis	FNAC diagnosis		Total N(%)
	Malignant N(%)	Benign N(%)	
Benign	0(0)	27(69.2)	27(36)
Malignant	27(75)	1(2.6)	28(37.3)
Indeterminate	9(25)	11(28.2)	20(26.7)
Total	36(100)	39(100)	75(100)

P< 0.001

**Table 3 :** Distribution of benign and malignant cases according to margin

Margin	FNAC findings		Total N(%)
	Malignant n(%)	Benign n(%)	
Smooth	1(2.8)	28(71.8)	29(38.7)
Irregular	8(22.2)	10(25.6)	18(24)
Spiculated	27(75)	1(2.6)	28(37.3)
Total	39(100)	36(100)	75(100)

**Graph 1:** Distribution of benign and malignant lesions according to shape with HPR correlation



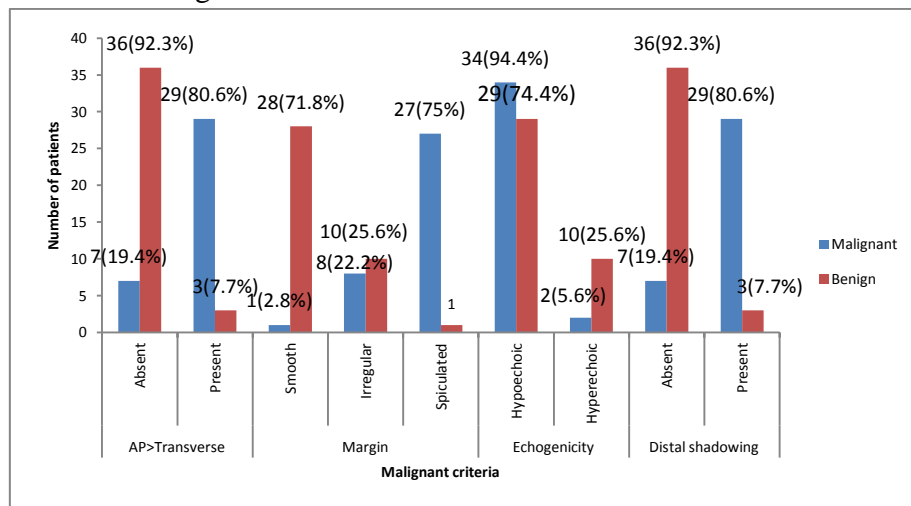
P value < 0.001

**Table 4:** Distribution of benign and malignant lesions according to thin echogenic capsule

Thin echogenic capsule	FNAC findings		Total N(%)
	Malignant n(%)	Benign n(%)	
Absent	27(75)	4(10.3)	31(41.3)
Present	9(25)	35(89.7)	44(58.7)
Total	36(100)	39(100)	75(100)

P<0.001

**Graph 2:** Distribution of benign and malignant lesions according to AP> Transverse diameter, margin, echogenicity and distal shadowing



**Table 5:** Distribution of benign and malignant lesions according to BIRADS

BIRADS	FNAC findings		Total n(%)
	Malignant n(%)	Benign n (%)	
2	0(0)	31(79.5)	31(41.3)
3	3(8.3)	3(7.7)	6(8)
4	11(30.6)	5(12.8)	16(21.3)
5	22(61.1)	0(0)	22(29.3)
Total	36(100)	39(100)	75(100)

P<0.001

**Table 6:** Distribution according to benign criteria and negative predictive value of each characteristic in ultrasonography

Criteria	FNAC findings		Total n(%)	Specificity	NPV
	Malignant n(%)	Benign n (%)			
Hyperechoic	2(5.6)	10(25.6)	12(16)	25.6	62.5
Ellipsoid	0(0)	26(66.7)	26(34.7)	66.7	74.9
Lobulated(3 or fewer lobulations)	1(2.8)	12(30.8)	13(17.3)	30.8	69.4
Thin echogenic capsule	9(25)	35(89.7)	44(58.7)	89.7	59.6

**Table 7:** Distribution according to malignant criteria and positive predictive value of each characteristic in ultrasonography

Criteria	FNAC findings		Total n(%)	Sensitivity	PPV
	Malignant n(%)	Benign n (%)			
Angular margins(spiculated)	35(97.2)	1(2.6)	36(48)	97.2	97.2
Distal shadowing	29(80.6)	3(7.7)	32(42.7)	80.6	90.6
Hypoechoic	34(94.4)	29(74.4)	63(84)	94.4	54.0
AP> Transverse	29(80.6)	3(7.7)	32(42.7)	80.6	90.6

**Table 8:** Distribution according to ultrasonographic diagnosis(2 or more ultrasonographic features) and Histopathology

Diagnosis	ultrasonographic diagnosis n(%)	Histopathology n(%)
Benign	41(54.7)	39(52)
Malignant	34(45.3)	36(48)
Total	75(100)	75(100)

Of the 34 sonologically malignant lesions, 30 were malignant histopathologically.

**Table 9:** Sensitivity, specificity, PPV and NPV of ultrasonography

USS findings	FNAC findings		Total n(%)
	Malignant n(%)	Benign(%)	
Malignant (based on the presence of atleast 2 of the malignant criteria in ultrasonography)	30(83.3)	4(10.3)	34(45.3)
Benign	6(16.7)	35(89.7)	41(54.7)
Total	36(100)	39(100)	75(100)

Measure of agreement Kappa= 0.732 P < 0.001

For detecting malignancy, with sonomammography, the sensitivity, specificity and accuracy obtained were 83.3%, 89.7% and 86.67% respectively for detection of malignancy; with PPV: 88.2% and NPV 85.3%

### Discussion

The maximum number of breast lumps was in the age group of 40- 49 years irrespective of benign or malignant nature. The most common benign lesion observed in the index study was fibroadenoma which was present in 16 patients (21 % of study population). Studies showed fibroadenoma is common before 40 years. In our study 10 out of 16 patients were below 40 years (62.5%).

The youngest patient with malignancy was 23 years old and the oldest patient was 67 years old. Above 60 years age, 4 out of 9 patients were malignant (44.5%) and rest were benign cases which consisted of oil cysts, simple cysts and breast abscesses. Here, only 44.5% in the age group above 60 years were malignant. There is higher chance of malignancy in a breast lump in patients older than 60 years. This may be due to the advanced stage of presentation which was an exclusion criterion here.

According to histopathology, 39 lesions were benign and 36 lesions were malignant. Benign lesions that came across the study were simple cysts, breast abscess, galactocele and fibrocystic breast disease. Among the 6 cases of simple cyst, 3 were in the age group of 40- 49 years and 3 in 30-39 years. According to literature, cysts are common in 30- 50 years. According to the malignant criteria for ultrasonography, 4 cases which were diagnosed as malignant by USS came out to be benign on histopathology. AP diameter

was equal to transverse diameter in one of the case. Two lesions were hypoechoic and had angular margins (satisfying malignant criteria in ultrasonography) of which two turned out to be post-operative scar and other two turned to be benign epithelial hyperplasia. According to benign criteria for ultrasonography 90% were benign. 6 cases which were diagnosed benign on ultrasonography came out to be malignant on histopathology. 2 were lobular carcinoma histologically. One was comedocarcinoma and 3 were invasive ductal carcinoma. Early malignancy may appear benign and can show well differentiated and smooth margins on ultrasonography.

Benign criteria for USS were hyperechogenicity, ellipsoid shape, fewer lobulations and thin echogenic capsule (presence of 2 or more criteria). The NPV of each were 62, 75, 70 and 60 respectively. Malignant criteria for ultrasound were angular margins, distal shadowing, marked hypo echogenicity and larger anteroposterior diameter (presence of 2 or more criteria). Positive predictive value were 97 for angular margins, 90 for distal shadowing, 54 for hypo echogenicity and 91 for larger AP diameter.

With sonomammography, the sensitivity, specificity, PPV and accuracy obtained were 83.3%, 89.7%, 88% and 86.67% respectively for detection of malignancy which is similar to that of another study showed sensitivity: 97%, specificity: 97% and positive predictive value: 85% (16).

### Conclusion

This study shows that ultrasonography is useful in characterization of breast masses. When judiciously used the requirement of biopsy for

breast masses can be reduced when strict sonographic criteria for benignity are present. The sensitivity, specificity, PPV and NPV of ultrasonography were calculated. Together these imaging modalities can be reassuring if follow up is planned when the physical examination is not highly suspicious and unnecessary breast biopsy can be avoided. The kappa values for USS was 0.732 with P value <0.001 which indicates good agreement with histopathology. The possible clinical implications of the current study is that ultrasonography can be a useful diagnostic armamentarium for the clinician.

### Limitation of the Study

Even though we have done ultrasonography, doppler evaluation of breast masses was not done which would have helped in better characterization of breast lesions into benign and malignant.

Also it is a hospital based study, the result may not be representative of the general population.

No sources of support in the form of grants

### References

1. Ghoncheh M, Momenimovahed Z, Salehiniya H. Epidemiology, incidence and mortality of breast cancer in Asia. *Asian Pac J Cancer Prev*. 2016;17:47–52.
2. Borecky N, Rickard M. Preoperative diagnosis of carcinoma within fibroadenoma on screening mammograms. *J Med Imaging Radiat Oncol*. 2008 Feb;52(1):64-7.
3. Lehman CD, Rutter CM, Eby PR, White E, Buist DS, Taplin SH. Lesion and patient characteristics associated with malignancy after a probably benign finding on community practice mammography. *AJR Am J Roentgenol*. 2008 Feb;190(2):511-5.
4. Rosenberg RD, Yankaskas BC, Abraham LA, Sickles EA, Lehman CD, Geller BM, et al. Performance benchmarks for screening mammography. *Radiology*. 2006 Oct;241(1):55-66
5. Sickles EA, Miglioretti DL, Ballard-Barbash R, Geller BM, Leung JW, Rosenberg RD, et al. Performance benchmarks for diagnostic mammography. *Radiology*. 2005 Jun;235(3):775-90.
6. Bassett LW, Gold RH, Mirra JM. Nonneoplastic breast calcifications in lipid cysts: development after excision and primary irradiation. *AJR Am J Roentgenol*. 1982 Feb;138(2):335-8.
7. Sastre-Garau X, Jouve M, Asselain B, Vincent-Salomon A, Beuzeboc P, Dorval T, et al. Infiltrating lobular carcinoma of the breast. Clinicopathologic analysis of 975 cases with reference to data on conservative therapy and metastatic patterns. *Cancer*. 1996 Jan 1;77(1):113-20.
8. Helvie MA, Paramagul C, Oberman HA, Adler DD. Invasive lobular carcinoma. Imaging features and clinical detection. *Invest Radiol*. 1993 Mar;28(3):202-7.
9. Moezzi M, Melamed J, Vamvakas E, Inghirami G, Mitnick J, Quish A, et al. Morphological and biological characteristics of mammogram-detected invasive breast cancer. *Hum Pathol*. 1996 Sep;27(9):944-8.
10. Kopans DB, Meyer JE, Murphy GF. Benign lymph nodes associated with dermatitis presenting as breast masses. *Radiology*. 1980 Oct;137(1 Pt 1):15-9.
11. Paulus DD. Benign diseases of the breast. *Radiol Clin North Am*. 1983 Mar;21(1):27-50.
12. Meyer JE, Amin E, Lindfors KK, Lipman JC, Stomper PC, Genest D. Medullary carcinoma of the breast: mammographic and US appearance. *Radiology*. 1989 Jan;170(1 Pt 1):79-82.
13. Estabrook A, Asch T, Gump F, Kister SJ, Geller P. Mammographic features of intracystic papillary lesions. *Surg Gynecol Obstet*. 1990 Feb;170(2):113-6.



14. Reuter K, D'Orsi CJ, Reale F. Intracystic carcinoma of the breast: the role of ultrasonography. *Radiology*. 1984 Oct;153(1):233-4.
15. Paulus DD, Libshitz HI. Metastasis to the breast. *Radiol Clin North Am*. 1982 Sep;20(3):561-8.
16. Yang WT, Mok CO, King W, Tang A, Metreweli C. The role of high frequency ultrasonography in the evaluation of palpable breast masses in Chinese women: alternative to mammography? *J Ultrasound in Med*, Vol. 15, Issue 9 637-644.