



Lymphoma of Breast with axillary Node Involvement- Pitfalls in Diagnosis

Authors

**Annu Elizabeth Prakash, Resmi Rajeev, Navya Narayanan Orchid,
Siyad Pokkakillath Mohamed**

Department of Pathology, Sree Narayana Institute of Medical Sciences, Ernakulam, Kerala, India

Corresponding Author

Annu Elizabeth Prakash

Assistant Professor, Pathology, Sree Narayana Institute of Medical Sciences

Residence Address- Kaliyadan House, Cheriya Pillay, Kaitharam P.O., North Paravur, Ernakulam,
Kerala 683519, India

Telephone number – 9497470661, Email: annelizprakash@gmail.com

Abstract

Lymphomas are rarely detected in breast tissue. This study reports a case of Diffuse Large B Cell Lymphoma in the breast with axillary lymph node involvement. The diagnosis was made by excision biopsy and confirmed by immunohistochemistry. Lymphomas can be a rare cause of breast lump in females of any age. Diffuse Large B cell Lymphoma is the commonest subtype among the Non Hodgkin Lymphomas affecting breast. It is difficult to differentiate a case of breast lymphoma from carcinoma by clinical examination and imaging. Tissue diagnosis is essential in evaluating breast lumps for lymphoid neoplasms so that treatment may be promptly initiated.

Keywords: *Lymphoma breast, Extra nodal Lymphoma, Diffuse Large B cell Lymphoma.*

Introduction

Lymphomas are clonal tumours of lymphoid cells at different levels of differentiation, involving lymph nodes as well as extranodal lymphoid tissue. Breast is an extremely rare site for extra nodal lymphoma, possibly due to the scarcity of lymphoid cells in normal breast tissue. The origin of primary lymphoma of breast is postulated to be Mucosa associated lymphoid tissue⁽¹⁾ (MALT). Primary Breast Lymphoma shows its major or the first manifestation in the breast tissue, with no other involvement elsewhere in the body, except for ipsilateral axillary lymph nodes⁽²⁾. Any lymphoma involving the breast, not conforming to the above criteria is regarded as Secondary Breast Lymphoma.

The objective of this study is to report a case of Breast Lymphoma with axillary nodal involvement.

Case Report

A 56 year old lady presented with a painless swelling in the upper outer quadrant of the right breast and a similar swelling in the right axilla, first noticed one month ago. The breast lump was 5 x 4 x 4 cm in size, irregular, hard with slight fixity to pectoralis muscle. The swelling in the axillary region measured 5 x 5 cm and was fixed to underlying structures. The contralateral breast was free of any palpable lesion. No other lymph nodes were palpable. Physical examination of the patient yielded no significant findings. Her blood

routine investigations were within normal limits. Mammogram showed a well-defined mass in the upper outer quadrant of right breast. Abdominal Ultrasound revealed multiple enlarged lymph nodes in the left iliac region, periportal and para aortic regions.

Fine Needle aspiration of the breast lump as well as the axillary mass predominantly showed lymphoid cells along with several tingible body macrophages (Image 1). No ductal epithelial cells were noted in the smears. Due to the atypical cytomorphology of the lymphoid cells, an excision biopsy was suggested.

The excised breast lump was a roughly nodular mass measuring 4.5 x 3.5 x 2 cm in size with a grey, fleshy cut surface (Image 2). The axillary lump appeared to be three enlarged lymph nodes, which being friable was removed as multiple fragments. Histopathology showed diffuse proliferation of small to medium sized lymphoid cells (Image 3) with some areas showing numerous tingible body macrophages. No ducts were noted within the lesion.

Immunohistochemistry showed positivity for CD20, BCL2, BCL6 and CD10. CD3, MUM1 and MYC were negative. A final diagnosis of Non Hodgkin Lymphoma, Diffuse Large B Cell type was reached from these investigations.

Based on the diagnosis, mastectomy was not considered necessary and the patient is currently undergoing chemotherapy.

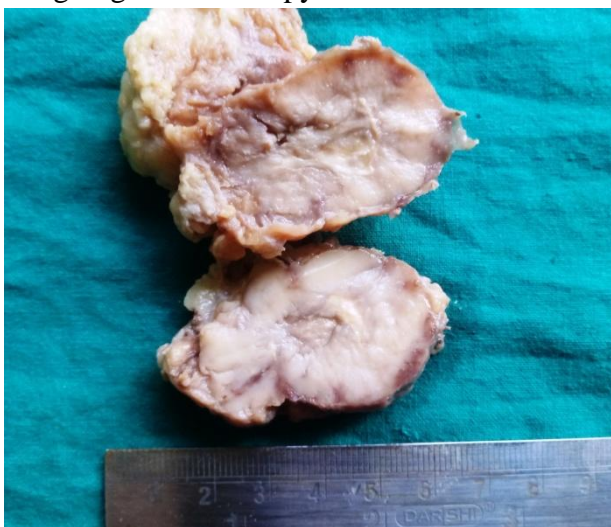

Image 1- Breast lump showing fleshy cut surface.

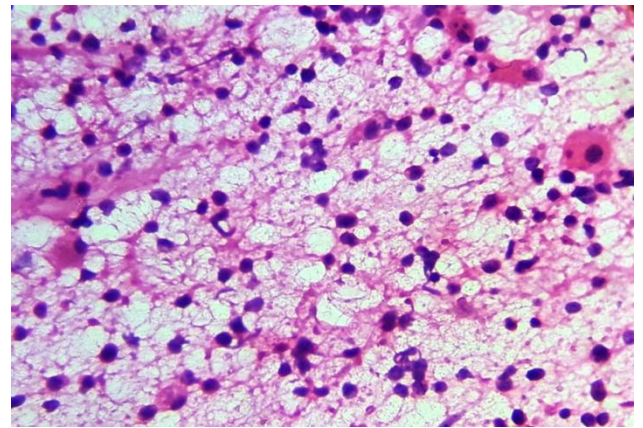


Image 2- FNAC of breast lump showing atypical lymphoid population and macrophages. Haematoxylin and Eosin.40X.

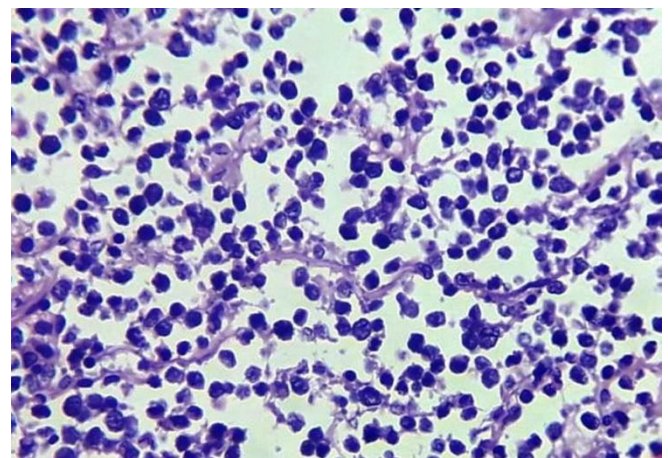


Image 3- Histopathology of breast lump showing small to medium sized lymphoid cells in diffuse pattern. Haematoxylin and Eosin.40X.

Discussion

Breast is an uncommon site of incidence for lymphoma, whether primary or secondary. Primary breast lymphoma accounts for less than 0.5% of all the malignant tumours which can occur in breast tissue⁽³⁾. Among all the cases of extranodal Non Hodgkin Lymphoma, Primary Breast Lymphoma accounts for less than 2%, whereas secondary involvement of breast by lymphomas is comparatively more common. Lymphoma of breast predominantly affects females with a wide age range of 9 to 85 years and a median age of onset of 58 years⁽⁴⁾. Primary or secondary involvement of male breast by lymphoma is exceptional. The clinical presentation of the patient may be with innocuous appearing lumps. Physical examination shows

well defined lumps with smooth rounded outlines without any fixity to pectoralis or overlying skin,⁽⁵⁾ giving credence to a clinical diagnosis of a benign lesion. Occasional cases may present with skin changes like erythema and edema but these are more likely in T cell lymphomas, which are rarer in incidence

Shim et al suggests that ultrasound is a better diagnostic tool than mammography in the detection of lymphoma of breast. The drawbacks of mammogram include its lower sensitivity in detecting very small lesions or diffuse infiltrations. Even discrete lesions appear as fairly circumscribed round to oval masses without calcifications, spiculations or architectural distortion.^(5,6) Further extensive imaging techniques need to be utilised in determining whether the breast lesion is primary or secondary in nature.

Patne et al favours FNAC as an ideal first line investigation for lymphoma of breast⁽⁷⁾. A smooth, mobile, painless breast lump maybe mistaken for a fibroadenoma or if a suspicion of malignancy arises due to axillary node involvement, for carcinoma breast, but for cytological findings. The predominance of lymphocytes on the smears may erroneously give the impression of an inflammatory lesion. The cytomorphology of the individual cells and other findings like lymphoglandular bodies have to be taken into account to reach the correct conclusion.⁽⁸⁾

Excision of the mass is essential for histopathological examination, although the advent of neoadjuvant therapy has relegated mastectomy to a minor role in the treatment strategy⁽⁹⁾. WHO classification of breast tumours classifies lymphomas of breast under Hematopoietic and lymphoid tumours, the commonest subtype being Diffuse Large B cell Lymphoma⁽¹⁰⁾. Women in the postmenopausal age group are more often affected. DLBCL of breast is distinctive from that arising in other extranodal sites in its greater likelihood to recur in the contralateral breast and at distant sites. The second most common lymphoma in the breast is Burkitt

lymphoma, which is prevalent in younger women. The diagnosis is clinched by Immunohistochemistry in all different subtypes.

Conclusion

Although rare in breast, a diagnosis of Non Hodgkin Lymphoma should be considered in case of women presenting with painless breast lumps with or without lymphadenopathy. Deceptively benign findings on clinical examination and imaging should not preclude the diagnosis of a lymphoid malignancy. The clue to diagnosis in lymphoma often lies in the atypical cytological findings. Excision biopsy and immunohistochemistry aids in confirming and refining the diagnosis. Further management involves chemotherapy and mastectomy is not considered to be necessary.

Acknowledgements: Nil

Sources of Support: Nil

References

1. Jennings WC, Baker RS, Murray SS, Howard CA, Parker DE, Peabody LF, et al. Primary breast lymphoma: The role of mastectomy and the importance of lymph node status. *Ann Surg.* 2007;245(5):784–9.
2. Wiseman C, Liao KT. Primary lymphoma of the breast. *Cancer.* 1972;29:1705–1712.
3. Joks M, Myśliwiec K, Lewandowski K. Primary breast lymphoma - a review of the literature and report of three cases. *Arch Med Sci.* 2011;7(1):27–33.
4. Whitfill CH, Feig SA, Webner D. Breast imaging case of the day. Secondary non-Hodgkin (low-grade B-cell follicular small cleaved cell type) lymphoma of the breast. *Radiographics.* 1998;18:1038–42.
5. Yang H. Primary Breast Lymphoma (PBL): A Literature Review. *Clin Oncol Cancer Res* 2011(8);128–32.
6. Shim E, Song SE, Seo BK, Kim YS, Son GS. Lymphoma affecting the breast: A pictorial review of multimodal imaging

- findings. J Breast Cancer. 2013;16(3):254–65.
7. Patne SCU, Kumar M, Khanna R. Cytodiagnosis of Primary Breast Lymphoma in a Young Woman. J Cytol. 2013 Oct-Dec; 30(4): 284–286.
 8. Jain MF, Khandekar SL, Mahadani JW, RautWK. Report of a case of primary breast lymphoma highlighting the importance of fine needle aspiration cytology as an initial diagnostic tool. J Cytol. 2015 Apr-Jun; 32(2): 127–129
 9. Vannata B, Zucca E. Primary extranodal B-cell lymphoma: current concepts and treatment strategies. Chin Clin Oncol 2015;4(1):10.
 10. Gupta V, Bhutani N, Singh S, Chhabra S, Sen R. Human Pathology : Case Reports Primary non-Hodgkins lymphoma of breast – A rare cause of breast lump. Hum Pathol Case Reports. 2017;7:47–50.