



Comparison of Grayscale and Histogram Thorax Computed Radiography (CR) Image in Tuberculosis (TBC) Patients with Normal Thorax Image

Authors

Kadek Yuda Astina¹, Bagus Dharmawan², I Made Wijaya³, Putu Rita Jeniyanthi⁴, Wahyu Gitawiarsa⁵

^{1,2,3,4}Lectures, Academy of Engineering Radiodiagnostic and Radiotherapy Bali, Indonesia

Email: atro_bali@yahoo.com

⁵Radiographer, Department of Radiology, Prima Medika Hospital, Bali Indonesia

Email: wahyupande10@gmail.com

*Corresponding Author

Kadek Yuda Astina

Email: yuda_astina@yahoo.com

Abstract

Introduction: According to WHO the world's leading cause of death was tuberculosis. Diagnosis of tuberculosis can be done by examining the chest X-ray to see the organs in the chest. This study aims to determine whether there is a difference in grayscale values and histogram on thorax computed radiography images of tuberculosis (TBC) patients.

Method: This research was quasi experimental with post-test only control group design method. The sample in this study were 30 patients who had chest X-ray examination. The Sample were divided into 2 groups, namely the control group (15 patients with normal thorax images) and the intervention group (15 patients with tuberculosis thorax images). Grayscale and histogram analysis were performed on Region of Interest (ROI) in the apex region of lung and superior lobe of the lung containing gloomy spots on the thorax image, assisted with a 16-bit MATLAB program, and later statistically analysed using SPSS 2.3 program.

Results: Non-paired T-test results concludes that there is a statistical difference of grayscale value between TB thorax image and normal thorax image, since the non-paired T-test reveals p value of less than $<0,001$ ($p < 0,05$).

Conclusion: The grayscale data was then converted to histograms, which showed that the tubular thorax image histograms were leaning to the right (high grayscale value) and the normal thorax image histograms tend to skew to left side (low grayscale value). The mean value of grayscale of tuberculosis patients thorax images using 16 bit is 36896,89 while the mean value of normal thorax levels at 15036,51.

Keyword: Tuberculosis, computed radiography, thorax image, Histogram, grayscale.

Introduction

Tuberculosis (TB) has been declared by the World Health Organization (WHO) as a "Global Emergency" in 1992. Indonesia was the highest number of TB sufferers, which is ranked 3rd in the world for ten years and only in 2011 fell to rank

^{5[1][2]}. According to WHO the world's leading cause of death was tuberculosis. In 2014 there were 9.6 million TB cases, including 5.4 million in men, 1.5 million in women, and 1 million in children. The number of TB deaths is very high from 9.6 million cases, 1.5 million have died and the rest can be cured with proper diagnosis and treatment^{[3][4]}. The

prevalence of pulmonary tuberculosis in Indonesia is in sixth position in Southeast Asia with a figure of 281 per 100,000 population. Province of Bali in 2013 with a prevalence of pulmonary tuberculosis reaching 50 per 100,000 population^[5].

Diagnosis of tuberculosis can be done by examining the thorax X-ray to see the organs in the chest. The thorax X-ray can show abnormalities through nodular shadows in the apical and posterior segments of the upper lobe of the lung and the superior segment of the lower lobe. Many shadows are white around the lung apex^{[6][7]}. This examination uses Posterior Anterior (PA) or Posterior Anterior (AP) projections according to the patient's condition and diagnostic needs^{[8][9]}.

In the era of computer technology, radiological examination techniques have used Computed Radiography (CR). The process of digitizing images using an imaging plate for the acquisition of X-Ray image data was carried out by Computed Radiography^{[9][10]}. Digital imaging technology has changed implementation in radiology and most have replaced conventional films^[11]. The digital image can display the histogram to find out the contrast value^[10]. The digital image produced by CR can be calculated the grayscale value and the histogram using the MATLAB program^{[12][13][14]}. This study was conducted to determine the differences in grayscale values and histogram on Thorax CR images for patients with pulmonary tuberculosis and normal Thorax images in Radiology Installation at Sanglah General Hospital. Information on grayscale values and histograms can later be used as additional instructions for medical personnel to enforce patient diagnoses so that diagnoses are more accurate.

Aims and Objectives

- To analyse the differences in grayscale values on thorax computed radiography (CR) images of pulmonary tuberculosis (TB) patients with normal chest radiographs.
- To analyse differences in histograms on thorax computed radiography (CR) images of

pulmonary tuberculosis (TBC) patients with normal chest radiographs.

- To determine the average grayscale value and histogram on the image of the thorax computed radiography (CR) patients with tuberculosis (TB) normal lung and thorax image.

Methods

This research was quasi experimental with post-test only control group design method^[15]. Thorax X-ray was taken randomly using exposure factors at a voltage of 55 kV - 60 kV, amperes of 4 mAs - 6 mAs with a thickness of 10 cm - 15 cm. The exposed chest image will be processed using Computed Radiography. The sample in this study were 30 patients who had chest X-ray examination. The Sample were divided into 2 groups, namely the control group (15 patients with normal thorax images) and the intervention group (15 patients with tuberculosis thorax images). The chest image used as sample was 15 thorax TB images and 15 normal thorax images recommended by the radiologist.

The chest image that will be analyzed is displayed in the MATLAB version 7.12^[16] program with a 16 bit format (Figure 1). Grayscale and histogram analysis were performed on Region of Interest (ROI) in the apex region of lung and superior lobe of the lung containing gloomy spots on the thorax image (Figure 2). The chest image that has been measured by ROI will be cropped (Figure 3) and a grayscale value will be calculated along with a histogram (Figure 4), later statistically analysed using SPSS 2.3 program.

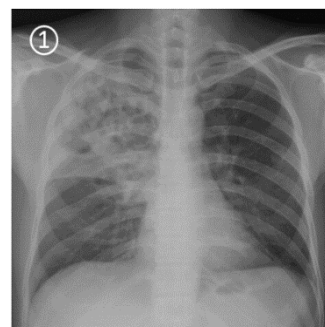


Fig. 1 Display of Thorax Image in Matlab

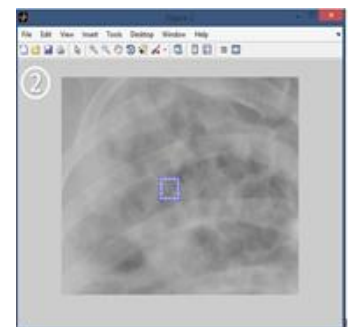


Fig. 2 ROI in the Apex Region

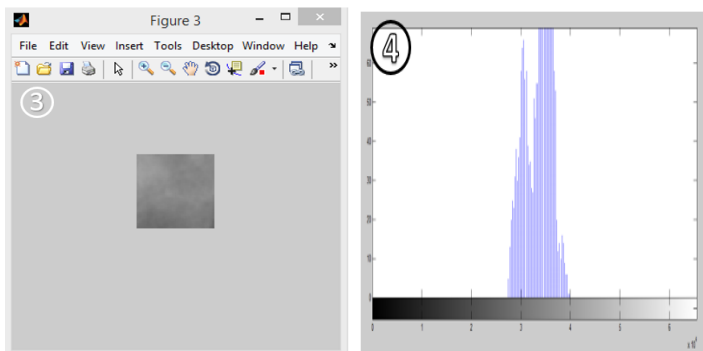


Fig. 3 Display of Thorax Image after Cropping

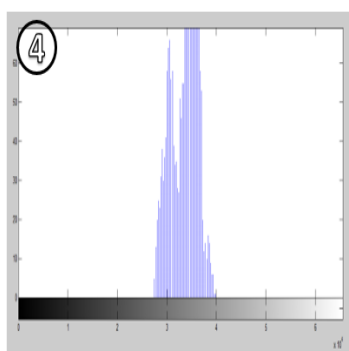


Fig. 4 Histogram Thorax Image

Result

Characteristics of respondent's data are described based on gender and age, in the intervention groups (tuberculosis sufferers) and control group (normal patients) (Table No 1).

Table No 1 Characteristics of Sample

Thorax Image	Male	Female	Age (Mean ±SD)	Thorax Thickness
	Percentage			
TB	13 (86, 7%)	2 (13, 3%)	52,40±5,41	13,67±0,9
Normal	13 (86, 7%)	2 (13, 3%)	54,33±5,41	12,60±1,35

Comparison of thorax TB images and normal chest images can be seen in Figure 5 and Figure 6.

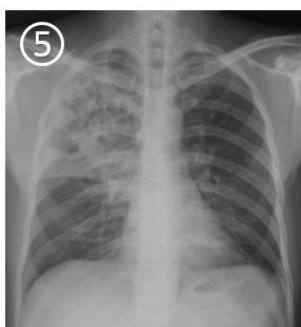


Fig. 5 Thorax image of TB

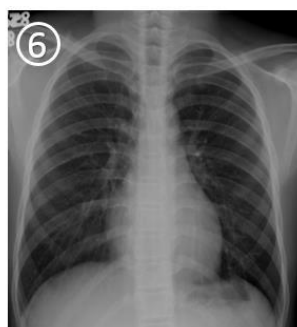


Fig. 6 Normal Thorax Image

Each thorax image is measured by ROI and the image is analyzed in grayscale and its histogram uses MATLAB version 7.12 with 16 bit format. The results of measuring grayscale using ROI can be shown in table 2. The grayscale value of the chest TB image has an average of 36896.89 and the grayscale value of the normal chest image has an average of 15036.51.

Table No 2 Results of Measurement Grayscale from TB Thorax Image and Normal Thorax Image

Grayscale	
TB Thorax Image	Normal Thorax Image
39256,80	15041,79
39917,69	15862,93
36586,13	14695,60
35032,52	14829,67
36264,09	14917,80
39734,82	18662,49
39932,23	14486,17
39915,70	15623,41
34821,15	13965,67
34162,86	16227,72
37152,40	12357,70
34026,13	13589,51
35380,80	14709,54
34744,70	14706,15
36465,38	15871,44
Average (36892,89)	Average (15036,51)

After grayscale measurements using ROI, it was continued by making a thorax image histogram using MATLAB. The histogram of the TB thorax image shows a graph that tends to be wide and approaches the right direction in white (Figure 7). Normal thorax image histogram shows a graph that tends to be narrow and close to the left in black (Figure 8).

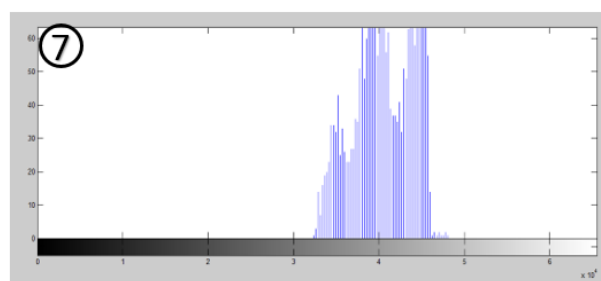


Fig. 7 Histogram of TB Thorax Image

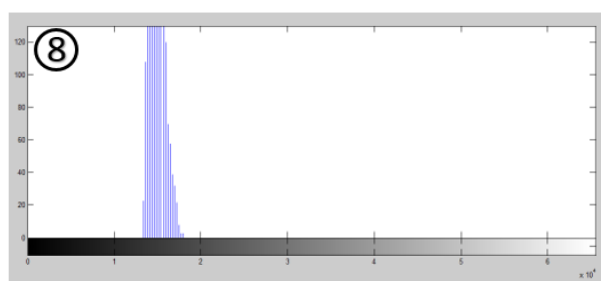


Fig. 8 Histogram of Normal Thorax Image

The results of Non-paired T-test that the value of p value is <0.001 (p value <0.05) shown in table 3. The results of this statistical test mean that there is a

significant grayscale difference between the image of the pulmonary thorax (TB) and the normal thorax image.

Table No 3 the Results of Non-Paired T-Test

Variable	p Value
TB Thorax Image-Normal	<0,001
Thorax Image	(p < 0,05)

Discussion

Tuberculosis is a disease caused by mycobacterium tuberculosis. These germs usually enter the human body through the respiratory tract into the lungs. The entry of mycobacterium tuberculosis in the lungs can cause infection in the lungs. These germs are usually located in the lung apex where the place contains a lot of oxygen and is very moist to multiply for mycobacterium tuberculosis germs^[6].

The grayscale value of the chest TB image has an average of 36896.89 and the grayscale value of the normal chest image has an average of 15036.51. The results of Non-paired T-test that the value of p value is <0.001 (p value <0.05) that mean that there is a significant grayscale difference between the image of the pulmonary thorax (TB) and the normal thorax image. The difference between the chest image of tuberculosis and the normal thorax image by lesions in the lung part of the TB patient while in the normal lung there are no lesions containing only air^[17].

The histogram of the Thorax TB image shows a graph that tends to be wide and approaches the right direction in white. Normal histogram images show graphs that tend to be narrow and close to the left black. This means that the grayscale pixel value of the thorax image of TB patients is of higher value than the normal thorax image. Histogram shift between chest X-ray image and normal thoracic image due to lesions in the lungs. Lesions in the form of pneumonia nests will look like clouds or smooth round shape on a radiograph. The presence of mycobacterium tuberculosis bacteria that have shaped lesions has a higher tissue density than normal lung tissue. Therefore, when a chest x-ray is performed on TB patients, it will produce images that tend to be whiter (radiopaque) and grayscale values show higher values than normal thorax. TB

lesions affected by X-rays will produce images that tend to be whiter (radiopaque) in the graph histogram will shift towards the right.

Conclusions

- There was a significant grayscale difference between the image of the pulmonary thorax (TB) and the normal thorax image, based on the results of Non-paired T-test that the value of p value is <0.001 (p value <0.05)
- There are differences in histograms on Thorax Computed Radiography (CR) images of pulmonary tuberculosis (TBC) patients with normal chest radiographs. The histogram of the Thorax TB image shows a graph that tends to be wide and approaches the right direction in white. Normal histogram images show graphs that tend to be narrow and close to the black left.
- The mean grayscale image of the TB thorax image and normal chest image differ significantly. The grayscale value of the chest TB image has an average of 36896,89 and the grayscale value in the normal chest image has an average of 15036,51.

References

1. Bloom B., 2006. *Tuberculosis Pathogenesis Protection and Control*. Howard H, editor. Washington DC: Albert Einstein Collage ASM.
2. Anderson, S.P., 2016, *Patofisiologi Konsep Klinis Proses – Proses Penyakit*, ahli Bahasa: Anugerah Peter, Edisi 4, Penerbit Bu ku Kedokteran EGC, Jakarta
3. World Health Organization (WHO), 2015. *Global Tuberculosis Report*. Edition 20.
4. Enarson D.A., Chen Y.C., Murray J.F., 2004. *Global Epidemiology Of Tuberculosis*. In: Rom WN, Garay SM, Blomm BR, editors. *Tuberculosis*. Philadelphia: Lippincott William & wilkins.
5. Badan Kesehatan RI. 2013. *Riset Kesehatan Dasar (RISKESDAS)*.

6. Bahar, Asril& Amin, Zulkifli. 2007. Tuberkulosis Paru. Dalam : Sudoyo, Aru et al. *Buku Ajaran Ilmu Penyakit Dalam Jilid II Edisi I V*. Jakarta : Pusat Penerbit Ilmu Penyakit Dalam FKUI, pp:988
7. Moore & Agur. 2002. *Essential Clinical Anatomy*. Penerbit Lippincott Williams & Wilkins.
8. Bontrager, Keneth L. 2014. *Text Book of Radiographic Positioning and Related Anatomy*. Eight Edition
9. Ballinger, Philip W. dan Eugene D. Frank. 2003. *Merrill's Atlas of Radiographic Positions and Radiologic Prosedures, Tenth Edition, Volume Three*. Saint Louis : Mosby.
10. Luis L., Augusto S., 2013. *Digital Imaging System for Plain Radiography*. New York: Business Media Springer Science
11. Greene, E. Reginald danJorg Wilhelm Oestmann. 2016. *Computed Digital Radiography in Clinical Practice*. New York :Thieme Medical Publishers.???
12. Bourne R. *Fundamentals of Digital Imaging in Medicine*. In: Calamar SL. Eds. 10th ed.2010. London: Springer
13. Gonzalez R.C., Woods R.E., 2008. *Digital Image Processing*. Prentice Hall. New Jersey
14. Greene, E. Reginald danJorg Wilhelm Oestmann. 2016. *Computed Digital Radiography in Clinical Practice*. New York: Thieme Medical Publishers
15. Sugiyono. 2010. *Metode Penelitian Kuantitatif, Kualitatifdan R & D*. Bandung: CV Alfabeta
16. Mathworks, (10 February 2016). *All about Matlab*. <http://www.mathworks.com>
17. American Thoracic Society. 2000. *Diagnostic Standards And Classification Of Tuberculosis In Adults And Children*. American Journal Of Respiratory And Critical Care Medicine: Vol 161.