



Histopathological Spectrum of Lesions in Orchidectomy Specimens – A Clinicopathological Study in Tertiary Care Hospital

Authors

Syed Imtiyaz Hussain¹, Gulshan Akhter², Ruby Reshi³, Suhail Farooq¹, Farooq Sideeq¹

¹Senior Resident, Postgraduate Department of Pathology, GMC Srinagar

²Senior Resident, Postgraduate Department of Obstetrics and Gynae, GMC Srinagar

³Head of Department, Postgraduate Department of Pathology, GMC Srinagar

*Corresponding Author

Syed Imtiyaz Hussain

Senior Resident Postgraduate Department of Pathology, GMC Srinagar.190010, India

Abstract

Background: Testicular Lesions are common in males of all age groups. The lesions range from Benign to malignant. The treatment is different for different histologic subtypes.

Objective: The aim of this study is to study the spectrum of testicular lesions in orchidectomy specimens and their clinical presentation.

Materials and Methods: This is a three and a half year retrospective study on hundred Orchidectomy cases from January 2015 to June 2018 conducted in the Post graduate department of Pathology Govt. Medical College Srinagar. Histopathological examination was done after routine processing and staining with Haematoxylin and Eosin.

Results: Non-neoplastic lesions of the testis are most common in the second decade of the life while malignancy is common in 3rd decade of life. The youngest patient was at one year and oldest was 76 years of age. Unilateral involvement is more common than the bilateral involvement; particularly right sided involvement is common than the left side involvement. Non-neoplastic lesions were (70%) were more common than the neoplastic lesions (30%) of testis. Out of non-neoplastic lesions, cryptorchid testis was most common findings (42.8%) followed by torsion and infarction (22.8%). Among the neoplastic lesions malignant lesions (56.6%) are more common than the benign lesions (43.3%). Out of all neoplastic lesions, mature teratoma is the most common finding (43.3%) in the present study.

Conclusion: Histopathology diagnosis is the golden standard tool despite various newer techniques as management is different for different lesions.

Keywords: Testicular Lesions, Orchidectomy.

Introduction

The testicular tumors (TTs), although relatively rare, constitute the 4th most common cause of death from neoplasia in a younger male. It is usually found in age groups of men between 15 and 35 years which accounts for <1% of all malignancies in males¹. Risk of development of these tumours increases with cryptorchidism and familial history of testicular tumours². The vast

majority of testicular tumours are of Germ cell origin and like the totipotent germ cells from which they arise, may differentiate along several pathways. The distinction of seminoma from the non seminomatous germ cell tumours remains of prime clinical importance.³

The germ cell tumours are the more common (approximately 95% of all testicular tumours) and are further divided into seminomas (40-45%), non

seminomatous tumours (approximately 30-35%) and mixed germ cell tumours (approximately 10%)⁴. Among the non-seminomatous tumours are Embryonal carcinomas (approximately 25%), Yolk sac tumours (approximately 15%), Malignant Teratoma (approximately 22.5%) and mixed tumours (approximately 37.5%)⁵. Other rare tumours are lymphomas (approximately 4% of all testicular tumours) which are the most common tumours in elderly age group⁶. The diagnosis of testicular lesions is mainly confirmed by histopathological examination. It is important to categorize these lesions as treatment and followup is different in each category.

Aims & Objectives

1. To study the various histopathological patterns of testicular lesions.
2. To study the age, laterity and clinical presentation of testicular lesions.

Materials and Methods

This is a one year retrospective study, done in the Postgraduate Department of Pathology in Govt. Medical College, Srinagar on hundred orchidectomy specimens. Detailed clinical data was retrieved from Record section of our department. The lesions were classified as non-neoplastic and neoplastic lesions. Neoplastic were further divided into benign and malignant.

The present study was carried out from January - 2015 to June-2018. A total of 100 cases were studied. Thorough Gross examination was carried out and salient features were noted down. The Gross specimens received were fixed in 10% neutral buffered formalin for overnight fixation. Next day morning, Gross examination of fixed specimen is done and the sections were taken from representative sites. These sections are further processed into automated tissue processor. After processing, sections are embedded in paraffin to make paraffin blocks. These blocks are then cut serially in three to five micron thickness using rotatory microtome to prepare slides. Slides are then stained using routine. Haematoxylin and

Eosin stain and then mounted with DPX. Immunohistochemical marker was done only in Non Hodgkin lymphoma cases.

Inclusion criteria: All orchidectomy specimens sent to post graduate department of pathology from surgery department and other associated hospitals of GMC Srinagar.

Exclusion criteria: All Testicular biopsies

Results and Observation

This is a Retrospective study conducted at Post graduate Department of Pathology, Govt. Medical College, Srinagar. A total of 100 Orchidectomy cases were studied during three and half year study from January 2015 to June 2018.

Out of 100 Orchidectomy cases, 70 cases were non neoplastic and 30 were neoplastic. Among neoplastic, 13 cases (43.3%) were benign and 17 cases (56.5%) were malignant.

Table 1: Histopathological diagnosis of non-neoplastic lesions

Histopathological Diagnosis	Number of cases (n=70)	Percentage
Cryptorchid Testis	30	42.8%
Granulomatous Orchitis	04	5.7%
TuberculoEpididymo-Orchitis	03	4.2%
Non Specific Testicular Abscess	11	15.7%
Non Specific Epididymo-Orchitis	06	8.5%
Torsion and Infarction	16	22.8%

Among non neoplastic lesions of testis, Cryptorchid testis constitutes the major bulk with 30 cases (42.8%) followed by torsion and infarction of testis with 16 cases (22.8%).

Table 2: Histopathological diagnosis of Neoplastic lesions

Histopathological Diagnosis	Number of Cases (n=30)	Percentage
Mature Teratoma	13	43.3%
Seminoma	08	26.6%
Yolk Sac Tumour	02	6.6%
Immature Teratoma	02	6.6%
Mixed Teratoma With Seminoma	02	6.6%
Non Hodgkin Lymphoma	03	10%

Neoplastic cases were further divided into benign and malignant with mature teratoma in benign category which included 13 cases (43.3%) and among malignant major bulk is seminoma with 08 cases (26.6%).

Table 3: Age incidence of testicular lesions

AGE (years)	Non-neoplastic lesions		Neoplastic lesions			
			No. of Cases		Total No. of Cases(n=30)	%age
	No. of cases (n=70)	%age	Benign	Malignant		
0-10	6	8.5	2	0	2	6.6
11-20	11	15.7	5	2	7	23.3
21-30	12	17.1	6	3	9	30.0
31-40	11	15.7	0	5	5	16.6
41-50	6	8.5	0	2	2	6.6
51-60	7	10	0	2	2	6.6
61-70	8	11.4	0	1	1	3.3
>70	9	12.8	0	2	2	6.6

Table 4: Clinical presentation of testicular lesions

Clinical Presentation	Number of Cases (n= 100)	Percentage
Testicular swelling	83	83
Lower abdominal pain	10	10
Testicular pain	07	07

The main clinical presentation of testicular lesions in our study is testicular swelling with 83 cases.

Table 5: Laterality of testicular lesions

Laterality	Side	Non-neoplastic lesions		Neoplastic lesions	
		No. of cases	%age	No. of cases	%age
Unilateral	Right	45	64.2	18	60.0
	Left	20	28.5	12	40.0
Bilateral		5	7.1	0	0

Among laterality, Right sided is more common with 63 cases and 32 cases with left side involvement and 05 cases have bilateral involvement.

Among non-neoplastic cases, 45 cases (64.2%) have right side involvement and 20 cases (28.5%) have left side involvement while as 05 cases(7.1%) have both testis involved.

Among neoplastic cases, 18 cases (60%) have right side involvement and 12 cases (40%) have left side involvement while none have bilateral involvement.

PHOTO MICROGRAPHS

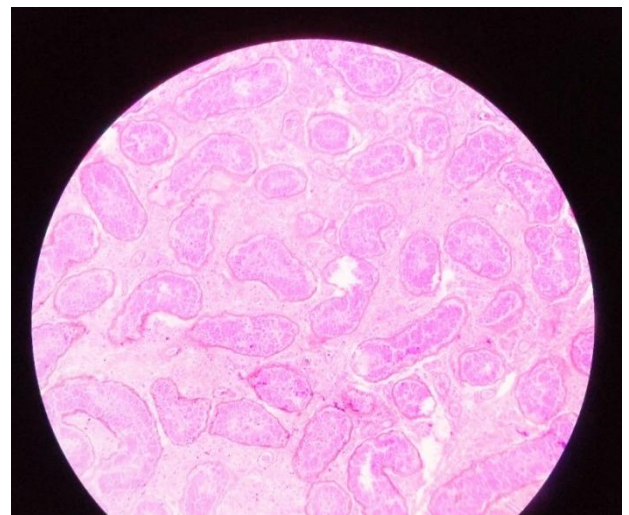


PHOTO MICROGRAPH OF TORSION TESTIS (10 X).

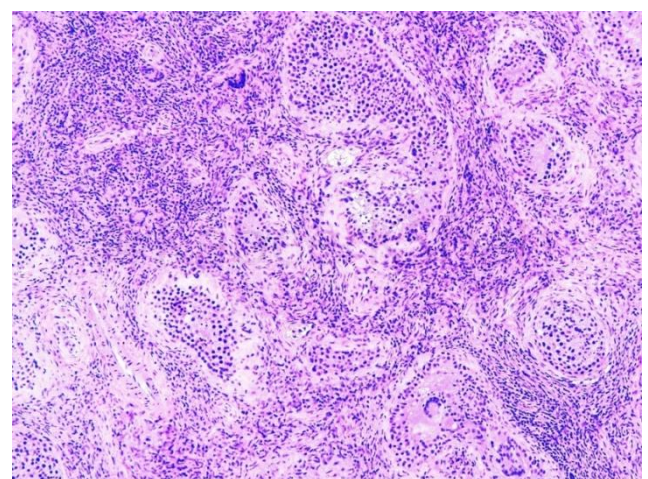


PHOTO MICROGRAPH OF GRANULOMATOUS ORCHITIS (10X).

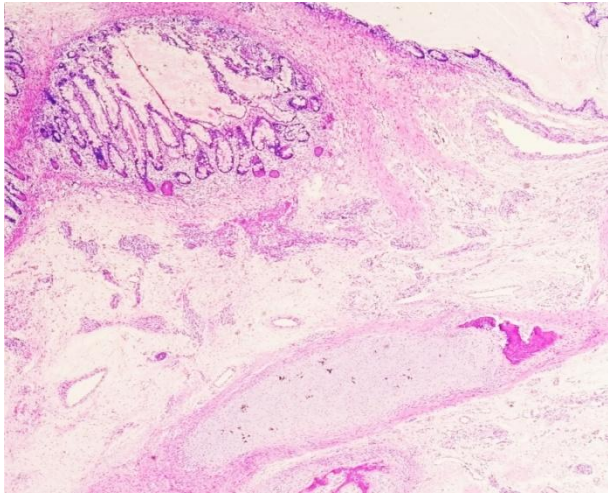


PHOTO MICROGRAPH OF MATURE TERATOMA TESTIS (10X).

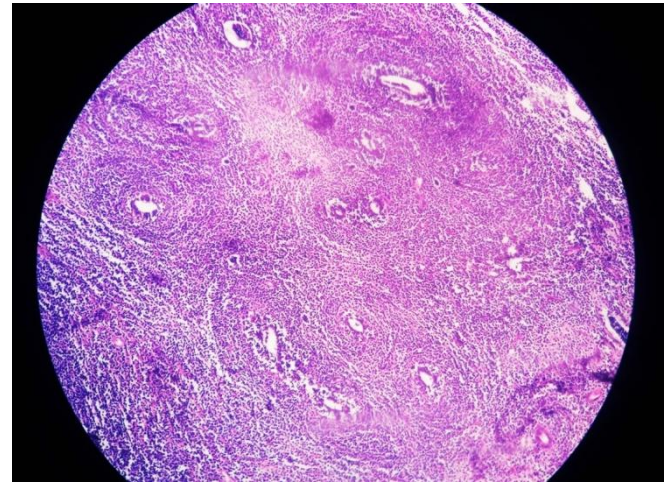


PHOTO MICROGRAPH OF NON HODGKIN LYMPHOMA TESTIS(4X)

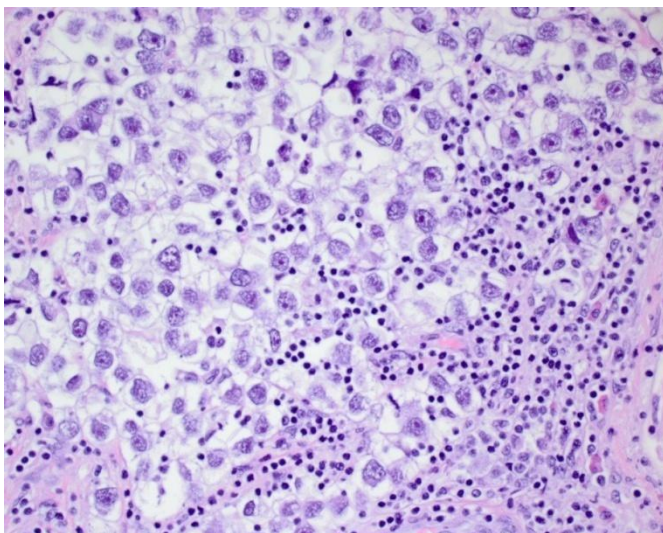


PHOTO MICROGRAPH OF SEMINOMA TESTIS (40X).

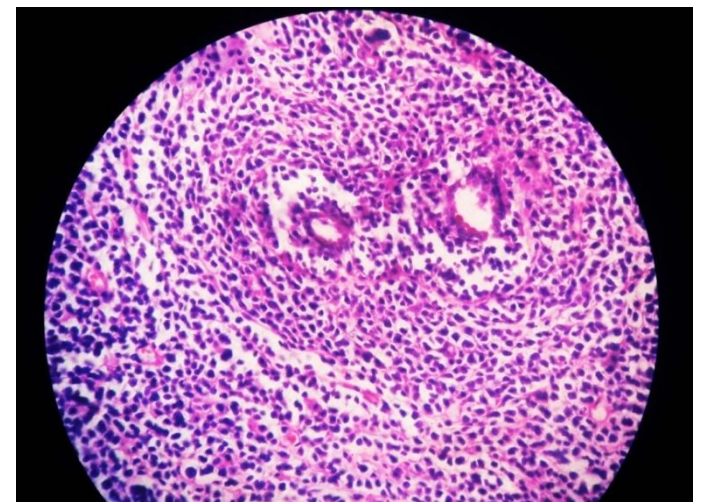


PHOTO MICROGRAPH OF NON HODGKIN LYMPHOMA TESTIS (40X)

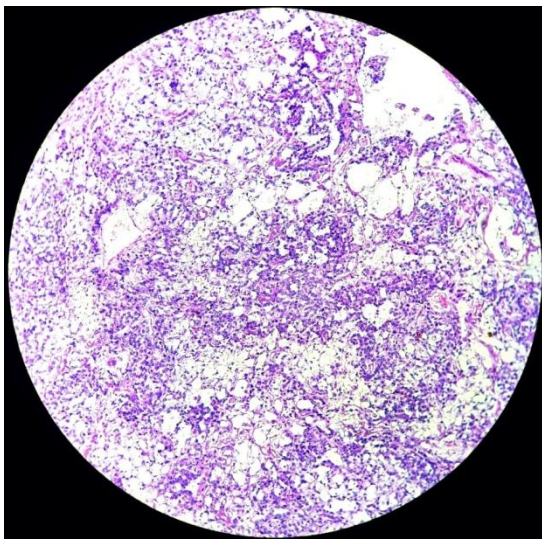
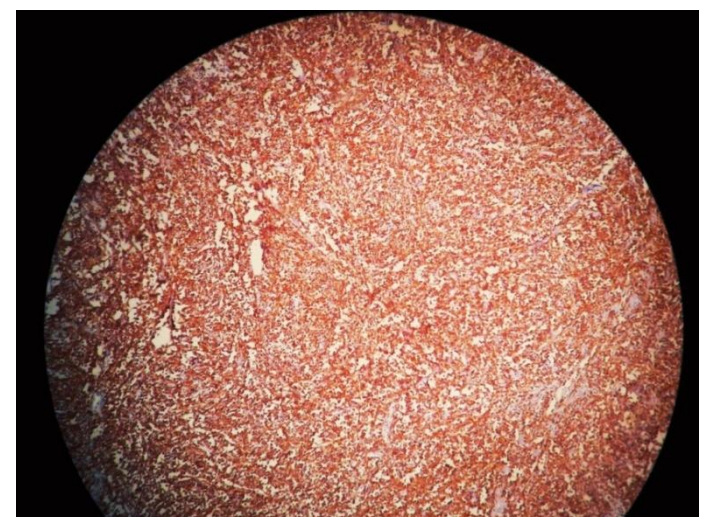
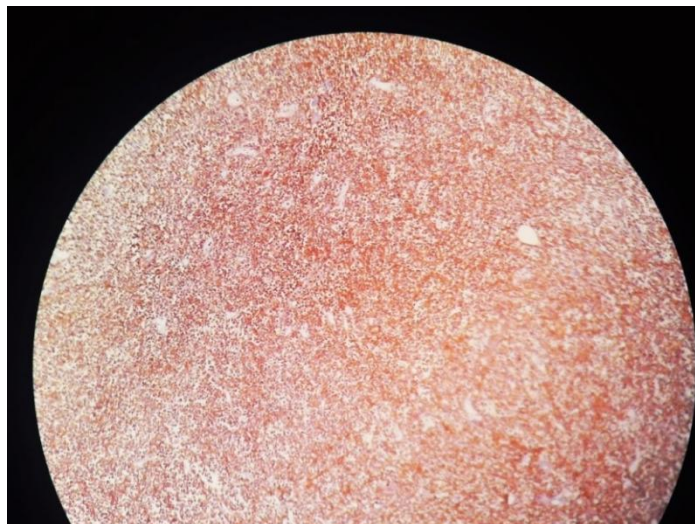


PHOTO MICROGRAPH OF YOLK SAC TUMOUR OF TESTIS (10X).



IMMUNO HISTOCHEMICAL MARKER CD 20 POSITIVITY



**IMMUNOHISTOCHEMICAL MARKER
CD45 POSITIVITY**

Discussion

In the present study out of 100 Orchidectomy cases, 70 cases (70%) were non-neoplastic and 30 cases (30%) were neoplastic. Out of 30 cases, 13 cases (43.3%) were benign and 17 cases (56.6%) were malignant.

Table 6: Comparison of percentage incidence of benign and malignant lesions

Authors(year)	Benign	Malignant
Haas GP et al (1986) ⁷	31%	69%
Kressel K et al (1988) ⁸	13.6%	87.4%
Robertson GS (1995) ⁹	31.5%	68.4%
Present study(2018)	43.3%	56.6%

In clinical Presentation, Testicular swelling constitute 83% in the present study; the same results are obtained by Robson et al¹⁰ and W. Duncan et al.¹¹

Table 7: Side of involvement of Testicular Lesions

Authors(Years)	Right	Left
W.Duncan (1987) ¹¹	55.8%	44.2%
Reddy and Ranganayakamma (1966) ¹²	64.3%	35.7%
Moghe K.V. et al (1970) ¹³	54.2%	45.8%
Present study(2018)	63%	32%

The etiology of this laterality may have to do with the fact that the right sided testis lies higher in the scrotal sac than the left and is therefore lesser amenable to temperature regulation by the dartos muscle.^{14,15}

Among non-neoplastic cases, cryptorchid testis constitute the major bulk, 30 cases (42.8%) followed by torsion and infarction 16 cases (22.8%).

Cryptorchidism is the only congenital anomaly of testis observed in our study and all 13 cases received were unilateral. Grossly, 70% were normal, 30% were small and brown. Histopathologically 02 cases showed normal histology, 04 cases showed maturation arrest at different levels and 07 cases showed features of atrophic testis. Cryptorchidism is the main risk factor for testicular cancer, which is currently the most frequent cancer in young men.¹⁶ Several authors now believe that any form of cryptorchidism at birth, regardless of the outcome should be considered a risk factor for testicular cancer¹⁷.

We had 03 cases of tubercular epididymo-orchitis. Genital TB accounts for 18% of cases of tuberculosis in India.¹⁸ Genitor urinary TB is the second most common form of extra pulmonary TB after lymphnode involvement.¹⁹

Most of the malignant cases were seen in the second and third with 08 cases (47%). Testicular tumors are limited to three age groups: infancy, late adolescence to young adulthood (20-35 years), and 50 years and above.

Of the total 17 neoplastic tumors in this study, 82.35% (14 cases) consisted of Germ cell tumours (GCTs). According to Mostofi and Price.²⁰ Germ cell tumours constitute more than 94% of Testicular tumours. Among the 14 cases of GCTs in this study, 2 (6.6%) were mixed GCTs. In this study, seminoma consisted of 26.6% (08 cases) of all Testicular tumours. In this study 03 cases (10%) of Non-Hodgkin lymphoma were seen which were later confirmed by immunohistochemistry. Primary testicular lymphoma accounts for approximately 4% of all lymphomas and is the most common testicular malignancy in men more than 60 years of age.²¹ Testicular swelling is the main complaint, 80% in our study, this was exactly the same in a study conducted by Duncan and Munro¹¹.

Conclusion

Testicular lesions exhibit broad histopathological spectrum. Non neoplastic lesions are more common than neoplastic lesions. Among non-neoplastic lesions, cryptorchid testis is more common and Mature Teratoma among benign category and seminoma among malignant category were more common. Testicular swelling is the main clinical presentation in patients with testicular lesions with right sided involvement more common probably because right sided testis lies higher in the scrotal sac than the left and thus less amenable to temperature regulation.

Histopathological diagnosis of testicular lesions is the golden standard tool as clinically neoplastic lesions can mimic non-neoplastic and vice versa and treatment and follow up is different in each category.

Acknowledgement

Authors acknowledge the immense help received from the scholars whose articles are cited and included in references of this manuscript. The authors are also grateful to authors / editors / publishers of all those articles, journals and books from where the literature for this article has been reviewed and discussed.

Bibliography

- Goedegebuure PS, Liyanage U, Eberlein TJ. Tumor biology and tumor markers. In: Townsend CM, Beauchamp RD, Evers BM, Mattox KL, editors. Townsend: Sabiston Textbook of Surgery. 17th ed. Philadelphia, PA: Elsevier, Saunders; 2004.
- Bray F, Richiardi L, Ekbom A, Pukkala E, Cuninkova M, Moller H. Trends in testicular cancer incidence and mortality in 22 European countries: continuing increase in incidence and decline in mortality. *Int J Cancer* 2006; 118:3099-111.
- Mulbright T, Barney DM. Testicular and paratesticular tumours. *Sternbergs Diagnostic Surgical Pathology* 2015; Vol. 2: 2175.
- Richiardi L, Bellocco R, Adami HO, Torrang A, Barlau L, Hakulinen T, et al. Testicular cancer incidence in eight European countries: secular and recent trends. *Cancer Epidemiol Biomarkers Prev* 2004;13:2157-66.
- Barney DM. Staging and classification of testicular tumours: pitfalls from macroscopy to diagnosis. *J ClinPathol* 2008;61:20-24.
- Park DS, Chung MK, Chung JI, Ahn HJ, Lee ES, Choi HY, et al. Histologic type, staging, and distribution of germ cell tumors in Korean adults. *Urologic Oncology* 2008 Nov-Dec;26(6):590-4.
- Haas GP, Shumaker BP, Cerny JC. High incidence of benign testicular tumors, *J Urol*. 1986, Dec; 136(6): 1219-1220.
- Kressel K, Schnell ID, Thon WF, et al. Benign testicular tumours: a case for testis preservation? *Eur Urol*. 1988; 15: 200-4.
- Robertson GS. Radical orchidectomy and benign testicular conditions. *Br J Surg*. 1995. Mar, 82(3): 342-345.
- Robson CJ, Bruce AW. Testicular tumors; A Collective review from Canadian Academy of Urological surgeon; *J. Urol*; 1965; 94:440.
- Duncan W, Munro AJ. The management of testicular seminoma: Edinburgh 1970-1981. *Br J Cancer*. 1987;55(4):443-8.
- Reddy DB, Ranganayakamma I; Review of 56 cases of Testicular tumors; *Indian J cancer*; 1966; 3: 255-271.
- Moghe KV, Agrawal RV, Junnerkar RV, Testicular tumors; *Indian J cancer*; 1970: 90-97.
- Nayak BS. Why the left testis hangs at a lower level than the right? *Medical Hypotheses*. 2009 Aug; 73(2):269-70.
- Mylonas I, Schiessl B, Jeschke U, Vogl J, Makrigiannakis A, Kuhn C, et al.

Expression of inhibin/activin subunits alpha (-alpha), beta A (-beta (A)) and beta B (-beta (B)) in placental tissue of normal and intrauterine growth restricted (IUGR) pregnancies. *J Molecular Histol* 2006 Jan;37(1-2):43-52.

16. McGlynn KA, Graubard BI, Klebanoff MA et al. Risk factors for cryptorchism among populations at differing risks of testicular cancer. *Int J Epidemiol*. 2006 Jun; 35(3): 787-795.
17. Ferguson L, AgoulNIK AI. Testicular cancer and cryptorchidism. *Front Endocrinol (Lausanne)*. 2013; 4: 32.
18. Das P, Abhuja A, Datta Gupta S. Incidence, etiopathogenesis and pathological aspects of genitourinary tuberculosis in India: A journey restricted. *Indian J. Urol* 2008; 24: 356-361.
19. Kapoor R, Ansari MS, Madhavi A, Gulia A. Clinical presentation and diagnostic approach in cases of genitourinary TB. *Indian J Urol* 2008; 24: 401-405.
20. Mostofi FK, Price EB Jr. Tumors of the male genital system. *Atlas of Tumor Pathology, Fascicle 7, Series 2*. Washington, DC: Armed Forces Institute of Pathology 1973; p. 1186-200.
21. Vural F, Cagirgan S, Saydam G, Hekimgil M, Soyer NA, Tombuloglu M. Primary testicular lymphoma. *J Natl Med Assoc*. 2007;99(11):1277-82.