



Effect of Mobile Phone Radiation on Pancreas of Rats

Authors

Shalini Gupta¹, Shilpi Jain², Satyam Khare³, Prateek Gautam⁴

^{1,4}Department of Anatomy, BRD Medical College, Gorakhpur

^{2,3}Department of Anatomy, Subharti Medical College, Meerut

*Corresponding Author

Dr Shalini Gupta

Department of Anatomy, BRD Medical College Gorakhpur, India

Phn-8874104992, Email: Guptashalini22@yahoo.com

Abstract

Mobile phones are now a part and parcel of our life. We all are well aware of its use but the other side of the coin says that it is also causing great damage to our body. Keeping this factor in mind the main aim and objective of my study is to read the effect of mobile phone radiations on various changes occurring in pancreatic tissues of male Sprague Dawley rats. In order to carry out the experiment male rats of weighting 90-110 gms which were divided into two groups i.e. control and experimental were subjected to mobile phone radiations for a duration of 3 months continuously for one hour daily in specially designed cage for exposing them to radiations. At the end of each month both the groups of rats were sacrificed and pancreatic tissues were collected and underwent processing to obtain histological slides stained with H&E. Also fasting blood glucose level was measured of both the groups of rats. The experiment showed that Control group of rats showed the normal histological picture i.e. well formed acini and islet of Langerhans, however rats sacrificed from experimental group of first month also showed more or less normal histological picture as that of control group. Rats sacrificed after second month of radiation doses showed changes in the histological picture as the acini showed disturbances in architecture also the blood vessels showed engorgement. A completely distorted histological picture which could be very well appreciated was observed after the study of slides obtained by the sacrifice of rats which underwent 3 months of radiation exposure. As far as the fasting glucose level is concerned it also showed a continuous increase with increase in the dose of radiation which may be due to effect of radiation on beta cells of pancreas. Hence it was concluded that the radiation which is emitted from the mobile phone has a damaging effect on pancreatic tissues of rats and hence its metabolism.

Keywords: mobile radiation, pancreas, microscopic picture, glucose level.

Introduction

Technology has introduced a device called as mobile phones for the benefit of mankind. It is now widely used by people all over the world. The emergence and evolution of mobile phones is one of the fastest in the history of innovation⁽¹⁾. It is being used both by adults and children. The number of mobile phone users is constantly increasing and estimated total number of mobile

phone users worldwide has surpassed 4.8 billion. This means that almost more than two-thirds of the world population is using this technology⁽²⁾. Electromagnetic Radiation (EMR) being emitted by variety of sources have become a very frequent source of contamination for the human environment due to production of non-ionizing radiation (NIR)⁽³⁾.

This phenomenon has raised concerns about the possible hazards of the electromagnetic field radiation emitted by mobile phones on human health^(4,5,6,7,8,9).

The EMF radiation generated by mobile phones can inflict its results through both thermal and non-thermal effects^(10,11).

Despite the large number of studies published over a decade, it still remains uncertain that their use may lead to serious debilitating problems in the different body structures while placing the mobile phones or during its use^(12,13,14,15)

Mobile phones are mainly placed in the front or side pockets (close to the heart, liver and pancreas) or hung with a waist belt (close to the reproductive organs). The excessive use of mobile phones has been followed by common public debate about possible adverse effects on human health. Thus, the present study was designed to investigate the effects of the Electromagnetic Field Radiation (EMFR) generated by mobile phones as regards the morphological findings in the 1 pancreata of albino rats.

Aims and Objective

To uncurtain the effect of electromagnetic radiation being emitted by mobile phone radiation on pancreas of rats & its microscopic study.

Material and Methods

The entire study was conducted in the Department of Anatomy of BRD Medical College, Gorakhpur Uttar pradesh.

Animal model

A total of 42 male albino rats of spargue dawley species with age of around 2 months and weighing 100-120 gm (fig1) with same genetic background and knowing disease free were recruited for the experiment. The animals after the procurement underwent acclimitization for around one week during which they underwent 12 hourly day and night cycle and were fed with their diet with water ad-libidum.⁽¹⁶⁾ the experimental animal protocol was approved by the animal ethical committee of

college board and the experiment were performed according to the suggested guidelines.

Experimental Protocol

Albino rats were equally divided into 2 groups one control and other experimental having 21 rats each. Group A rats which were the control rats were given the same environment as that of group B rats which were the experimental one except exposure to radiation. They were even kept in different rooms to avoid any exposure with mobile phone. However Group B rats were exposed to mobile phone radiations

Radiation Set Up

Normal plastic cage available for rats were taken and the base of it were carpeted with thermocol sheet. The cage was partitioned using a wooden plank and the area seperated was fitted with mobile phone of GSM model with frequency bandwidth of 900 MHz, power of 2 watt & SAR value of 0.38 W/Kg.(Fig 2)

When the experiment was started a call was given on the mobile phone being kept in the cage and it is kept on answering mode for a duration of 3 hours.

During this the rats remain in touch with the mobile phone and were receiving the radiations same as that of human being interacting on mobile and keeping it near its body.^(17,18,19) (Fig 3)

This entire experiment was repeated for 6 months and at the end of every 2 months 7 rats from each group were sacrificed and blood sample was collected and sent to lab for glucose analysis.

Histopathological examination

After the sacrifice of rats pancreas were collected and kept in 10 % of formalin and the tissues were processed using routine tissue processing technique and were stained with Hematoxylin and eosin. Tissue slides were prepared and were examined both under high and low power magnification.

Statistical analysis

The data obtained for the level of glucose was analysed and mean and standard deviation was calculated and t-test was applied on the data.

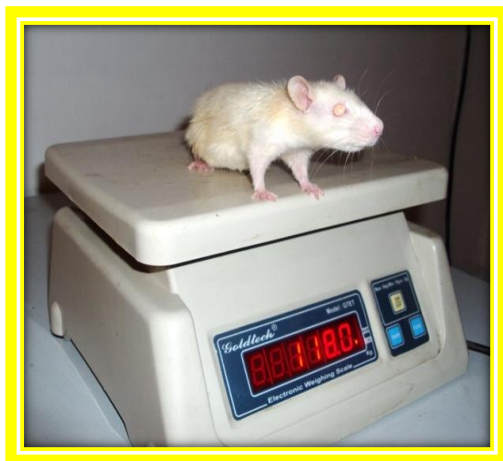

Fig 1: Albino Rats Getting Weighed.



Fig 2: Radiation set up in cage.



Fig 3: Rats undergoing exposure to mobile phone radiations during experiment.

Observation

Fasting Blood Glucose in Rat

Normal fasting blood glucose level in rat: 80-120 mg/dl

Table 1: Table showing mean of blood glucose level in control vs experimental group of rats

Month	Fasting glucose level in mg/dl	
	Control (mean)	Experimental (mean)
2 nd month	88 mg/dl	100mg/dl
4 th month	90mg/dl	112mg/dl
6 th month	82mg/dl	159mg/dl

Table 2: Comparison of glucose of experimental and control group of Rats for 2nd month

R.no	1 st day		2 nd month	
	Control	Experimental	Control	Experimental
1	81	86	88	100
2	83	81	81	102
3	88	98	94	106
4	82	100	83	110
5	83	105	85	109
6	101	80	103	110
7	94	107	99	111

Table 3: Difference in glucose of rats after 2 months

R.no	Control	Experimental
1	7	14
2	2	21
3	6	8
4	1	10
5	2	4
6	2	30
7	5	4

Table 4: Comparison of glucose of experimental and control group of Rats for 4th month

R.no	1 st day		4 th month	
	Control	Experimental	Control	Experimental
1	91	82	106	112
2	81	92	108	114
3	85	93	99	118
4	88	87	98	120
5	88	85	101	121
6	93	87	103	112
7	85	84	98	117

Table 5: Difference in glucose of rats after 4 months

R.no	Control	Experimental
1	15	30
2	27	22
3	14	25
4	10	33
5	13	36
6	10	25
7	13	33

Table 6: Comparison of glucose of experimental and control group of Rats for 6th month

R.no	1 st day		6 th month	
	Control	Experimental	Control	Experimental
1	90	98	103	132
2	100	97	106	136
3	81	99	89	140
4	84	92	101	143
5	89	103	83	146
6	87	105	99	148
7	86	97	97	141

Table 7: Difference in glucose of rats after 6 months

R.no	Control	Experimental
1	13	34
2	6	39
3	8	41
4	17	51
5	6	43
6	12	43
7	11	44

Microscopic Finding

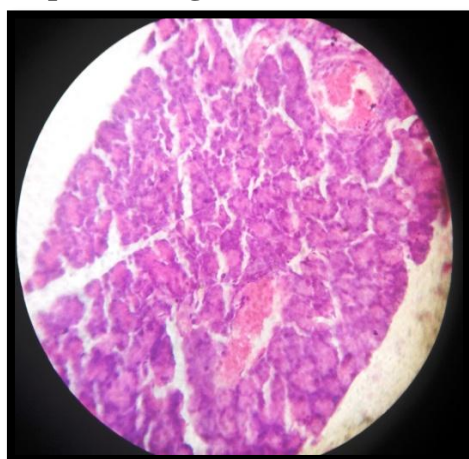


Fig 4:- Microscopic picture showing control group of rats.

1. Control: Majority is formed by the presence of exocrine part of pancreas that

is the serous cells. Arranged in small lobule.

2. Lobules are demarcated by thin connective tissue septa.
3. Within the serous acini are the isolated pancreatic acini called as Pancreatic islets which represent the endocrine part.
4. Presence of duct is well appreciated

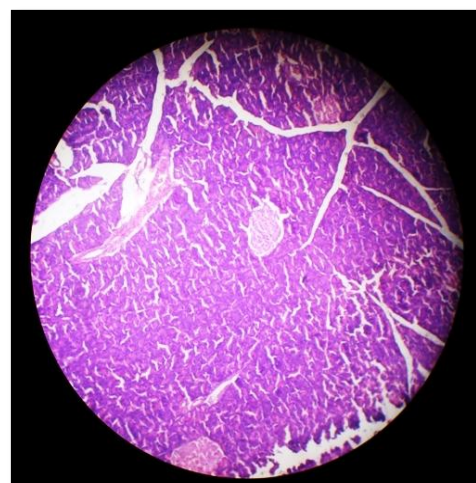


Fig 5:- Microscopic picture showing 2nd month of experimental group of rats.

2nd Month

No major appreciable changes were observed in the microscopic structure of pancreas.

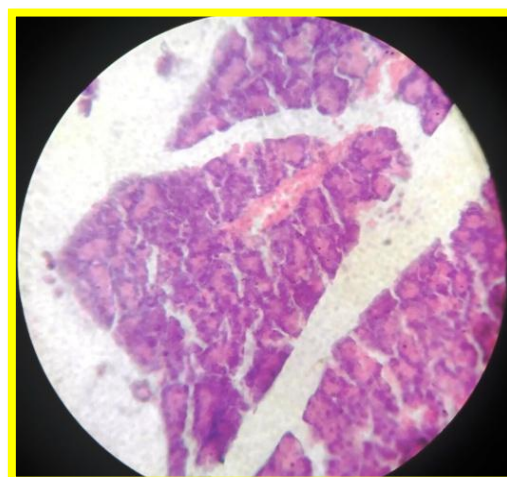


Fig 6: Microscopic picture showing 4th month of experimental group of rats.

4th Month

Rats sacrificed after second month of radiation doses showed changes in the histological picture as the acini showed disturbances in architecture also the blood vessels showed engorgement.

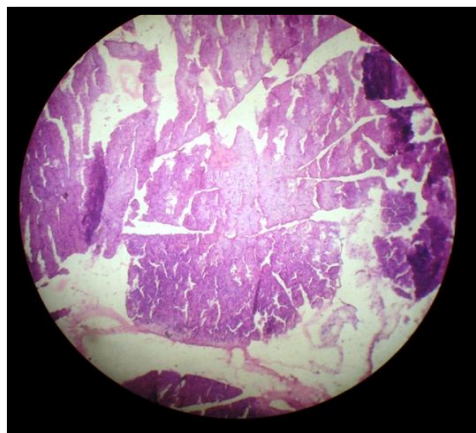


Fig 7a:- Microscopic picture showing 6th month of experimental group of rats.

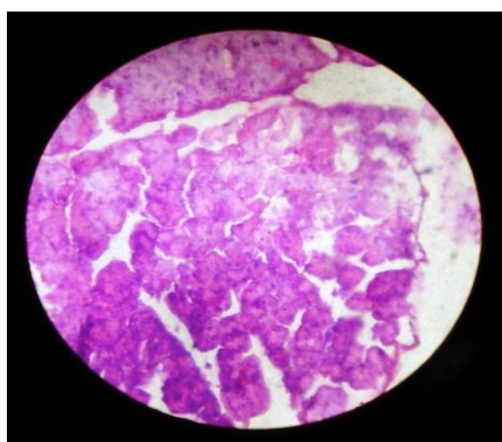


Fig 7b:- Microscopic picture showing 6th month of experimental group of rats at higher magnification.

6th Month

Clear distinction of acini was missing.
Shape of the acini were found distorted

Results

Glucose analysis

Table 8: Statistical analysis of glucose level at 2nd month

Group	Mean	SD	P-Value
Control	98.14285714	6.593647737	0.085
Experimental	105.5714	8.182443	

Table 9: Statistical analysis of glucose level at 4th month

Group	Mean	SD	P-Value
Control	119	3.545621042	0.31
Experimental	115	9.433981	

Table 10: Statistical analysis of glucose level at 6th month

Group	Mean	SD	P-Value
Control	115	9.433981132	0.0013(very significant)
Experimental	137	10.36018	

As per the analysis of glucose level during six month of studies we found that there is a continuous increase in the level of glucose with increase in the dose of radiation. (table 1)

Even the statistical analysis of the data says that value obtained during 6th month of study is quite statistically significant.(table 10)

Microscopic Analysis

1. After the 2nd month of exposure no major changes which could be appreciated were seen at the microscopic level.(fig 5)
2. After the 4th month of exposure there occurs a disturbance in acini of pancreas architecturally and also the blood vessels were engorged.(fig 6)
3. After the 6th month of exposure clear cut distinction of the acini was missing and the architecture was very much distorted. Also the blood vessels were more engorge.(fig 7a,b)

Discussion

The Electromagnetic Field Radiation generated by mobile phones may affect different organs and their functions via three mechanisms: an EMW-specific effect; a thermal molecular effect, or a combination of both⁽²⁰⁾. Animal model studies have shown that electromagnetic field radiation generated by mobile phones has a broad range of damaging effects on different organs/systems. As far as the present study is concerned, we found that long-term use of mobile phones can cause inflammation in pancreatic cells of albino rats as compared to their matched control. Moreover, the pancreatic inflammation increased with the duration of exposure to mobile phone radiation. Imaida et al.⁽²¹⁾ conducted a study on rats exposed to nearfield EMR. They reported that the histopathological findings in the pancreas revealed

changes, but the differences among the groups were not significant.

Oral et al.⁽²²⁾ observed that exposure to 900-MHz radiation emitted by mobile phones can cause endometrial apoptosis and oxidative stress in rats. Lahijani et al.⁽²³⁾ demonstrated the histopathological and ultra-structural change in the livers of preincubated chicken embryos exposed to EMFs. Keeping in mind the results of previous studies, it can be ascertained that long term use of mobile phones can cause several effects, including inflammation of the pancreas. Since there was not much literature in descriptions of any association of mobile phones and their effects on pancreatic cells, in the present study we were prompted to study the morphological and histological findings in pancreatic cells of albino rats.

Conclusion

- 1) There is increase in the level of glucose with increase in the exposure which is even statistically significant and may be due to disturbance in beta cells of pancreas.(table 1)
- 2) With increase in duration of time and exposure changes are taking place in pancreas at microscopic level.(Fig 6,7a,b)

Since exposure to mobile phone radiation is causing changes at the level of glucose and even at microscopic level of pancreas this may be a predisposing factor for diabetes.

Hence we should use this device very judiciously.

References

1. COLONNA A (2005). Cellular phones and cancer: current status. *Bull Cancer*, 92: 637-643.
2. WORLDWIDE MOBILE PHONE USERS (2009). More than four billion mobile phone users worldwide (Accessed dated Nov 24, 2009). Available at <http://www.infobalt.lt/main.php?&a=0&i=7983>.
3. BORIS Đ, DUŠAN S, DEJAN K, DEJAN P, JOVICA J, MARJAN M (2010). Biochemical and histopathological effects of mobile phone exposure on rat hepatocytes and brain. *Acta Medica Medianae*, 49: 37-42.
4. STUCHLEY MA (1988). Biological effects of radiofrequency fields. In: Repacholi MH (ed). *Non-Ionizing Radiations: Physical characterization, Biological effects and Health Hazard Assessment*. Proceedings for the International Non-Ionizing Radiation Workshop, Melbourne, pp 197-217.
5. MAIER M, COLIN B, KOIVISTO M (2000). The health hazards of mobile phones. *Brit Med J*, 320: 1288-1289.
6. AL-KHALAIWI T, MEO SA (2004). Association of mobile phone radiation with fatigue, headache, dizziness, tension and sleep disturbance in Saudi population. *Saudi Med J*, 25: 732-736.
7. MEO SA, AL DREES AM (2005). Mobile phone related hazards and subjective hearing and vision symptoms in the Saudi Population. *Intl J Occupational Med Environm Health*, 18: 53-57
8. KARGER CP (2005). Mobile phones and health: Literature overview. *Z Med Phys*, 15: 73-85
9. KLEINLOGEL H, DIERKS T, KOENIG T, LEHMANN H, MINDER A, BERZ R (2008). Effects of weak mobile phone-electromagnetic fields (GSM, UMTS) on well-being and resting EEG. *Bioelectromagnetics*, 29: 479-487.
10. DERIAS EM, STEFANIS P, DRAKELEY A, GAZVANI R, LEWISJONES DI (2006). Growing concern over the safety of using mobile phones and male fertility. *Arch Androl*, 52:9-14.
11. ACAR GO, YENER HM, SAVRUN FK, KALKAN T, BAYRAK I, ENVER O (2009). Thermal effects of mobile phones on facial nerves and surrounding soft tissue. *Laryngoscope*, 119: 559-562.

12. AITKEN RJ, BENNETTS LE, SAWYER D, WIKLENDT AM, KING BV (2005). Impact of radio frequency electromagnetic radiation on DNA integrity in the male germline. *Int J Androl*, 28: 171-179.
13. CHRISTENSEN HC, SCHUZ J, KOSTELJANETZ M, POULSEN HS, BOICE JD JR, MCLAUGHLIN JK (2005). Cellular telephones and risk for brain tumors: a population-based incident case-control study. *Neurology*, 64: 1189-1195.
14. MOULDER JE, FOSTER KR, ERDREICH LS, MCNAMEE JP (2005). Mobile phones, mobile phone base station and cancer: a review. *Int J Radiat Biol*, 81: 189-203
15. SHOEMAKER MJ, SWERDLOW AJ, AHLBOM A, AUVINEN A, BLAASAAS KG, CARDIS E (2005). Mobile phone use and risk of acoustic neuroma: results of the interphone casecontrol study in five North European countries. *Br J Cancer*, 93: 842-848.
16. SOKOLOVIC D, DJINDJIC B, NIKOLIC J, BJELAKOVIC G, PAVLOVIC D, KOCIC G (2008). Melatonin reduced stress induced by chronic exposure, of microwave radiation from mobile phone. *J Radiation Research*, 49: 579-586.
17. SOKOLOVIC D, DJINDJIC B, NIKOLIC J, BJELAKOVIC G, PAVLOVIC D, KOCIC G (2008). Melatonin reduced stressinduced by chronic exposure, of microwave radiation from mobile phone. *J Radiation Research*, 49: 579-586.
18. NARAYANAN SN, KUMAR RS, POTU BK, SATHEESHA N, MAILANKOT M (2009). Spatial memory performance of Wistar rats exposed to mobile phone. *Clinics*, 64: 231- 234.
19. GUL A, CELEBI H, UĞRAŞ S (2009). The effects of microwave emitted by cellular phones on ovarian follicles in rats, *Arch Gynecol Obstet*, 280: 729-733.
20. DASDAG S, KETANI MA, AKDAG Z, ERSAY AR, SARI I, DEMIRTAS OC (1999). Whole-body microwave exposure emitted by cellular phones and testicular function of rats. *Urol Res*, 27: 219.
21. IMAIDA K, TAKI M, YAMAGUCHI T, ITO T, WATANABI S-I, WAKE K, AIMOTO A, JAJTE J, GRZEGORCZYK J, ZMYSLONY M, RAJKOWSKA E (2002). Effect of 7 mT static magnetic field and iron ions on rat lymphocytes: apoptosis, necrosis and free radical processes. *Bioelectrochemistry*, 57: 107-111.
22. ORAL B, GUNNEY M, OZGUNER F, KARAHAN N, MUNGAN T, COMLEKCI S, CESUR G (2006). Endometrial apoptosis induced by a 900-MHz mobile phone: Preventive effects of vitamins E and C. *Advances in Therapy*, 23: 957-973.
23. LAHIJANI MS, TEHRANI DM, SABOURI E (2009). Histo - pathological and ultrastructural studies on the effects of electromagnetic fields on the liver of preincubated white Leghorn chicken embryo. *Electromagn Biol Med*, 28: 391-413.