



Comparison of Standard Brain Technique & 90⁰ Rotational Technique of Proseal LMA Insertion in Adults

Authors

**Narasimhanmk¹, Chitra Devi¹, Karthik Prakasam², Mohamed Ashiq.M³,
Gowri Shankar Anjaneyan⁴, Satish Logidasan⁵, Kanimozhi Rathinasamy⁶,
Arulraj Panchatcharam⁷, Prasana Vadhanan⁸, SR Karthik⁹, Satish C¹⁰**

Govt Stanley Medical College, TN- 600001, India

Corresponding Author

Satish Logidasan

Department of Anesthesiology, Govt Stanley Medical College, TN- 600001, India

Email: drsathishlogi@gmail.com

Introduction

The laryngeal mask airway (LMA) is a supraglottic airway device, developed by Dr. ARCHIE BRAIN of the United Kingdom in 1981. He describes it as an alternative device to either the endotracheal tube or the face mask for either spontaneous or positive pressure ventilation¹. The most important feature of the LMA is that it provides a rapid control over the airway. It is faster and easier to insert LMA than the endotracheal intubation¹. The Proseal Laryngeal mask airway (Proseal LMA) was designed by Dr. Archie Brain in 2000 which he describes as an LMA with an oesophageal vent². The Proseal LMA is a revolutionary new airway device with modifications to separate the respiratory and gastrointestinal tracts thereby providing an improved seal and reducing the risk of aspiration, regurgitation and gastric insufflation.

The manufacturer recommends using two methods for inserting the Proseal LMA³; using digital insertion technique like LMA classic (index finger or thumb technique) or with an introducer tool like the intubating LMA. Several techniques have hence been described to improve the insertion success rate. Drolet and Girard⁴ described the use of a gastric tube, Brimacombe and Keller⁵ the use of fiberoptic bronchoscopy, Howarth et al⁶ the use of a gum elastic bougie and Garcia Aguado et al⁷ the use of a suction catheter for Proseal LMA insertion. The main cause of failed insertion was identified as impaction at the back of the mouth⁸, and a slight lateral approach has been used to manoeuvre around when a tactile resistance was felt at the back of the mouth. Another technique used to insert the Proseal LMA, the 90⁰ rotational technique, has been described in several studies. In these studies they hypothesized that insertion of Proseal LMA with a 90-degree rotation would reduce the contact surface between the Proseal LMA and the pharyngeal wall and make it easy to advance the Proseal LMA around the lateral surface of the tongue and over the smooth angle against the posterior pharyngeal wall into the hypopharynx.

Keywords-laryngeal mask airway (lma), supraglottic airway device, proseallma

Aim of the Study

To compare the two techniques of Proseal LMA insertion, the standard Brain technique and 90⁰

rotational techniques, in terms of first attempt success rate in adult patients planned for elective surgical procedures.

All consented patients of age 18 to 80 years of both genders, ASA I or II, Elective surgeries of duration 30-180 minutes under GA in supine position, Mouth opening > 2.5cm, MP I & II, TMD > 6 cm were included in the study.

Patients younger than 18 years and older than 80 years, Restricted mouth opening < 2.5 cm, Patients with altered airway anatomy and anticipated difficult airway, MP III & IV, TMD < 6 cm, Recent sore throat, lower respiratory tract infection, Patients at risk of aspiration, non fasted, obesity (BMI > 30 kg/m²), Laparoscopic procedures and pregnant patients, Emergency surgeries were excluded from the study.

The selected patients were randomly assigned to 2 groups, group S (Standard technique) and group R (rotational technique). The patients were placed in the supine position with a standard pillow of height 8 cm. The patients were premedicated with Inj. Glycopyrrolate 0.01 mg/kg, Inj. Midazolam 0.02 mg/kg and Inj. Fentanyl 2mcg/kg intravenously. All the patients were induced with inj. Propofol 2 mg/kg iv, muscle relaxation achieved with inj. Atracurium 0.5mg/kg iv and ventilated for 3 minutes with N₂O 50%, oxygen 50% and sevoflurane 2%. Proseal LMA of appropriate size was inserted using either standard or rotational technique. Anesthesia was maintained with sevoflurane and intermittent muscle paralysis with inj. Atracurium 0.1 mg/kg IV.

GROUP S (standard): In group S, the Proseal LMA was inserted using the standard Brain technique. In this technique, first the cuff was fully deflated and the posterior aspect of the cuff was lubricated with a water soluble lubricant. The Proseal LMA was held like a pen with the index finger of the dominant hand in the groove formed between the airway tube and the laryngeal mask; the non dominant hand was used to open the mouth. Proseal LMA was inserted by pressing it against the palatopharyngeal curve using the index finger, and sliding it in a cranio-posterior direction and advancing into the hypopharynx until a definite resistance was met. Then the index finger was removed after the Proseal LMA was held in place by the non dominant hand.

Appropriate amount of air was used for cuff inflation. Proseal LMA was secured in place with adhesive plasters to maxilla. No introducer tool was used.

GROUP R (rotational): In group R, Proseal LMA was inserted using the 90⁰ rotational technique. In this technique, the cuff was deflated and lubricated on the posterior and lateral aspects with the same lubricant used in the standard technique group. The non dominant hand was used to open the mouth. The Proseal LMA was inserted until the entire cuff was inside the mouth without inserting finger. The Proseal LMA was then rotated counter clockwise through 90⁰ and advanced into the hypopharynx sliding around the tongue. When a definite resistance of the hypopharynx was felt, the Proseal LMA was straightened out by rotating it back through 90⁰ in the clockwise direction. The cuff was inflated with recommended volume of air and Proseal LMA secured in place with adhesive plasters.

The circuit was connected and an effective airway was judged by a continuous square-wave capnograph trace, bilateral equal chest expansion and no audible leak during gentle manual ventilation. The presence or absence of oropharyngeal air leaks (detected by listening over the mouth), gastric air leaks (detected by listening with a stethoscope over the epigastrium), drain tube air leaks (detected by placing a small bubble of lubricant jelly over the proximal end of the drain tube), or an end-tidal carbon dioxide greater than 45 mmHg was noted. The Proseal LMA was repositioned if any air leak was detected or if ventilation was ineffective (EtCO₂ > 45mmhg, inadequate chest expansion). A well-lubricated, 14-Fr nasogastric tube was inserted through the drain tube if there was no air leak up the drain tube. Correct placement of gastric tube was assessed by suction of fluid or detection of injected air by epigastric stethoscopy. Three attempts were allowed before insertion was considered a failure. Failed insertion was defined by any of the following criteria: (1) failed passage into the pharynx; (2) malposition (air leaks, and failed gastric tube

insertion if pharyngeal placement was successful); and (3) ineffective ventilation or end-tidal carbon dioxide >45 mmHg if correctly positioned. The etiology of failed insertion was documented. If insertion failed after three attempts, endotracheal intubation was done.

After successful placement of the Proseal LMA and an effective airway judged by the above described methods, The fiberoptic view of the glottic structures was then graded just proximal to the mask aperture in the airway tube. Ventilation was interrupted and a 2.8 mm well lubricated fiberoptic bronchoscope was passed down the airway tube till just before the opening of the airway tube in the mask bowl. The relationship of the mask bowl with the laryngeal inlet was visually assessed by an independent blinded observer and the grading done. The fiberoptic grading System used proposed by Brimacombe et al. (14, 15)

Grade	View
4	Only cords seen
3	Cords plus posterior epiglottis seen
2	Cords plus anterior epiglottis seen
1	Cords not seen, but function adequate
0	Cords not seen, failure to function

Ventilation was continued and the oropharyngeal leak pressure was recorded. Oropharyngeal leak pressure (OLP) was recorded by closing the expiratory valve of the circuit system at a fixed flow of 3 litres min⁻¹ and recording the airway pressure at which the dial on the aneroid manometer of the anesthesia machine reached a static pressure¹⁷.

At the end of surgical procedure patient was reversed with inj. Neostigmine 0.05mg/kg and inj. Glycopyrrolate 0.01mg/kg. Proseal LMA was removed in a fully awake patient after thorough oral suctioning. Proseal LMA was inspected for any visible blood staining on removal. The mouth, lips, and tongue was inspected for evidence of trauma.

Primary Outcome Measured: first attempt success rate

The ease of insertion of Proseal LMA was assessed by the success rate of insertion in the first attempt.

Secondary Parameters Observed

1. Time For Insertion

The time of insertion was measured from the time of picking up the Proseal LMA to confirmation of airway patency with Proseal LMA in place by auscultation and continuous square wave capnography in the first attempt.

2. Number Of Attempts

Three attempts were allowed for a single technique. If Proseal LMA cannot be inserted after three attempts the patient’s airway was secured with endotracheal intubation. The reasons for the re-attempts were also recorded.

3. Failures and the etiology of failure

If a fourth attempt was needed it was considered a failure and the patient was intubated with endotracheal tube of appropriate size. The etiology of the failure was also recorded.

4. Fiberoptic grading after Proseal LMA placement

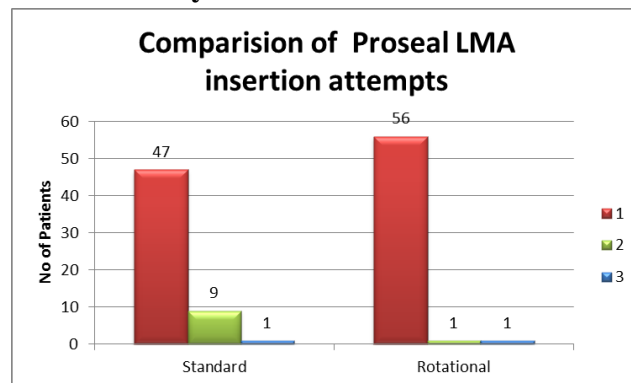
5. Oropharyngeal leak pressure

6. Blood staining of Proseal LMA, detected by inspection of Proseal LMA after removal

7. Incidence of other intraoperative complications was also noted if any.

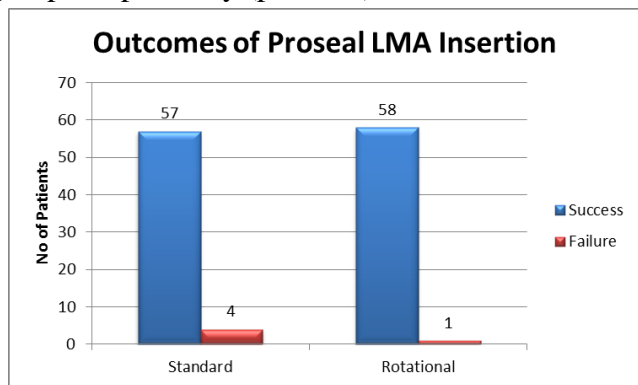
All cases were conducted by a single experienced user (more than 2 years of experience in Proseal LMA insertion) who was not blinded to the technique. The time taken for insertion in the first attempt, number and reasons for re-attempts, etiology of failure, fiberoptic grading, any visible or occult blood staining on Proseal LMA removal, evidence of trauma to lips, mouth or teeth were all recorded by a blinded independent observer.

Statistical analysis

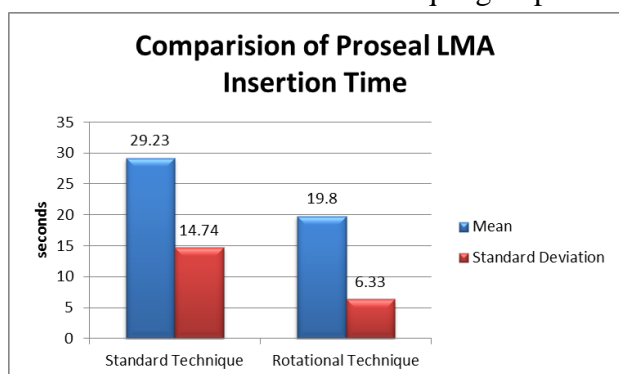


Number of attempts for Proseal LMA Insertion among group S (standard) and R (rotational). The first attempt success rate in Proseal LMA insertion

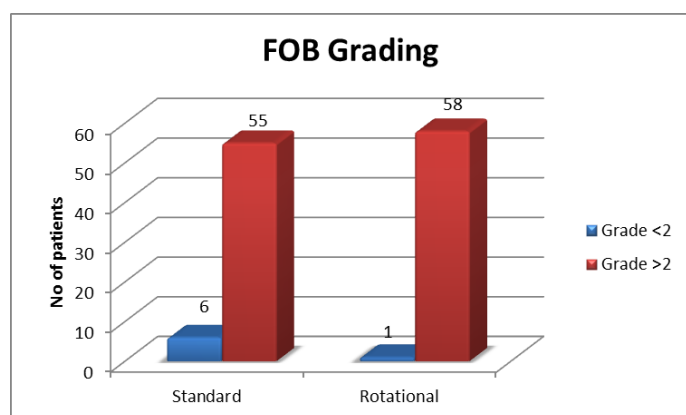
was 95% and 82% in Rotational and Standard groups respectively ($p < 0.05$)



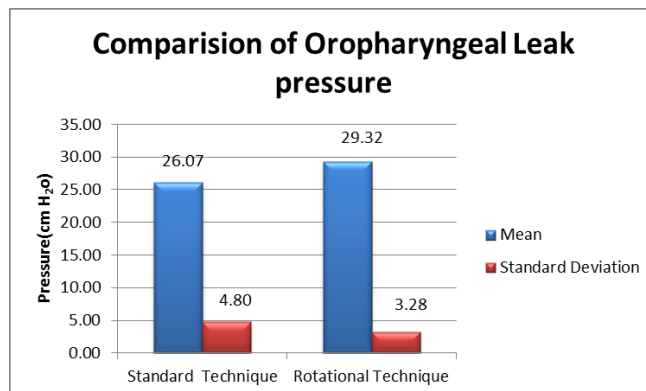
In simple terms Proseal LMA– Rotational Technique is superior to the Proseal LMA – Standard Brain Technique in terms of insertion outcomes with an overall success rate of 98% in Proseal LMA – Rotational Technique group and 93% in Proseal LMA – standard Technique group.



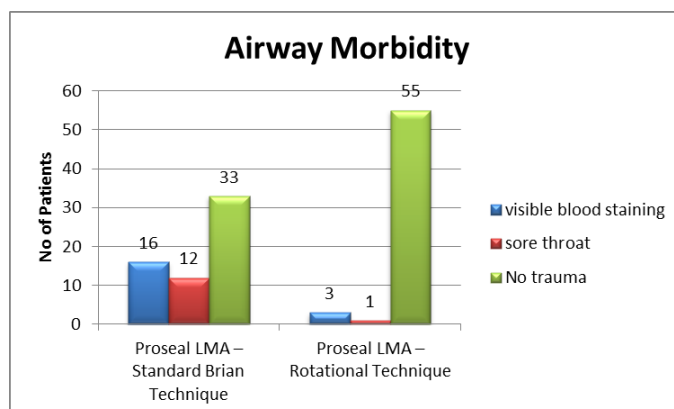
The time for successful insertion was meaningfully less in the Rotational group compared to the Standard group ($p < 0.0001$).



The association between the techniques and post insertion fiberoptic grading of Proseal LMA is considered to be statistically not significant since $p > 0.05$.



The association between the techniques and oropharyngeal leak pressure is considered to be not statistically significant since $p > 0.05$.



In simple terms by using the Proseal LMA– Rotational Technique, the incidence of blood staining and sore throat are reduced to 5% and 2% respectively.

Discussion

Our study shows that the 90 degree rotational technique improves the first attempt success rate; reduces the time required to insert the Proseal LMA and the incidence of airway related complications in adults.

The Proseal LMA was reportedly more difficult to insert using standard Brain technique because the presence of a larger cuff makes it difficult to place in the oral cavity and leaves little room for insertion of an index finger or thumb. The 90 degree rotational technique was proposed to overcome the problems of insertion by simple insertion of the Proseal LMA into the oral cavity without the finger and rotating it around the tongue to advance it till the hypopharynx where it is rotated back to its original position. It was more convenient because it

does not require any additional devices like the bougie or introducer tool. Although both methods of Proseal LMA insertion were satisfactory, the 90 degree rotational technique improved the ease of insertion as assessed by the first attempt success rate of insertion. In our study we found first attempt success rate of 95% for rotational technique and 82% ($p = 0.028$) success rate for standard technique which is a statistically significant result similar to the previous studies. Jung-won Hwang et al²² found that the first attempt success rate for standard technique was 85% and that of rotational technique was 100% ($p < 0.001$). Young Tae Jeonet al²³ found first attempt success rate of 100% for rotational technique and 83.5% ($p = 0.03$) for standard technique. Mi-Ja Yun et al²⁴ also reported a 97% success rate for rotational technique and 70% ($p < 0.01$) success rate for standard technique.

Nine patients in the standard technique group required a second attempt for Proseal LMA insertion whereas only one patient required a second attempt in the rotational technique group. A third attempt for Proseal LMA insertion was required in one patient in both the groups. Hence a significant number of reattempts was needed in the standard technique group than the rotational technique group ($p = 0.028$). In the standard technique group we encountered four failures whereas in the rotational technique group we failed to insert the Proseal LMA in one patient. The overall success rate of insertion of Proseal LMA was 98% in the rotational technique group and 93% in the standard technique group and was statistically significant ($p = 0.001$). These results were similar to the results obtained in previous studies. Hwang et al⁹ found that the overall success rate for standard technique was 94% and that of rotational technique was 100% ($p < 0.001$). Mi-Ja Yun et al¹¹ also reported an overall success rate of 100% for the rotational technique and 95% for the standard technique.

The time to complete insertion of Proseal LMA in the first attempt was 29.23 ± 14.74 seconds using standard technique and was 19.8 ± 6.33 seconds ($p = 0.0001$) using rotational technique. The results were similar to a previous study by Young-Tae

Jeonet al²³ where they reported longer insertion time 19 ± 16 seconds for standard technique than 11 ± 3 seconds ($p = 0.03$) for rotational technique. In contrast to our results, Jung-won Hwang et al⁹ et al found that insertion technique made no difference to insertion time. In their study the mean time for insertion of Proseal LMA for standard technique was 10 ± 7 seconds and rotational technique was 8 ± 3 seconds ($p > 0.05$, not significant).

In our study after successful placement of the Proseal LMA, we used a fiberoptic bronchoscope to visually assess if any residual rotation or malposition was present. We used a grading system devised by Brimacombe J et al¹⁴ to score the fiberoptic view of the glottis after placement of Proseal LMA. We found no significant difference in the fiberoptic grading among the two techniques ($p > 0.05$). The vocal cords were seen in more than (>grade 2) 94% of the cases. This is in accordance with the findings of previous studies reporting the fiberoptic view of the larynx via the Proseal LMA.^(12,16) Even though the different scoring systems used make direct comparisons difficult, the vocal cords were seen in > 80% of cases with mean 84.7%.¹³

The oropharyngeal leak pressure estimated in our study had no significant difference among the two groups. The 90 degree rotational group had a mean oropharyngeal leak pressure of 29.32 ± 3.28 cm H₂O vs 26.07 ± 4.80 cm H₂O for the standard group which was not statistically significant ($p = 0.9225$). This implies that both techniques were comparable in the oropharyngeal leak pressures attained. This is in accordance to Young-Tae Jeonet al⁹ where they found similar airway seal pressures between the standard and rotational groups (25 ± 7 vs 27 ± 6 cm H₂O; respectively) with no significant difference. The average airway seal pressure reported in 24 studies and 2,017 Proseal LMA uses ranges from 23 cm H₂O to 32cm H₂O.¹³

Oropharyngeal trauma is one of the common complications of Proseal LMA insertion due to its larger size compared to the classic LMA. Compared to endotracheal tube intubation, the trauma is significantly reduced with Proseal LMA¹³. The

incidence of trauma is analyzed by the presence of blood on Proseal LMA tip. In our study, the 90 degree rotational technique reduced the incidence of mucosal bleeding (5%) and sore throat (2%) compared with the standard index finger insertion technique, suggesting that the rotational technique causes less pharyngeal trauma. The decreased incidence of complications may be associated with reduced resistance between the tip of the Proseal LMA and the posterior pharyngeal wall. Many studies reported decreased incidence of blood staining of Proseal LMA tip when using rotational technique⁽⁹⁻¹¹⁾.

In our study we had no case of respiratory obstruction, laryngospasm, cough and hoarseness of voice. This may be due to difference in induction techniques used and the plane of anesthesia at the time of Proseal LMA insertion. Many researchers have reported varying incidences of laryngospasm¹³. Those studies commonly used inhalational induction alone for Proseal LMA insertion. Inhalational induction needs longer duration to achieve correct plane of anesthesia.

In our study, we had four failures in the standard group and one failures in the rotational group which was statistically significant ($p = 0.001$). The overall success rate of insertion in the rotational group was 98% compared to the standard group 93%. All the five patients who had failed insertion with standard technique or the rotational technique had been intubated with appropriate size endotracheal tube.

Summary

The standard Brain technique is the recommended technique of Proseal LMA insertion in adults. The 90 degree rotational technique is another technique used for Proseal LMA insertion with improved success rate and lower incidence of complications.

In a randomized comparative study, 120 adults aged 18 to 80 years of ASA I and II physical status were randomly allocated in two groups, in which Proseal LMA is inserted using either standard Brain technique (Group S) or rotational technique (Group R).

All the patients were assessed for insertion time, number of attempts required for successful placement, failures and etiology of failure, pre and post insertion hemodynamic parameters, fiberoptic grading after placement, oropharyngeal leak pressure, occurrence of airway related trauma and complications.

The groups were comparable for age, sex, height, weight, BMI, choice of Proseal LMA size, Mallampatti classification and duration of surgeries. Our observations were,

- The first attempt success rate was higher for 90° rotational technique than standard technique.
- Time to complete Proseal LMA insertion in first attempt was shorter with 90° rotational technique than the standard technique. It is a statistically significant result.
- In our study there is a decreased incidence of blood staining of Proseal LMA tip and sore throat in the 90° rotational technique group.

Conclusion

We conclude that the 90° rotational technique is better than the standard Brain technique for Proseal LMA insertion in adults in terms of ease of insertion assessed by the first attempt success rate. We also suggest the 90° rotational technique as an alternate better method over the standard technique routinely used for Proseal LMA insertion.

Bibliography

1. Brain AIJ. The laryngeal mask – a new concept in airway management. *Br J Anaesth* 1983; 55: 801–805.
2. Brain AI, Verghese C, Strube PJ. The LMA ‘ProSeal’ - a laryngeal mask with an oesophageal vent. *Br J Anaesth* 2000; 84: 650–4.
3. LMA™ Airway Instruction Manual. San Diego, LMA North America, 2013
4. Drolet P, Girard M: An aid to correct positioning of the ProSeal laryngeal mask. *Can J Anaesth* 2001; 48:718–9

5. Brimacombe J, Keller C: Awake fiberoptic-guided insertion of the ProSeal Laryngeal Mask Airway. *Anaesthesia* 2002; 57:719
6. Howath A, Brimacombe J, Keller C, Kihara S: Gum elastic bougie-guided placement of the ProSeal laryngeal mask. *Can J Anaesth* 2002; 49:528–9
7. Garcia Aguado R, Vinales J, Brimacombe J, Vivo M, Lopez-Estudillo R, Ayala G: Suction catheter guided insertion of the ProSeal laryngeal mask airway is superior to the digital technique. *Can J Anaesth* 2006; 53:398–403
8. Brimacombe J, Keller C: The ProSeal laryngeal mask airway: A randomized, crossover study with the standard laryngeal mask airway in paralyzed, anesthetized patients. *Anesthesiology* 2000; 93:104–9
9. Young-Tae Jeon, Hyo Seok Na. Insertion of the ProSeal laryngeal mask airway is more successful with the 90 rotation technique. *J Can Anesth* (2010) 57:211–215
10. Mi-Ja Yun, Jung-Won Hwang. The 90 rotation technique improves the ease of insertion of the ProSeal™ laryngeal mask airway in children. *J Can Anesth* (2011) 58:379–383
11. Kihara S, Brimacombe J. Sex-based ProSeal laryngeal mask airway size selection: a randomized crossover study of anesthetized, paralyzed male and female adult patients. *Anesth Analg* 2003; 97:280–284.
12. Christodoulou C. ProSeal laryngeal mask airway foldover detection. *Anesth Analg* 2004; 99:312–313.
13. Brimacombe J. Insertion of the laryngeal mask airway – a prospective study of four techniques. *Anaesth Intens Care* 1993; 21: 192
14. Keller C, Brimacombe J. A fibre optic scoring system to assess the position of laryngeal mask airway devices. Inter observer variability and a comparison between the standard, flexible and intubating laryngeal mask airways. *Anaesthesiol Intensivmed Notfallmed Schmerzther* 2000; 85: 262 - 6
15. Evans NR, Gardner SV, James MF, et al. The Proseal laryngeal mask: results of a descriptive trial with experience of 300 cases. *Br J Anaesth* 2002; 88: 534–9.
16. Ghai B, Ram J, Makkar JK, Wig J, Fiber-optic assessment of LMA position in children: a randomized crossover comparison of two techniques. *Pediatric anesthesia* 2011; 21; 623 – 712.
17. Tan SM, Sim YY, Koay CK. The ProSeal laryngeal mask airway size selection in male and female patients in an Asian population. *Anaesth Intensive Care* 2005; 33: 239–42.