JMSCR Vol||06||Issue||01||Page 32359-32362||January 2018

www.jmscr.igmpublication.org
Impact Factor 5.84
Index Copernicus Value: 71.58
ISSN (e)-2347-176x ISSN (p) 2455-0450
crossref DOI: https://dx.doi.org/10.18535/jmscr/v6i1.150

IGM Publication
Journal Of Medical Science And Clinical Research
An Official Publication Of IGM Publication

Case Report - Patent Urachus

Authors
Dr R. Jayavarmaa M.S.[1], Dr J. Kabalimurthy M.S.[2]
[1]Postgraduate, Department of General Surgery, Rajah Muthiah Medical College, Chidambaram
[2]Professor and Head, Department of General Surgery, Rajah Muthiah Medical College, Chidambaram
Corresponding Author
Dr R. Jayavarmaa
Dept of General Surgery, Rajah Muthiah medical college, Annamalai University, Chidambaram – 608002
drjai92@gmail.com, doctorkabali@gmail.com
9976813400, 9994360502

Abstract
The epithelial tubular structure located in the midline that spreads from the anterosuperior part of the bladder to the umbilicus is called Urachus. It connects the apex of the urinary bladder with the allantois in the fetus. When the urachal tract is not obliterated completely during embryonic development, urachal abnormalities occurs which include bladder diverticulum, urachal cyst, umbilical polyp, or patent urachus. This is the case report of a 40 year old woman who presented to the OP with abdominal pain over umbilical region for 2 weeks and foul smelling purulent discharge from the umbilicus for 1week. Physical examination and radiological investigations revealed umbilical abscess. On exploration abscess was drained and a striated structure was present between the bladder and the umbilicus and it is found to be the patent urachus. Patent urachus and other congenital urachal anomalies in adulthood are rare. Often it present as acute abdominal pain which may be inconspicuous. So it may cause many diagnostic problems. The patient's clinical history and thorough physical examination are important for the correct diagnosis. It is crucial to have an understanding of the embryology, anatomy, presentation, and relevant investigations for these anomalies.
Keywords: *Abdominal Pain, Patent Urachus.*

Introduction

The urachus or median umbilical ligament is an epithelial tubular structure located in the midline that spreads from the anterosuperior part of the bladder to the umbilicus, connecting the apex of the urinary bladder with the allantois in the fetus, and is involved in forming the umbilical structures. It is the embryological remnant of the cloaca and the allantois. The lumen of the urachus usually becomes obliterated during embryonic development. Descent of the bladder toward the pelvis stretches the urachus, eventually leading to obliteration of its lumen. The median umbilical ligament is the resultant fibrous cord that runs from the umbilicus to the dome of the bladder. Occasionally, this obliterative process is incomplete, leading to a persistent urachal remnant (UR)[1]. UR diseases are rare and typically present in early childhood with unspecific symptoms such as abdominal pain or

urinary problems. Urachal anomalies can be classified into congenital and acquired anomalies.

It is of four types

1. Persistent urachus, which communicates the bladder with the umbilicus;
2. Urachal cyst (54%), a part of the urachal canal without any patent connection with the bladder or the umbilicus;
3. Vesicourachal diverticulum, a structure that opens within the bladder;
4. Urachal sinus (30%), which is a form of a cyst communicating with the umbilicus.

Acquired anomalies are infections and malignant degeneration. Remnants found in neonates <6 months old usually resolve spontaneously without the need for surgery[5].

Case Report

A 40 year old woman presented to OP with complaints of abdominal pain in the umbilical region for 2 weeks with foul smelling purulent discharge from the umbilicus for 1week. There were no urinary symptoms, and she was afebrile. Physical examination revealed periumbilical tenderness and minimal guarding. Ultrasound scan revealed umbilical abscess. On exploration abscess was drained and a striated structure was seen between the bladder and the umbilicus. It is found to be the patent urachal structure connecting the two. The urachus is resected and sent for pathological analysis. Postoperatively the patient condition improved and there were no urinary complaints. The pathological report revealed the patent urachus. With the advice to review regularly, the patient was discharged.

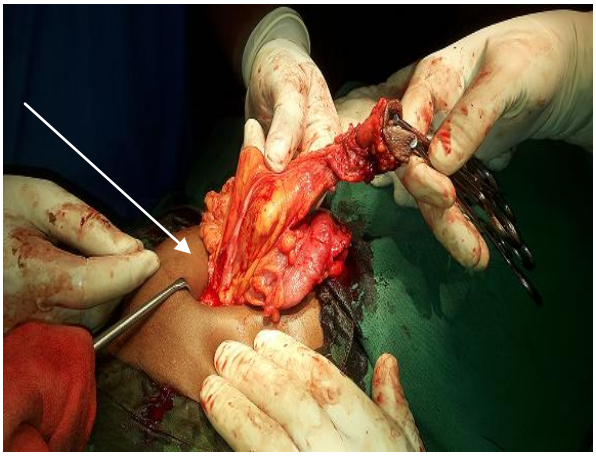

Fig 1.1 This shows the umbilicus being dissected and the patent urachus as a tube like structure extending from the bladder to the umbilicus (arrow pointed)

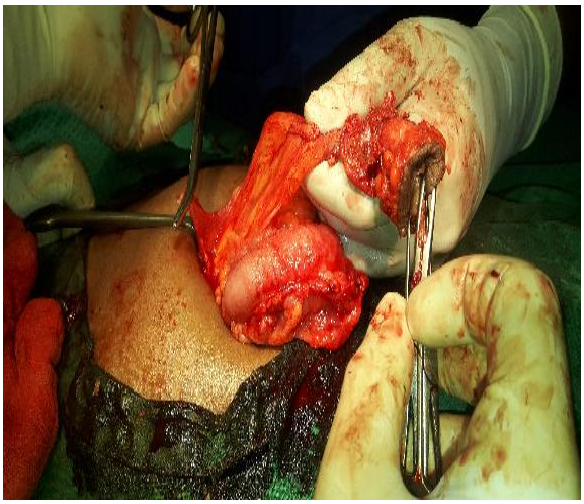

Fig 1.2. shows after resection, the remanant of the patent urachus being attached to the urinary bladder.

Discussion

The urachus is a fibrous remnant of the cloaca and the allantois, which in adults, connects the dome (anterosuperior part) of the bladder with the anterior abdominal wall (umbilicus). The allantois is a fingerlike projection from the yolk sac, which is contiguous with the ventral cloaca at one end and the umbilicus at the other. The cloaca, in the fetal life, is the cephalic extension of the urogenital sinus (a precursor of the fetal bladder) and the allantois. The ventral portion of the cloaca develops into the bladder after cloacal division by the urogenital septum. Between the 4th and the 5th months of gestational age, the bladder drops

toward the pelvis, and the urachus prolongs and narrows until it turns into an epithelialized fibromuscular cord. It lies in the space of Retzius, extending between behind the transversalis fascia and anterior to the parietal peritoneum, and is bordered laterally by the obliterated umbilical arteries (medial umbilical ligaments) [2]. The size of the urachus can range between 3 cm and 10 cm in length and 8 mm and 10 mm in diameter. After birth it obliterates, forming the median umbilical ligament. However, a vestigial small lumen lined by a transitional epithelium is seen commonly in the fully developed infant[3]. Occasionally, the urachus may merge with one or both of the obliterated umbilical arteries, and there may be a slight deviation to the right or left of the mid line[4].

Those found in older patients require management and needs resection, as chronic exposure to urinary stasis leads to infection and inflammation, and has an increased risk of neoplastic differentiation. Clinical symptoms of an urachal infection are fever, abdominal pain, urinary problems and sometimes, a suprapubic palpable mass. Spontaneous resolution without the need for further intervention has been reported[6].

It is unclear whether all URs or a subset of symptomatic URs should be resected. With an increase in incidental diagnosis, non-operative management has become more common. Ueno et al [3] reviewed the ultrasound reports of 3400 patients and found that 56 children had a UR. Of these, 44 patients were followed up without surgical resection. In 9 cases, URs disappeared during the follow-up period. Only 1 patient had recurrent symptoms, which were treated conservatively.

Galati et al[7] retrospectively reviewed 23 patients treated for a UR, and found that overall 50% and in children less than 6 months of age 80% of URs resolved non-operatively. Lipskar et al [8] reviewed their experience in managing 15 children with URs. 8 patients underwent surgical excision, while 7 were managed non-operatively for 26 months.

There is not enough information in describing postoperative complications after UR resection. McCollum et al[2] reported on excision of 26 URs with 1 wound infection and 1 bladder leak. Cilento et al[9] reported 45 UR excisions with three postoperative wound infections.

Urachal anomalies are twice as common in men as those in women[4], and are rarely observed in adulthood. Modes of presentation differ from those seen in children. Urachal cancer (51%) and urachal cyst (35%) are the most frequent modalities diagnosed in adults [5]. Some patients with URs are asymptomatic, but still carry a high risk for infection or cancer.

First, urachal anomalies are rarely observed clinically, with only eight of 40,000 cases being admitted to a surgical department[10]. Second, the urachus is located in a clinically silent area, in the space of Retzius. As a consequence, possible symptoms and clinical signs of inflammation as well as of tumors are, in most cases, nonspecific or delayed, or even absent.

Typical clinical manifestations of patent urachal pathologies are umbilical discharge, abdominal pain and tenderness, erythema, or a mass within the umbilicus. The differential diagnosis should include, mainly acute appendicitis, cystitis, inflammatory bowel disease, strangulated umbilical hernia, hematoma, pelvic or intra-abdominal abscess, and Meckel's diverticulum[5]

The diagnostic tools include USG, contrast enhanced CT abdomen or sometimes sinogram. Additional studies, including voiding cystourethrogram or cystoscopy, play very little roles in an otherwise asymptomatic patient. Treatment of symptomatic URs remains surgical. For the uncomplicated patent urachus, usually a one-stage procedure will suffice[2].

When urachal cancer cannot be excluded, cystoscopy with biopsy and urine cytology should not be omitted. Cytology is positive in 38% of patients with urachal carcinoma. If urachal pathology appears with signs of infection, a two-stage treatment is recommended: initially, administration of antibiotics and resolution of

inflammation, associated with the draining of the cyst or purulent collection, followed by surgical removal. In benign urachal anomalies, complete excision, with or without the cuff of the bladder, is sufficient. It is not necessary to remove the umbilicus. The surgical treatment prevents the possibility of a malignant degeneration. In case of urachal cancer, partial or radical cystectomy should be considered. Partial cystectomy with en bloc resection of the urachus with cancer within the bladder dome provides similar oncologic outcomes to radical cystectomy. Reports on laparoscopic partial cystectomy with urachus removal have been published[5].

Patent urachus and other congenital urachal anomalies in adulthood are rare. Often it present as acute abdominal pain which may be inconspicuous. So it may cause many diagnostic problems. The differential diagnosis should include mainly acute appendicitis, cystitis, inflammatory bowel disease, strangulated umbilical hernia, hematoma, pelvic or intra-abdominal abscess, and Meckel's diverticulum. The patient's clinical history and thorough physical examination are important for the correct diagnosis. It is crucial to have an understanding of the embryology, anatomy, presentation, and relevant investigations for these anomalies.

References

1. Maurode Queiroz Garcia et al., Patent Urachus Presenting as Acute Abdomen. Journal of Medical ultrasound, Volume 23, Issue 4, December 2015, Pages 189-192
2. M.O. McCollum, A.E. Macneily, G.K. Blair, Surgical implications of urachal remnants: presentation and management. J Pediatr Surg, Volume 38, 2003, pp. 798–803
3. T. Ueno, H. Hashimoto, H. Yokoyama, et al., Urachal anomalies: ultrasonography and management. J Pediatr Surg, Volume 38, 2003, pp. 1203–1207
4. J.S. Yu, K.W. Kim, H.J. Lee, et al., Urachal remnant diseases: spectrum of CT and US findings Radiographics, Volume 21, 2001, pp. 451-461
5. N. Muśko, J. Dobruch, S. Piotrowicz, et al., Infected urachal cyst in a young adult Cent Eur J Urol, Volume 67, 2014, pp. 199-201
6. J.A. Naiditch, J. Radhakrishnan, A.C. Chin, Current diagnosis and management of urachal remnants. J Pediatr Surg, Volume 48, 2013, pp. 2148-2152
7. V. Galati, B. Donovan, F. Ramji, et al., Management of urachal remnants in early childhood. J Urol, Volume 180, Issue 4 Suppl., 2008, pp. 1824-1826 [discussion 1827]
8. A.M. Lipskar, R.D. Glick, N.G. Rosen, et al. Nonoperative management of symptomatic urachal anomalies. Pediatr Surg, Volume 45, 2010, pp. 1016-1019
9. B.G. Cilento Jr., S.B. Bauer, A.B. Retik, et al. Urachal anomalies: defining the best diagnostic modality. Urology, Volume 52, 1998, pp. 120-122.
10. F. Tazi, M. Ahsaini, A. Khalouk, et al., Abscess of urachal remnants presenting with acute abdomen: a case series. J Med Case Rep, Volume 6, 2012, p. 226
11. D.M. Hernandez, P.P. Matos, J.C. Hernandez, et al., Persistence of an infected urachus presenting as acute abdominal pain. Case report. Arch Esp Urol, Volume 62, 2009, pp. 589-592.