



Wilson's Disease: Absence of Kayser-Fleischer Ring in a full blown neurological Wilson's disease

Authors

**Dr Rahul Kumar¹, Dr Seema Meena², Dr Umashankar U S³, Dr Rajesh Manocha⁴
Dr Bhandari Gurbir Singh⁵, Dr Harshit Khosla⁶, Dr Sahil Arora⁷**

^{1,5}Senior Resident, Department of General Medicine, VMMC and SJH

²Senior Resident, Rajendra Prasad Centre for Ophthalmic Sciences, AIIMS, New Delhi

^{3,6,7}PG Resident, Department of General Medicine, VMMC and SJH

⁴Professor and Consultant, Department of General Medicine, VMMC and SJH

Corresponding Author

Dr Rahul Kumar

Senior Resident, Department of Medicine, VMMC & Safdarjung Hospital, New Delhi-110029

Postal address- Ward 11, H- Block, Safdarjung Hospital, New Delhi-110029

Email: dr.rahulvmmc@gmail.com

ABSTRACT

Wilson's disease (WD) is an autosomal recessive disorder caused by mutation in ATP7B gene, in which clinical manifestations are caused by copper toxicity and primarily involve the liver and brain. An impairment in biliary excretion process leads to copper accumulation in the liver, which progressively damages the liver, leading to cirrhosis. Since effective treatment is available for this disease, early and correct diagnosis is very important. This case report describes a 28 year old male patient of Wilson's disease with predominant neurological manifestations due to widespread involvement of basal ganglia and cerebellum in absence of a Kayser-Fleischer Ring (KF Ring).

Key Words: *Wilson's disease, ATP7B gene, Neurological manifestation, Kayser-Fleischer Ring.*

INTRODUCTION

Wilson's disease or hepatolenticular degeneration is an autosomal recessive hereditary disease, that localizes to chromosome 13 characterized by a deficiency of ceruloplasmin, the serum transport protein for copper. Mutation of the ATP7B gene is closely linked to the impairment of copper excretion, leading to abnormal deposition of copper in the target organs ⁽¹⁾. The most pronounced involvement is in the liver, brain with typical involvement of the lenticular nucleus. The

clinical manifestation of WD are highly variable and patients usually present hepatic, neurological and/or psychiatric disturbances. The mean age of onset of neurological features of the disease is usually in the second to third decade of life. KF Ring no longer considered pathognomonic of Wilson's disease unless accompanied by neurological manifestation, as KF Ring may also be observed in patients with chronic cholestatic disorders. The gold standard for diagnosis is liver biopsy with quantitative copper assays. The

mainstay of therapy is lifelong use of chelating agents (trientine, penicillamine).

CASE REPORT

A 28 year old male non diabetic, non hypertensive and occasional alcoholic recently diagnosed to have chronic liver disease presented with complaints of altered sensorium, slurred speech, incoordination and difficulty in walking since past 1month. There was no history haematemesis or malena. The patient had a past history jaundice 2 year back that persisted for 1 month. He is the second child of non consanguineous marriage. Birth history was unremarkable and attained normal development milestones with no chronic medical conditions and family history unremarkable.

On examination there was slow mentation, slurred speech, ataxic gait, cog-wheel rigidity, exaggerated deep tendon reflexes of both upper and lower limbs, flexor planter response and cerebellar signs (finger nose test, pendular knee jerk, dysdiadokokinesia) were present, ascitis was absent, there was no hepatomegaly with no peripheral signs of liver failure. Respiratory and CVS examination were unremarkable. Urine output was maintained. Ophthalmic examination showed icteric sclera, decreased visual acuity and restricted field of vision, normal pupillary reaction to light and normal fundus. K-F ring was not seen on slit lamp examination

On evaluation Hb was 9.6 gm/dl, S.Bilirubin 5.4 mg/dl (3.2 mg/dl was indirect), SGOT/SGPT 965/40 IU, ALP- 234IU, INR - 1.3, S.Albumin of 3.5 gm/dl, B.Urea/ S.Creatine (34/1.0). Markers for Hepatitis B, C were negative.USG abdomen revealed features suggestive of Cirrhosis with portal hypertension.

Keeping the above clinical scenario in view, a probable diagnosis of Wilson's disease was kept. On further investigations the serum ceruloplasmin level was 15mg/dl (18-35mg/dl) and 24 hour urinary copper was 375 mcg (20-50mcg) .MRI brains revealed T2 hyperintensities in bilateral basal ganglia and dentate nucleus of cerebellum as

enclosed. Patient did not give the permission for liver biopsy. Patient was subsequently started on zinc therapy.

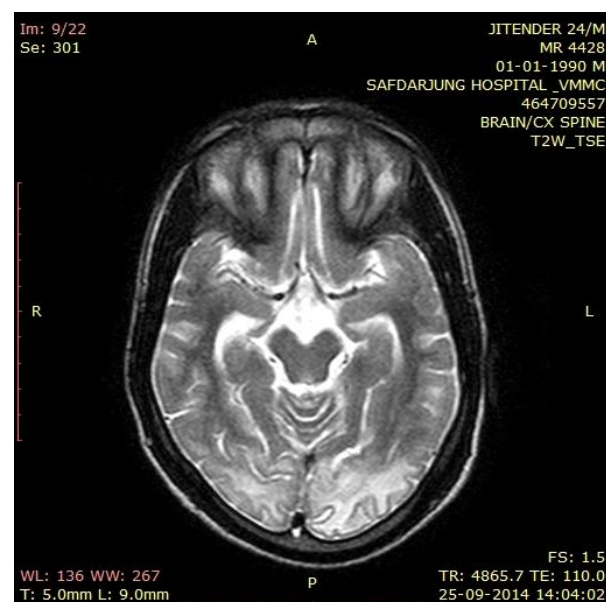
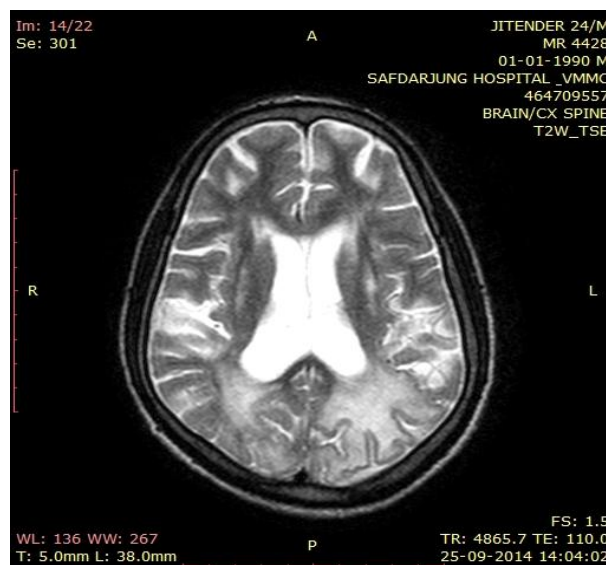


Fig.1,2- MRI Brain showing T2 weighted hyperintensity in bilateral basal ganglia and cerebellum.

DISCUSSION

WD is a rare autosomal recessive disorder resulting in copper overload, caused by mutation in the ATPB7 gene, which encodes a membrane bound copper transporting ATPase. Impairment in biliary excretion leads to the accumulation of copper, initially in the liver, and then in other tissues with domestic frequency of WD is approximately 1 case in 94,000 individuals in

population older than 15 years of age^(2, 3). Most patients present in their mid to late teenage years, although the age of presentation is quite broad and extends into the fifth decade of life.

There is no single specific test for diagnosis of WD. In a nation-wide survey of WD, low serum ceruloplasmin (<20mg/dl), high 24 hr urine copper level(>100gm), high hepatic copper content (>250ug/g of dry liver), and Kayser-Fleischer rings were found in 96%, 86%, 88% and 73% cases respectively⁽⁴⁾. A combination of any 2 of the above 4 laboratory findings forms a strong support for the diagnosis of WD.

The clinical hallmark of Wilson's disease is the Kayser-Fleischer ring, which is present in 95% of patients with neurologic symptoms and somewhat over half of those without neurologic symptoms⁽⁵⁾. Thus, the absence of rings does not exclude Wilson's disease. KF Ring is formed by deposition of copper in the descemet membrane in the limbus of the cornea; colour may range from greenish gold to brown. KF Ring may be visible by naked eye or ophthalmoscope set at +40, but slit-lamp examination is confirmatory. The neurological features of WD are primarily due to the deposition of copper in the lenticular nuclei, although areas like the brainstem and cerebellum can be affected. The clinical presentations of WD are liver and neuropsychiatric problems. Chronic active hepatitis, culminating in cirrhosis is the most common hepatic presentation, but some patients present with fulminant liver failure. Typical neurological signs include tremor, rigidity, drooling of saliva, speech changes, incoordination, and difficulty with fine motor tasks and gait difficulties. Psychiatric manifestations include compulsive behavior, aggression, depression, impulsive behavior and phobias⁽⁶⁾. Cerebral atrophy with ventricular dilation especially of the frontal horns and cerebellar atrophy are also frequently observed in WD. On MRI, they are hypointense on T1-weighted images and hyperintense on T2-weighted sequences. The high signal intensity on T2 weighted images is believed to be due to

edema, gliosis necrosis and cystic degeneration⁽⁷⁾. The description of the '*face of the giant panda*' sign by Hitoshi et al⁽⁸⁾ consisted of high intensity in the tegmentum expect for red nucleus, preservation of signal intensity of the lateral portion of the pars reticulate of the substantia nigra and hypointensity of the superior colliculus. The disease is treated with lifelong use of chelating agents such as D-penicillamine or trientine hydrochloride, drugs that help removing copper from tissues. Symptoms, particularly neurological, may worsen with initiation of chelation therapy, for those patient Zinc acetate should be used. Patient must avoid alcohol consumption and potential hepatotoxic drug therapy. Surgical decompression or transjugular intrahepatic shunting (TIPS) is reserved for recurrent or uncontrolled variceal bleeding unresponsive to medical therapy. Orthotopic liver transplantation is curative in Wilson's disease.

REFERENCES

1. Dong, Q.Y., Wu, Z.Y. Advance in the pathogenesis and treatment of Wilson disease. *Transl. Neurodegener.* 2012, doi:10.1186/2047-9158-1-23.
2. Davies K. Cloning the menkes disease gene. *Nature.* 1993;361:98.
3. Fatemi N, Sarkar B. Structural and functional insights of wilson disease copper-transporting ATPase. *J Bioenerg Biomembr.* 2002;34:339-349.
4. Seo JK, Kim YS, Hahn CJ, Baik SK. A nationwide survey for prevalence and clinical characteristics of Wilson disease in Korea. *Korean J Hepatol.* 2004; 10 (Suppl):5-15.
5. Steindl P, Ferenci P, Dienes HP, Grimm G, Pabinger I, Madl CH, et al. Wilson's disease in patients presenting with liver disease: a diagnostic challenge. *Gastroenterology* 1997;113:212-218.
6. Rudolph JA, Balisteri WF. *Metabolic Diseases of Liver.* In: Nelson's Textbook of Pediatrics. Eds. Behrman RE, Kliegman

RM, Jenson HB. 17th Ed Philadelphia, W.B. Saunders Company, 1996.pp.1319-22.

7. van Wassenae-van Hall HN, van den Heuvel AG, Algra A, Hoogenraad TU, Mali WPTM. Wilson Disease: Findings at MR imaging and CT of the Brain with clinical correlation. Radiology 1996; 198: 531-536.
8. Hitoshi S, Iwata M, Yoshikawa K. Mid-brain pathology of Wilson Disease: MRI analysis of three cases. J Neurol Neurosurg Psychiatry 1991;54(7):624-26.