



Paratesticular Fibrous Pseudotumor -A Rare Entity

Authors

Rajiv Srivastava¹, Rajeev Singh¹, Nikita Mahar¹, Bennot¹, Ashok¹

¹Department of Surgery, Govt. Medical College Haldwani

Abstract

Paratesticular tumors are rare intrascrotal masses that grow mainly in structures containing connective tissue around the testis, epididymis, or spermatic cord. We report here on a case of a 29 year-old man with a mass in the hemiscrotum arised post traumatic that was found to be a paratesticular fibrous pseudotumor in the orchiectomy specimen's Histopathologic examination. From this case report and literature review, a diagnostic and therapeutic strategy is demonstrated for the management of this uncommon lesion.

Keywords-*paratesticular tumor, fibrous pseudotumor, testis, scortum, epididymis.*

Introduction

Paratesticular fibrous pseudotumor is a rare benign lesion that arises from testicular tunics and, less commonly, grows into the epididymis and spermatic cord. Also known as chronic proliferative periorchitis, inflammatory pseudotumor, and reactive periorchitis, paratesticular fibrous pseudotumors (PFPs) are rare pathologies with quite wide and variable topographic-morphological features, and their etiology is not fully understood. The epididymis is involved in less than 10% of the cases. This lesion is a consequence of a reactive proliferation of inflammatory and fibrous tissue. The initial stimulus of this reactive process may be a prior infection or trauma. The diagnosis is made on postoperative histologic examination. On clinical examination its very difficult to differentiate it from testicular tumors, so called pseudotumor.

Case Report

A 29 year old gentleman came to surgery OPD with complaint of swelling over Rt. hemiscortum,

he gave history of swelling since last 5 months that gradually increased to the present size, swelling was not associated with any other symptoms except some heaviness on the effected side. History of trauma to the scortum 1 year back was given. The physical examination revealed a firm, nontender, and mobile mass in the right hemiscrotum. This mass was fixed to the upper pole of the testis and gave the impression of testicular tumor. Abdominal and inguinal examination revealed no mass or palpable lymph node. The left hemiscrotum was normal.

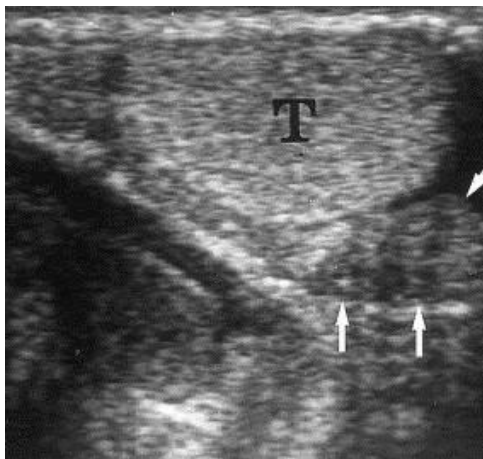
Serum markers for germ cell tumors (α -fetoprotein, β -human chorionic gonadotrophin, and lactic dehydrogenase) were within normal range.

Ultrasound examination showed a evidence of lobulated hetroechogenic lesion measuring 3*2.5cm seen involving the right spermatic cord close to the superior pole of the testis. The lesion is seen separate from the epididymis and the finding were suspicious of neoplastic pathology Because we suspected a neoplastic paratesticular

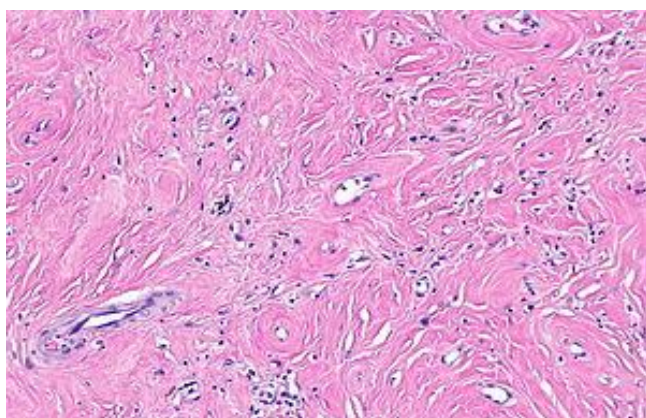
tumor, we decided to perform a radical high orchiectomy.

On the cut section a well circumscribed greyish white paratesticular mass was noted. Periphery of mass showed thickened capsule and cut surface was solid grayish white and solid variegated in appearance.

Histopathology revealed –paratesticular mass showing a circumscribed lesion containing paucicellular dense hyalinized collagen bundles with spindle cells and variable amount of chronic inflammatory cell infiltrate at the periphery along with proliferating blood vessels. Section from spermatic cord, epididymis and testis show unremarkable morphology.



Usg of Rt testis showing paratesticular tumor arising from spermatic cord.



paratesticular mass showing a circumscribed lesion containing paucicellular dense hyalinized collagen bundles with spindle cells and variable amount of chronic inflammatory cell infiltrate at the periphery along with proliferating blood vessels

Discussion

Paratesticular fibrous pseudotumors are uncommon reactive benign lesions of testicular tunics. This term is generally accepted, although multiple names, such as inflammatory pseudotumor, proliferative funiculitis, chronic proliferative periorchitis, fibrous mesothelioma, and reactive periorchitis, are also assigned to this tumor.^{1,2} This case was first reported by Balloch in 1904.³ Most reported cases have involved the tunica vaginalis; rarely is it associated with the tunica albuginea, epididymis, or spermatic cord.⁴ This tumor is one of the rarest paratesticular tumors. The pathogenesis of the fibrous pseudotumors of the testicular tunics is poorly understood and highly controversial. Most authors favor reactive nature at least in certain cases including a history of trauma, infection, or inflammatory hydrocele.⁷

The peak incidence of fibrous pseudotumors is in the third decade but can occur at any age. Tumor size at presentation can range from 1 to 10 cm.² Most patients report a history of hydrocele, trauma, or infection. In most reports, hydrocele represents the most frequently associated finding with the lesion and has been found in nearly 50% of fibrous pseudotumor cases.

Our patient reports the typical clinical finding, as most patients present with a painless scrotal mass. This mass can be quite large and mimics neoplasms. This lesion might be separated from the testes.³ This lesion presents grossly as multinodular, well delimited, oval, and mobile structures often with diffuse fibrosis of the tunics. Under microscopic examination, such nodes demonstrated hyalinized tissue and fibroblasts in a richly vascularized stroma, with collagen bundles and calcification foci.⁵⁻⁶ Sonographic evaluation may show either hypoechoic or hyperechoic solid mass involving the paratesticular structures⁷⁻⁸. As in our case, most patients with fibrous pseudotumors undergo surgery because their mass mimics a malignancy that results in treatment by radical orchiectomy. However, scrotal exploration, frozen biopsy,

and local excision of the tumor is the treatment of choice and orchiectomy might be unnecessary.³

Although these masses may be difficult to distinguish from malignancy, they behave in a benign fashion once excised.

Conclusions

Benign tumors of scrotal structures are not common. Fibrous pseudotumors are among the most rarely seen benign tumors, and two-thirds involve the testicular tunica with other scrotal structures rarely involved. Surgical exploration is usually required to rule out malignant processes.

Points to remember-

Paratesticular fibrous pseudotumor are benign lesions of testicular tunics. Diagnosis is made on histopathological section sent after resection of the tumor or orchidectomy specimen.

Pseudotumor mainly involve tunica vaginalis and rare occurrence is from albugenia, epididymis or spermatic cord.

Peak age of incidence is third decade but can occur in any age. Size ranges from 1cm to 10cm

As it mimics neoplastic lesions so in most of the cases orchiectomy is done but if proper preoperative evaluation is done with high suspicion of pseudotumor. orchiectomy can be avoided

References

1. Sadowski EA, Salomon CG, Wojcik EM, Albala D. Fibroma of the testicular tunics: an unusual extratesticular intrascrotal mass. *J Ultrasound Med.* 2001;20:1245–1248.
2. Parker PM, Pugliese JM, Allen RC., Jr Benign fibrous pseudotumor of tunica vaginalis testis. *Urology.* 2006;68:427.
3. Tobias-Machado M, Corr\ ea Lopes Neto, Heloisa Simardi L, et al. Fibrous pseudotumor of tunica vaginalis and epididymis. *Urology.* 2000;56:670–672.
4. Göğüs O, Bulay O, Yurdakul T, Bedük Y. A rare scrotal mass: fibrous pseudotumor of epididymis. *Urol Int.* 1990;45:63–64.
5. Mostofi FK, Price EB. Tumors of the male Genital System. *Atlas of Tumor Pathology, 2nd series, fascicle 8.* Washington DC: Armed Force Institute of Pathology; 1973: 151-4.
6. Oliva F, Young RH. Paratesticular tumor-like lesions. *Semin Diag Pathol* 2000; 17: 358.
7. Grebenc JL, Gorman JD, Sumida FK. Fibrous pseudotumor fo tunica vaginalis testis: Imagins appearance. *Abdom Imaging* 1995; 20: 379-80
8. Germaine P, Simerman LP. Fibrous Pseudotumor of the Scrotum. *J Ultrasound Med* 2007; 26: 133-8.