



Comparative Study of Solitary Nodules of Thyroid in Adults in Tertiary Care Teaching Hospital

Authors

T. Henry Prabakaran¹, P. Rajeswari², Arbind Kumar C³

¹Asst. Professor of Surgery, IRT-Perundurai Medical College & Hospital, Perundurai, Tamilnadu, India

²Asst. Professor of Pathology, IRT-Perundurai Medical College & Hospital, Perundurai, Tamilnadu, India

³Asst. Professor of Pharmacology, IRT-Perundurai Medical College & Hospital, Perundurai, Tamilnadu, India

Corresponding Author

Dr P. Rajeswari

Asst. Professor of Pathology, IRT-Perundurai Medical College & Hospital, Perundurai, Tamilnadu, India

Abstract

Introduction: In recent times, prevalence of Thyroid Solitary nodule of thyroid are increasing, common presentation of OP and IP patients f surgical ward. Solitary nodule of thyroid can exhibit various pathology like benign cyst, colloid nodules, adenoma, thyroiditis and malignant tumour.

Aim and Objective: The aim and objective of this study to find out incidence and prevalence of solitary nodule of thyroid in adult tertiary care teaching hospital. and to study of, various presentation of swelling, huge enlargement produce tracheal compression, pressure symptoms on vital structure in neck, and to study the correlative findings of pre FNAC and post-operative histopathology examination and study the intraoperative and post-operative complications.

Material s& Methods: In this study of total of 100 cases were taken, who satisfied the inclusion/ exclusion criteria; of the 100 patients who underwent our study. There are 90 females 10 males showing female preponderance (sex ratio m:f 1:10), Patient ranging from 19 yrs to 65yrs.

After thorough clinical evaluation, Patients suspected to have thyroid lesions were subjected to FNAC & USG, Histopathology reports were correlated. Treatment planning was done as appropriate depending on clinical findings and investigation results. Patients underwent surgery, post operating complications were recorded. All patients were followed up for a period ranging 1 to 7 months.

Results and Conclusions: The data collected during study period shows Thyroid Nodules of 58% of 3rd to 4th decades (20 to 39 years). 40 to 49 years – which is 22%; FNAC was found to have sensitivity of 86% Specificity of 91%; Follicular adenoma and carcinoma cannot be differentiated by FNAC, confirmed by biopsy. 2 cases of Papillary Carcinoma was diagnosed and confirmed by biopsy. One suspected Papillary Carcinoma was found. This was confirmed in post-operative biopsy. In 3 suspected follicular neoplasm only one patient confirmed positive in biopsy. In USG findings 69 Solitary Nodules of Thyroid, 30 multiple dominant nodules, 1 simple cyst. For most of the Solitary nodules Rt or Lt- Hemithyroidectomy is performed.

Keywords: dominant Nodule, FNAC, clinical data, HPE.

Introduction

Thyroid swellings are common in Out-patients and in-patients. Solitary nodule of thyroid is the commonest presentation in surgical wards. It consists of various pathology like colloid nodules, Thyroiditis cysts, adenomas, carcinomas, dominant nodule, lymphoma etc.

These nodules present a unilateral thyroid enlargement with normal or hyper function. Size of the nodule may be small to large producing tracheal compression and various pressure symptoms on vital structures in neck^[1]

Clinical examination, Thyroid profile, Fine Needle Aspiration Cytology, HPE, Ultrasound Examination of neck, Indirect Laryngoscopy, X-rays of Chest and neck are the various methods for preoperative workups. Hemi thyroidectomy and total thyroidectomy are the surgeries done for solitary nodule thyroid.

Hemithyroidectomy and total thyroidectomy are the surgeries done for solitary nodule thyroid based on pre-operative FNAC reports whether benign or malignant.^[1] FNAC cannot differentiate follicular adenoma from follicular carcinoma and they are treated by total thyroidectomy

Solitary Thyroid Nodule

Causes of Thyroid Nodules

Benign; Multinodular goiter, Hashimoto's thyroiditis, Simple or hemorrhagic cysts, Follicular adenomas Subacute thyroiditis.

Malignant: Papillary carcinoma, Follicular carcinoma, Hürthle cell carcinoma, Medullary carcinoma, Anaplastic carcinoma, Primary thyroid lymphoma^[21]

Metastatic malignant lesion: Most patients with thyroid nodules are asymptomatic, occasionally patients complain of dysphagia, dysphonia, pressure, pain, or symptoms of hyperthyroidism or hypothyroidism^[13]. Absence of symptoms does not rule out a malignant lesion. Thyroid US should not be performed as a screening test. All patients with a palpable thyroid nodule, however, should undergo US examination. US-guided FNA (US-FNA) is recommended for nodules ≥ 10 mm; US-

FNA is suggested for nodules < 10 mm only if clinical information or US features are suspicious. Preferably, the aspirates should be obtained from the peripheral areas and different parts of the nodule in a sequential manner to ensure representative sampling^(11,13). For larger nodules, the deep center of the mass should be avoided because it is more likely to contain degeneration and fluid^[14,19]

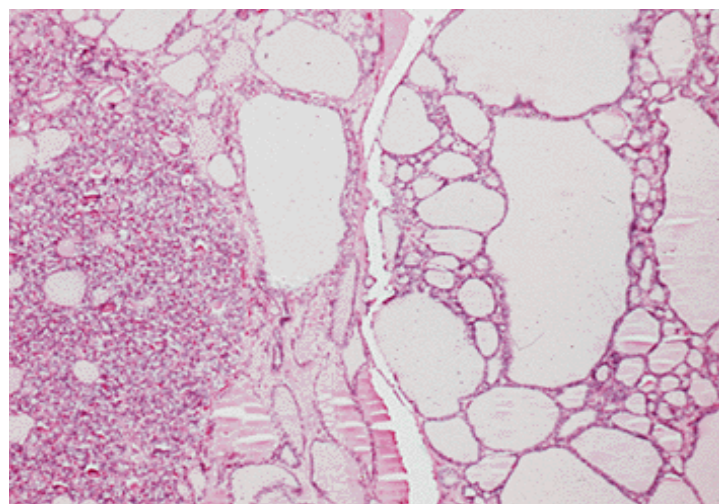


Fig.1 Multinodular goiter

Family History

A family history of thyroid cancer is a risk factor for the development of both medullary and non-medullary thyroid cancer.

Diagnostic Tests

Fine-Needle Aspiration Biopsy: This procedure has become the single most important test in the evaluation of patients with thyroid masses and can be performed with or without ultrasound guidance^[8]. Ultrasound guidance is recommended for nodules that are difficult to palpate^[4,19].

Laboratory Studies: Most patients with thyroid nodules are euthyroid. Determining the blood TSH level is helpful. If a patient with a nodule is found to be hyperthyroid, the risk of malignancy is approximately 1%. Serum Tg levels cannot differentiate benign from malignant thyroid nodules unless the levels are extremely high, in which case metastatic thyroid cancer should be suspected. Thyroglobulin levels are, however, useful in following patients who have undergone

total thyroidectomy for thyroid cancer and also for serial evaluation of patients undergoing non-operative management of thyroid nodules. Serum calcitonin levels are also done in MTC cases and also tested for RET oncogene mutations and have a 24-hour urine collection with measurement of levels of vanillylmandelic acid (VMA), metanephrine, and catecholamine to rule out a co-existing pheochromocytoma.

Imaging

Ultrasound as well CT and MRI are helpful for detecting nonpalpable thyroid nodules and for differentiating solid from cystic.

Management Thyroid Nodules

Malignant tumors are treated by thyroidectomy, "Simple thyroid cysts resolve with aspiration in approximately 75% of cases, although some require a second or third aspiration. If the cyst persists after three attempts at aspiration, unilateral thyroid lobectomy is recommended. Lobectomy is also recommended for cysts greater than 4 cm in diameter and for complex cysts with solid and cystic components, because the latter have a higher incidence of malignancy (15%). When FNA biopsy is used in complex nodules, the solid portion should be sampled. If a colloid nodule is diagnosed by FNA biopsy, patients should still be observed with serial ultrasound and Tg measurements. If the nodule enlarges, repeat FNA biopsy is often indicated. Thyroidectomy should be performed if a nodule enlarges on TSH suppression, causes compressive symptoms, or for cosmetic reasons.

Malignant Thyroid Disease: Thyroid cancer accounts for less than 1% of all malignancies (2% of women and 0.5% of men). Thyroid cancer is responsible for six deaths per 1 million persons annually. Most patients present with a palpable swelling in the neck, which initiates assessment through a combination of history, physical examination, and FNA biopsy.

Papillary Carcinoma: 80% of all thyroid malignancies in iodine-sufficient areas; predominant thyroid cancer in children and

individuals exposed to external radiation; 2:1 female:male ratio; Mean age at presentation is 30 to 40 years; Most patients are euthyroid and present with a slow-growing painless mass in the neck. Dysphagia, dyspnea, and dysphonia are usually associated with locally advanced invasive disease; Lymph node metastases are common, followed by bone, liver, lung and brain ^[22].

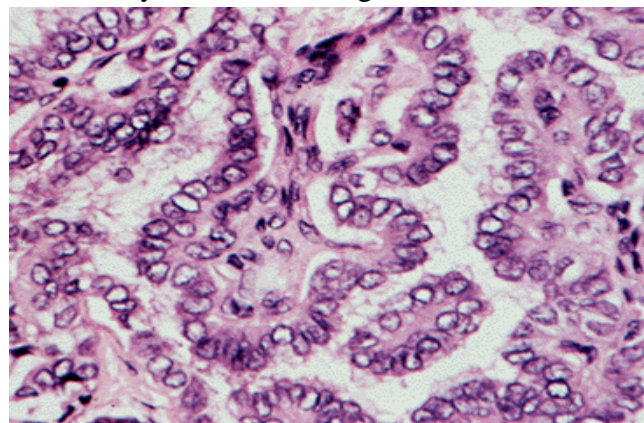


Fig 2. Papillary Carcinoma

Pathology

- On gross examination, PTCs are generally hard and whitish
- Macroscopic calcification, necrosis, or cystic change may be apparent
- Histologically papillary projections, a mixed pattern of papillary and follicular structures.
- Cells are cuboidal with pale, abundant cytoplasm, "grooving," crowded nuclei, and intranuclear cytoplasmic inclusions, leading to the designation of *Orphan Annie* nuclei.
- Psammoma bodies, which are microscopic, calcified deposits.
- Multifocality is observed in 85% cases.

Prognostic Indicators

AGES scoring system, which incorporates age, histologic grade, extrathyroidal invasion and metastases, and tumorsize to predict the risk of cancer. The MACIS scale incorporates distant metastases, age at presentation, completeness of original surgical resection, extrathyroidal invasion, and size of original lesion (in centimeters). AMES system classify differentiated

thyroid tumors into low- and high-risk groups using *age* (men <40 years, women <50 years), *metastases*, *extrathyroidal spread*, and *size of tumors* (5 cm).TNM system,

Surgical Treatment: Total or near-total thyroidectomy, lobectomy.

Follicular Carcinoma: 10% of thyroid cancers and occur more commonly in iodine-deficient areas; female:male ratio of 3:1 with mean age at presentation of 50 years.

present as solitary thyroid nodules, occasionally with a history of rapid size increase, and long-standing goiter^[5].

FNA biopsy is unable to distinguish benign follicular lesions from follicular carcinomas. Large follicular tumors (>4 cm) may be malignant^[20]

Pathology

Follicular carcinomas are usually solitary lesions, the majority of which are surrounded by a capsule^[14]. Histologically, follicles are present, but the lumen may be devoid of colloid. Architectural patterns depend on the degree of differentiation demonstrated by the tumor^[6]. Malignancy is defined by the presence of capsular and vascular invasion. Minimally-invasive, widely invasive tumors demonstrate evidence of large-vessel invasion and/or broad areas of tumor invasion through the capsule. literature support the findings that FTC with angioinvasion is more aggressive than FTC with only capsular invasion yet is less aggressive than widely invasive FTC. The authors conclude that FTC no longer should be classified as either minimally invasive or widely invasive; rather, they recommend classifying FTC as minimally invasive, moderately invasive, or widely invasive, because prognosis varies according to these groupings^[7,21]

Hürthle Cell Carcinoma

- 3% of all thyroid malignancies.
- Like follicular cancers, Hürthle cell cancers are characterized by vascular or capsular invasion.

- Tumors contain sheets of eosinophilic cells packed with mitochondria, which are derived from the oxyphilic cells of the thyroid gland

Postoperative Management

Thyroid Hormone & Thyroglobulin Measurement, Radioiodine Therapy, External Beam Radiotherapy and Chemotherapy

Medullary Carcinoma

- MTCs account for about 5% of thyroid malignancies and
- Arise from the parafollicular or C cells of the thyroid, which, in turn, are derived from the ultimobranchial bodies.
- C cells secrete calcitonin, a 32-amino-acid polypeptide
- 25% occur within the spectrum of several inherited syndromes such as familial medullary thyroid cancer, MEN2A, and MEN2B.
- secondary to germline mutations in the RET proto-oncogene

Patients with MTC often present with a neck mass that may be associated with palpable cervical lymphadenopathy (15 to 20%). Most patients present between 50 and 60 years of age, occasionally younger age. Diagnosed by history, physical examination, raised serum calcitonin or CEA levels, and FNA cytology of the thyroid mass. Approximately 25% of patients with MTC have familial disease.

Treatment: Total thyroidectomy is the treatment of choice for patients with MTC because of the high incidence of multicentricity and aggressive^[17]

Anaplastic Carcinoma

Anaplastic carcinoma accounts for approximately 1% of all thyroid malignancies. Women are affected in the seventh and eighth decades of life. Pathology On gross inspection, anaplastic tumors are firm and whitish in appearance. Microscopically, sheets of cells with marked heterogeneity are seen. Cells may be spindle-shaped, polygonal, or large, multinucleated cells.

Lymphoma

- Less than 1% of thyroid malignancies and most are of the non-Hodgkin's B-cell type.
- Patients usually present with symptoms similar to those of patients with anaplastic carcinoma, although the rapidly enlarging neck mass often is painless. Patients may present with acute respiratory distress
- The thyroid gland is a rare site of metastases

(Hashimoto's) Thyroiditis

- autoimmune process that is thought to be initiated by the activation of CD4+T (helper) lymphocytes with specificity for thyroid antigens^[3]
- Hypothyroidism results not only from the destruction of thyrocytes by cytotoxic T cells, but also from autoantibodies^{16,18}

Aims & Objectives of the Study

This study was mainly to analyse the clinically presenting solitary nodular thyroid swellings which commonly present in fluorosis prevalent and endemic thyroid region.

The study was conducted in the following disciplines:

1. The incidence and prevalence of the solitary nodule thyroid in and around semi-urban region, clinical symptoms and signs
2. To study the correlative findings in pre-op FNAC and postoperative biopsy reports,

Materials and Methods

Prospective, clinical, observational study designed in IRT-Perundurai Medical college, Erode, In this study of total of 100 cases were taken, who satisfied the inclusion/ exclusion criteria; of the 100 patients who underwent our study. There are 90 females 10 males showing female preponderance (sex ratio m:f 1;10) ,Patient ranging from 19 yrs to 65yrs.

After thorough clinical evaluation, Patients suspected to have thyroid lesions were subjected

to FNAC & USG, Histopathology reports were correlated.

Treatment planning was done as appropriate depending on clinical findings and investigation results. Patients underwent surgery, post operating complications were recorded. All patients were followed up for a period ranging 1 to 7 months.

Clinical data regarding thyroid nodule; Laboratory values and FNAC & USG and biopsy reports were entered & analysed.

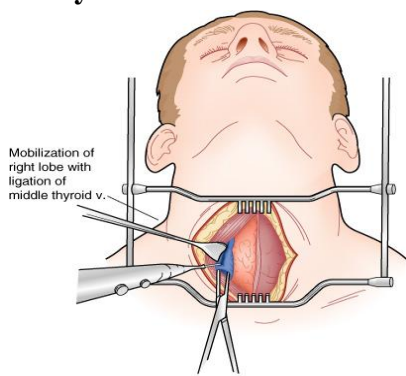
Methodology

Informed consent was obtained from patients. Relevant history and clinical details were recorded, after proper position and physical examination of thyroid was follow up, followed by laboratory investigation, thyroid scan and FNAC. All the relevant data and parameter was entered by using Microsoft excel on daily prospective basics and analysed by using simple biostatistics tools.

Investigation include: Serum TSH The tests for serum TSH (normal 0.5 to 5 U/mL) TSH assay has become the most sensitive and specific test for the diagnosis of hyper- and hypothyroidism, Total T₄ and Total T₃, Free T₄ and Free T₃, These radioimmunoassay-based tests are a sensitive and accurate measurement of biologically active thyroid hormone. Free T₄ Use of this test is confined to cases of early hyperthyroidism in which total T₄ levels may be normal but free T₄ levels are raised. Free T₃; TSH test is useful to evaluate pituitary TSH secretory function, Thyroid Antibodies Thyroid antibodies include antithyroglobulin (anti-Tg), antimicrosomal or antithyroid peroxidase (anti-TPO) Serum Thyroglobulin, Fine-Needle Aspiration Biopsy The slides are stained by Papanicolaou²¹ (Pap) or Wright's stains and examined under the microscope. After FNA biopsy, the majority of nodules can be categorized into the following groups: benign (65%), suspicious (20%), malignant (5%), and nondiagnostic (10%).

THYROID IMAGING: Radionuclide Imaging, Ultrasound, CT/MRI Scan

Thyroidectomy



Patient must be appropriately positioned with the neck extended. A transverse incision is made about two fingerbreadths above the clavicular heads¹⁵

The skin incision is carried through subcutaneous fat and the platysmal muscle.

The anterior jugular veins are identified and divided

Total thyroidectomy involves division of all thyroid tissue between the entrance of the recurrent laryngeal nerves bilaterally at the ligament of Berry, and it results in complete removal of all visible thyroid tissue^[9,21]

Near-total thyroidectomy involves complete dissection on one side while leaving a remnant of thyroid tissue laterally on the contralateral side, which incorporates the parathyroids.

Subtotal thyroidectomy leaves a rim of thyroid tissue bilaterally to ensure parathyroid viability and avoid entrance of the recurrent laryngeal nerves into the larynx

Indications for Interventional Procedures:

Procedure	Advantage	Disadvantage Or Complications	Indication
Fine-needle aspiration (FNA)	Accurate diagnosis of malignancy	Cannot confirm benign diagnosis Capsular hemorrhage	Tissue diagnosis of ultrasound-determined solid nodule Previous "nondiagnostic" result
Open biopsy	Direct visualization	Requires an operating room, possibly general anesthesia	Complex case in which FNA has failed to give a diagnosis
"Nodulectomy" (less than a lobectomy)	None	Difficult second operation to complete the lobectomy if a diagnosis of cancer is made	None
Lobectomy (with isthmectomy)	Lower rates of hypocalcemia and nerve damage	May require completion thyroidectomy if a diagnosis of cancer is made	Strong suspicion of benign disease Well-differentiated cancer <1 cm

Results & Discussion

A study is designed for the data collected during the study period and various epidemiological and other statistical details are analysed, results calculated and Graphs given at appropriate places to make easy understanding.

Age & Sex

Of the 100 patients who underwent our study, there are 10 males and 90 females showing female preponderance (sex ratio =M;F 1;10)

There were patients ranging from lowest age of 19 yrs to highest age of 65 years.-The following statistics are calculated Mean Age = 37.8 Years

Median Age = 35 Years

TABLE – 1: Age distribution

The above data shows that 3RD & 4TH decades(20-39 years) are the most common age group for thyroid nodules (58 %) closely followed by 5th decade (40-49 years) which is 22%.

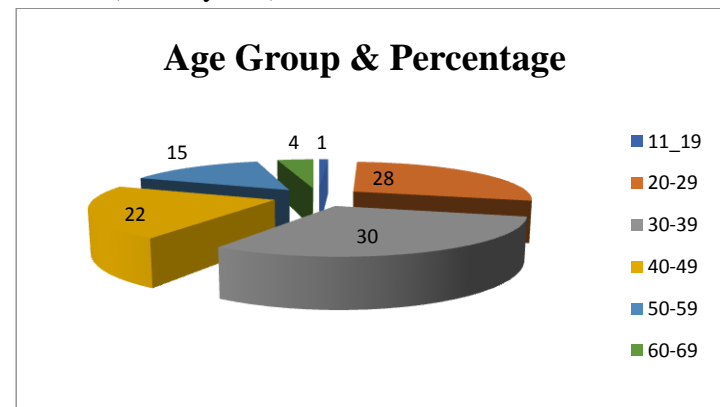


Table No 2 : Patients Complaints

Complaint	No Of Patients
Swelling	87
Pain	2
Swelling And Pain	6
Swelling , Pain , Dyspnoea	3
Swelling , Pain , Hoarseness Of Voice	1
Swelling And Hoarseness Of Voice	1

Solitary nodule presented clinically of varying sizes from 2 cm to 9 cm. Clinically diagnosed solitary nodular goiters found to have impalpable nodules diagnosed by USG and as intra out-patient finding.

Table No 3; Size of Nodules

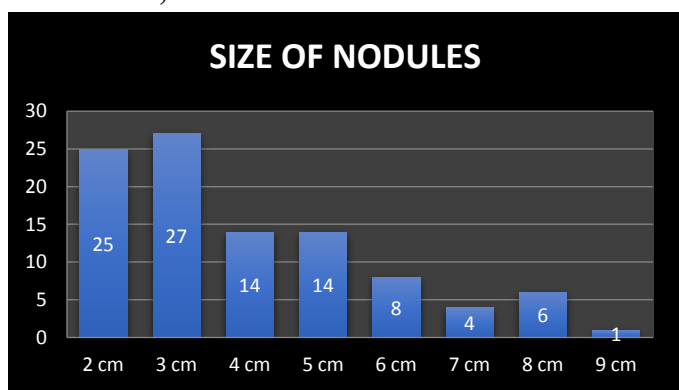


Table No 4 Male and female Ratio thyroid nodules

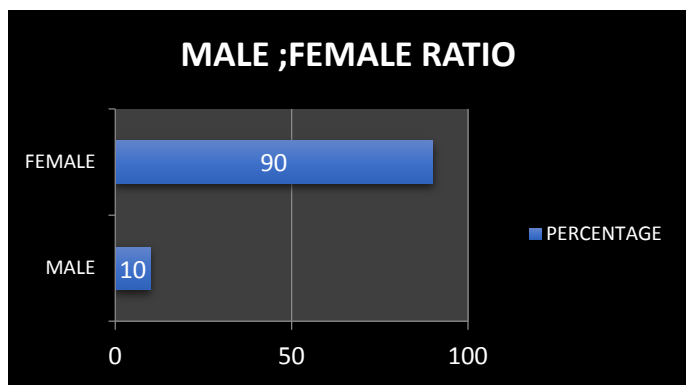
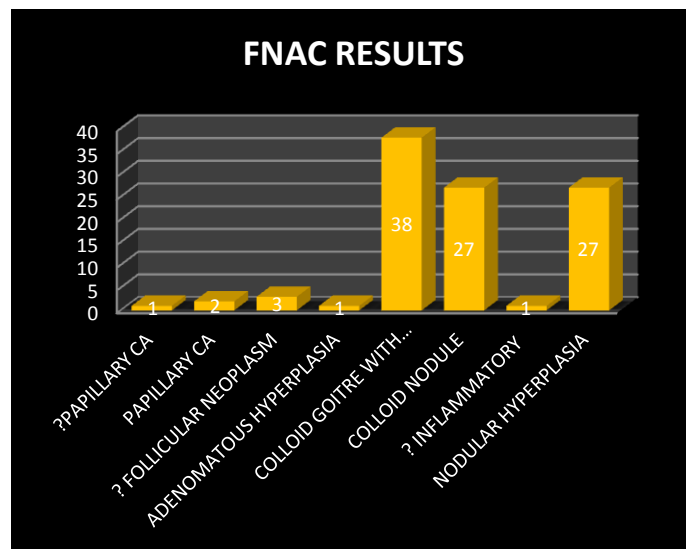


Table. No 5

FNAC was found to have a sensitivity of 86% and a specificity of 91%. Follicular adenomas and carcinoma cannot be differentiated .FNAC are repeated for inconclusive results.USG guided FNAC is not done. Two cases of papillary ca were diagnosed and confirmed by FNAC One suspected papillary ca is found confirmed in post-op biopsy.

In three suspected follicular neoplasms only one patient confirmed positive in biopsy.

FNAC Result



USG preoperatively done and clinically diagnosed solitary nodule thyroid patients found to have impalpable small nodes bilaterally .

Table No; 6:-Ultrascan Finding

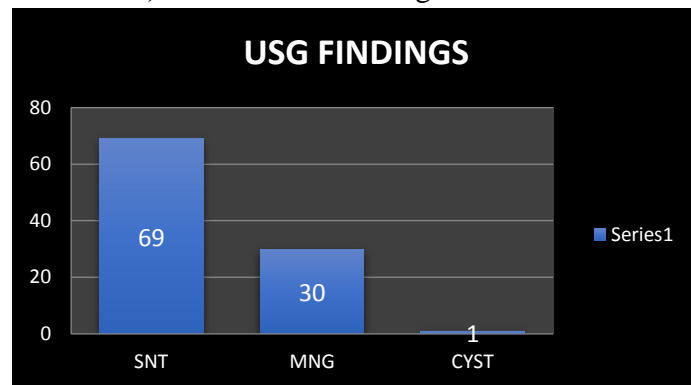


Table no 7: Anatomical location:

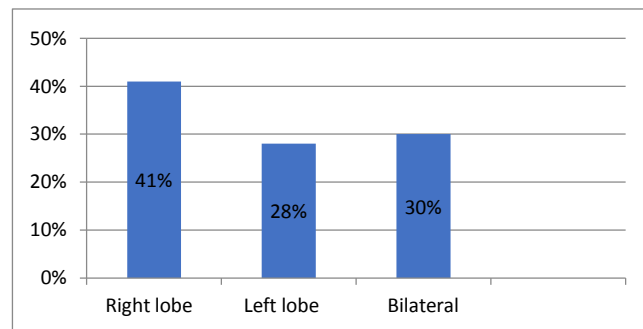
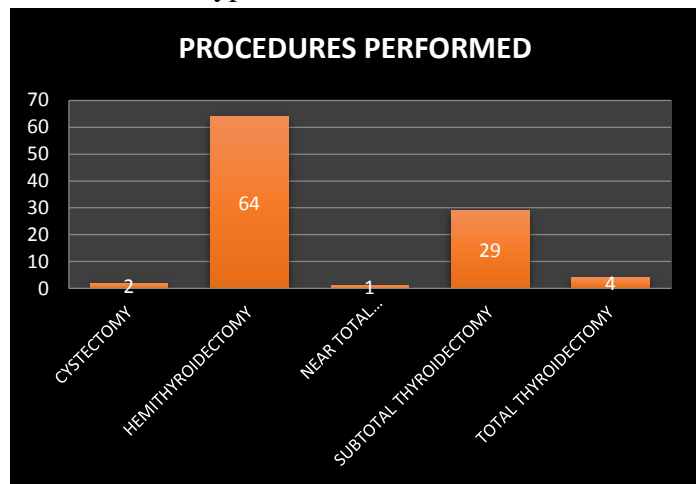


Table no 8 For most of the solitary nodules Rt or Lt – hemithyroidectomy is performed

Subtotal thyroidectomy is performed for multinodular goitres with dominant nodule. Near total and total thyroidectomy is done for malignant thyroid nodules and one suspected case of follicular neoplasm. Cystectomy is performed for simple cysts.

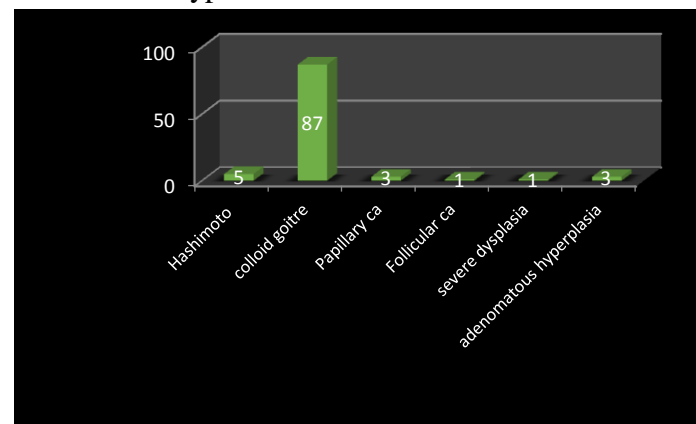
Table No 8 : Type of Procedures



Post op biopsy revealed malignant disease in 4 cases, Hashimoto's thyroiditis in 5 cases and benign conditions for the remaining cases.

An incidence of 4 % of malignancy is found in the study.

Table no 9: type of lesion



During the past 2 decades, the widespread use of ultrasonography for evaluation of thyroid disease has resulted in a dramatic increase in the prevalence of clinically in apparent thyroid nodules, estimated at 20% to 76% in the general population.

20% to 48% of patients with a single palpable thyroid nodule are found to have additional nodules when investigated by US.

As a consequence, we are now facing an epidemic of thyroid nodules; the prevalence is similar to that reported in autopsy data, 50%, in patients with no history of thyroid disease.

In our study 30 % of clinically palpable and diagnosed solitary nodular goitres found to have multiple small nodules in USG and intraoperative findings which correlates with the previous study²². Solitary nodule thyroid is the commonest presentation in thyroid disorders.

20-39 years are the commonest age group ; 30 % of clinically solitary nodules found to be dominant nodules in MNG on USG and intraop findings. Most of the disorders are benign. Malignancy accounts for 4 % of cases. Incidence is more common in females M:F 1:9.

Most cases are diagnosed preoperatively and confirmed by biopsy. Cystectomy, hemithyroidectomy, subtotal thyroidectomy, near total thyroidectomy, total thyroidectomy are the various surgeries done for clinically presenting solitary nodules in thyroid. Incidence of neuropraxia in recurrent laryngeal nerve which recovered completely is 29%. No bilateral nerve palsy; No wound infection seen.

References

1. Orlo H. Clark, MD, Thyroid Nodules and Thyroid Cancer: Surgical Aspects; West J Med. 1980 Jul; 133(1): 1-8.
2. Courtney M Townsend, Daniel R Beauchamp, Mark B Evers. Sabiston Textbook of Surgery. The Biological basis of modern surgical practice. 18th ed. Philadelphia: Saunders Elsevier; 2009. p. 917.
3. Doniach, D. et al. 6 Goitrous autoimmune thyroiditis (Hashimoto's disease) Clinics in Endocrinology and Metabolism , Volume 8 , Issue 1 , 63 – 80
4. Gharib H. Fine-needle aspiration biopsy of thyroid nodules: advantages, limitations, and effect. Mayo Clin Proc. 1994 Jan;69 (1): 44-9. Review. PubMed PMID: 8271850.

5. Richard T. et al factors That Predict Malignant Thyroid Lesions When Fine-Needle Aspiration Is “Suspicious for Follicular Neoplasm” Schlinkert,. Mayo Clinic Proceedings , Vol 72 , Issue 10 , 913 – 916
6. Schlumberger MJ Papillary and follicular thyroid carcinoma. N Engl J Med 1998; 338:297-306.
7. D'Avanzo A¹, Treseler P, Ituarte PH, Wong M, Streja L, Greenspan FS, Siperstein AE, Duh QY, Clark OH. Follicular thyroid carcinoma: Histology and prognosis. Cancer 2004;100:1123-1129.
8. Joe M. Chehade, MD¹, Alan B. Silverberg, MD¹, Joohee Kim, MD¹, Christopher Case, MD¹, Arshag D. Mooradian, MD¹ Role of repeated FNAC of thyroid nodules with benign cytologic features. *EndocrPract.* 2001 Jul-Aug; 7(4):237-43
9. Sakorafas GH, Peros G, Farley DR, Thyroid nodules: does the suspicion for malignancy really justify the increased thyroidectomy rates? *SurgOncol.* 2006 Jul; 15(1):43-55.
10. Burch HB, Burman KD, Reed HL, Buckner L, Raber T, Ownbey JL: FNAC of thyroid nodules. Determinants of insufficiency rate and malignancy yield at thyroidectomy. *ActaCytol.* 1996 Nov-Dec; 40(6):1176-83.
11. Bouvet M, Feldman JI, Gill GN, Dillmann WH, Nahum AM, Russack V, Robbins KT: Surgical management of the thyroid nodule: patient selection based on the results of FNAC 1992 Dec; 102(12 Pt 1):1353-6.
12. Jamal Akhavan-Moghadam, Mahdi Afaaghi, Ali Reza Maleki, and Amin Sabur :FNAC of thyroid nodules. *Arch Dis Child.* 2001 Oct; 85(4):313-7
13. Gharib H. :Thyroid fine-needle aspiration biopsy: progress, practice, and pitfalls. *EndocrPract.* 2003 Mar-Apr; 9(2):128-36.
14. Solomon D. Fine needle aspiration of the thyroid: an update. *Thyroid today.* 1993;16:1-9.
15. Nam-Goong IS, Kim HY, Gong G, Lee HK, Hong SJ, Kim WB, Shong YK: Ultrasonography-guided FNAC of thyroid incidentaloma: correlation with pathological findings. *ClinEndocrinol (Oxf).* 2004 Jan; 60(1):21-8.
16. Sandro Ceratti , Paula Giannini , Ricardo Antenor de Souza e Souza , Orlando Fermozelli Rodrigues Junior, Current status of FNAC for thyroid nodules. *Adv Surg.* 2006; 40:223-38.
17. Cooper DS, Doherty GM, Haugen BR, Kloos RT, Lee SL, Mandel SJ, Mazzaferri EL, McIver B, Sherman SI, Tuttle RM; Management guidelines for patients with thyroid nodules and differentiated thyroid cancer. *Thyroid* 2006; 16:109-142
18. Oftedal BE, Hellesnes et al Dominant mutations in the autoimmune regulator AIRE are associated with common organ-specific autoimmune diseases. *Immunity* 42:1185-96, 2015.
19. R P Morton, , J Watkinson, 3, A Shaha: Investigating the thyroid nodule H M Mehanna, director, A Jain, clinical research, , *BMJ* 2009 Mar 13; 338
20. Michael W. Yeh, Orhan Demircan, Philip Ituarte, and Orlo H. Clark False-Negative Fine-Needle Aspiration Cytology Results Delay Treatment and Adversely Affect Outcome in Patients with Thyroid Carcinoma *Thyroid* 2004 14 3 , 207 -215
21. Ernest L. Mazzaferri :Management of a Solitary Thyroid Nodule N Engl J Med 1993; 328:553-559 February 25, 1993 DOI: 10.1056/NEJM199302253280807
22. Harach HR, Franssila KO, Wasenius VM. 1985 Occult papillary carcinoma of the thyroid. A “normal” finding in Finland. A systematic autopsy study. *Cancer* 56:531–538.