



## Right Sided Varicocele Mimicking Inguinal Hernia

Authors

**Prof Dr Sribatsa Kumar Mahapatra<sup>1</sup>, Dr Lingaraj Hansda<sup>2</sup>, Dr Dharbind Kumar Jha<sup>3</sup>**

<sup>1</sup>Unit Head and Professor, <sup>2</sup>Post Graduate Student, <sup>3</sup>Post Graduate Student

Department of General Surgery, VIMSAR, Burla, Odisha, India

Contact number 9437025626, Email: [drskm2010@gmail.com](mailto:drskm2010@gmail.com)

### Abstract

*A scrotal varicocele is an abnormal dilation and tortuosity of the internal spermatic veins within the pampiniform plexus of the spermatic cord. Like cryptorchidism, varicocele is a common finding in otherwise normal males, may contribute significantly to the risk of infertility in adulthood, and is associated with a natural history that is poorly understood. Usually the varicocele is found in left side and is easy to diagnose. But in very rare condition it can be present on right side thus putting the clinicians in dilemma and confusing them with hernia. In our case we encountered with a 30yrs young man with right sided varicocele mimicking inguinal hernia. Intraoperatively we got evidence of thickened spermatic cord along with varicocele of pampiniform plexus with multiple small hard nodules may be due to thrombosis. Such rare and interesting presentation gives us a message to always keep varicocele as differential diagnosis in all cases of inguinal hernia with a high index of suspicion in mind.*

**Key Words:** Varicocele, hernia.

### BACKGROUND

Simple inguinal hernia presents as lump in the groin that goes away with lying down or with minimal pressure. Most cases may be painless or cause mild to moderate discomfort that increases with activity. Varicocele result from abnormal dilatation of pampiniform venous plexus of the scrotum that drained testicular venous blood and ascent through the inguinal canal to drain into inferior vena cava (on right side) or renal vein (left side).<sup>[1]</sup> Retrograde flow of blood into these venous channels can occur in various conditions such as absence of venous valve or incompetent valve or abnormal venous communication or pressure due to obstruction/compression upstream of the venous draining resulting in tortuosity and

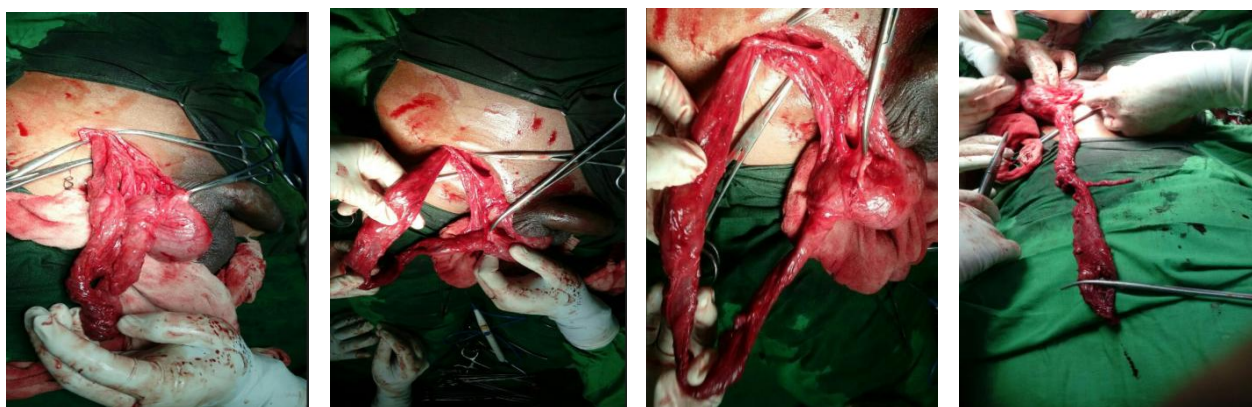
dilatation of vein . Abnormal dilatation may also mimic hydrocele or inguinal hernia. Simple varicocele is easily diagnosed by clinical examination; ultrasonography, Doppler imaging, and venography can be used to diagnose latent or complicated varicocele<sup>[1,2]</sup>. Most of the varicocele in clinical practice are on left side. We encountered a case of varicocele presented as gross inguinoscrotal swelling on right side mimicking inguinal hernia which used to disappear on lying down.

### CASE REPORT

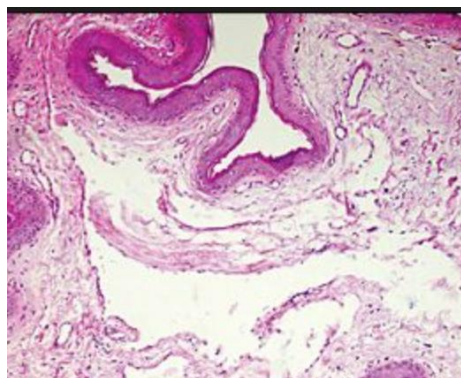
A 30yrs male was admitted to our hospital with chief complaint of swelling at right inguinoscrotal region since 12 years. The swelling was associated

with occasional pain. The swelling increased in size on walking and decreased in size while sleeping. The patient was admitted due to severe pain in right inguinoscrotal region. On examination in standing position a swelling in right inguinoscrotal region which was pyriform in shape about 7cm x 4cm in size. The swelling reduced in size in supine position and cough impulse was positive. The swelling was non tender, soft, incomplete, getting over swelling was negative, testis was felt separately from swelling.

Deep ring occlusion test was positive. On auscultation no bowel sounds heard. Usg finding was thickened spermatic cord. So our provisional diagnosis was indirect inguinal hernia. So we planned for hernioplasty. But intraoperatively we got a thickened spermatic cord along with varicocele of pampiniform plexus with multiple small hard nodules may be due to thrombosis. So we planned suprainguinal open approach and did mass ligation of the cord above the vas sparing lymphatic and artery.



**Fig 1,2,3,4** Intraoperative pictures showing varicocele.



**Fig 5:** showing vascular channels (pampiniform plexus)

Specimen was sent for histopathology which confirmed our diagnosis.

## DISCUSSION

Although varicoceles may be bilateral, they are usually unilateral and almost always on the left side. A unilateral right-side varicocele is a rare presentation confusing clinicians as typical bag of worm is not found and most commonly misdiagnosed as hernia or hydrocoele. So if any

suspicion is there one should prompt an investigation for other radiological investigations such as USG, Doppler, CT angiogram. Right sided varicocele should always be investigated for a retroperitoneal process such as a mass that causes obstruction of the right internal spermatic vein. Also thrombosis or occlusion of the inferior vena cava must be ruled out in all patients who present with a solitary right-side varicocele.<sup>[3,4]</sup> Situs inversus is another cause of a right-side varicocele. In our case the cause of varicocele may be due to thrombosis of pampiniform plexus of veins and there was no evidence of portal hypertension. Ultimately we cured the patient by palomo procedure.

## REFERENCES

1. Barroso U Jr, Andrade DM, Novaes H, et al. Surgical treatment of varicocele in children with open and laparoscopic Palomo technique: a systematic of the literature. *J Urol* 2009;181:2724–8.

2. Gargollo PC, Diamond DA. Current management of the adolescent varicocele. *Curr Urol Rep* 2009;10:144–52.
3. Kolon TF, Clement MR, Cartwright L, et al. Transient asynchronous testicular growth in adolescent males with a varicocele. *J Urol* 2008;180: 1111–14.
4. Laven JS, Haans LC, Mali WP, et al. Effects of varicocele treatment in adolescents: a randomized study. *Fertil Steril* 1992;58:756–62.