



Use of Immunohistochemistry in Prostatic Carcinoma

Authors

Dr Jyothi C R, Dr Jisha K T, Dr Joy Augustine, Dr Simi S

Associate Professor, Department of Pathology, Government Medical College, Thrissur, Kerala, India

Mobile no: 9495635733. Email: jyothicr@gmail.com

Dr Jisha K T

Assistant Professor, Department of Pathology, Government Medical College, Thrissur Kerala, India

Mobile no: 9447883193. Email: drjishakt@gmail.com

Abstract

Introduction: Use of immunohistochemistry in prostatic carcinoma

Materials and Method: All specimens of Prostatic needle biopsy received during the period of 9 months from 2012 October to 2013 June in the Department of Pathology, GMC-Thrissur were included in the study. Primary diagnosis made on H&E sections. A total of 35 cases of histologically proven prostatic adeno carcinoma cases were selected. Histological diagnosis was based on architectural pattern, absence of basal layer, nuclear atypia and prominent nucleoli. After Gleason Grading and Scoring were done, Immunohistochemistry was performed on all cases using six antibodies which include HWCK /34 β E12, CK5/6, p63 as basal cell specific antibodies which gives negative staining in invasive prostate carcinoma, AMACR, PSA, CKAE1/AE3 stains the malignant cells hence positive staining indicated carcinoma, PSA antibody to confirm prostatic origin of the neoplastic cells. Relevant clinical details including PSA values were also collected. Study was approved by the institutional ethical committee.

Result: All the three Basal cell markers were negative in 100% of adenocarcinoma cases hence are the best markers useful in the diagnosis of Carcinoma prostate. PSA and CKAE1/AE3 were positive in most of the cases hence maybe useful in the diagnosis of Carcinoma. AMACR was positive in one fifth cases only and hence is less useful than basal cell markers in the diagnosis of carcinoma prostate.

Conclusion: All the three Basal cell markers give 100% specificity in the diagnosis of Carcinoma prostate hence are the best markers useful in the diagnosis of Carcinoma prostate

Keywords: Carcinoma prostate, Immunohistochemistry, antibodies HWCK /34 β E12, CK5/6, p63, PSA, CKAE1/AE3 and AMACR.

Introduction

Prostate cancer is the most commonly diagnosed non-epidermal cancer and second-most common cancer-related cause of death in men in the western world.

Diagnosis of prostatic cancer (PC) is based on a combination of architectural, cytological and ancillary features rather than any single diagnostic feature none of which is absolutely sensitive and

specific. Accurate tissue diagnosis can be very challenging due to the presence of either a small focus of cancer or due to the presence of many benign mimickers of malignancy. Due to the widespread use of serum PSA as a mass screening test for prostate cancer there has been an ever increasing number of prostate needle biopsies and hence the need to give an accurate diagnosis despite the limitations and a number of tumor subtypes/

variants have emerged as distinct entities, some difficult to diagnose, especially in limited tissue fragments such as those of needle biopsy. Immunohistochemistry (IHC) has emerged as an important tool that can aid in confirming the diagnosis of minimal carcinoma and/or in distinguishing between prostatic adenocarcinoma and its mimickers. Benign glands contain basal cells, which are absent in cancerous glands and hence the use of basal cell markers (HMWCK 34bE12, p63, CK5/6) to label the basal cells when faced with an ambiguous lesion. More recently a positive marker for prostate carcinoma, alpha methylacyl CoA racemase (AMACR/p504S) has been reported to have sensitivity ranging from 82-100%. Immunostaining with Cytokeratin AE1/AE3 is also helpful in prostate carcinoma diagnosis in the post treatment setting. CK AE1/AE3 is helpful in highlighting individual atrophic prostate cancer cells and is superior to PSA, which can be suppressed by therapy and is, therefore, not detectable by immunohistochemistry following treatment.

PSA is highly expressed in benign prostate tissue as well as in the large majority of prostatic adenocarcinomas. PSA is highly sensitive and specific marker for adenocarcinoma of prostatic origin.

Objectives

1. To study the expression of Immunohistochemistry markers in adenocarcinoma prostate
2. To identify the best IHC markers in the diagnosis of adenocarcinoma of prostate

Materials and Methods

Case Selection

Hospital based Cross sectional study conducted in the Department of Pathology, Government Medical College, Thrissur. During the period October 2012-june 2013.

Prostatic needle biopsies with histologically proven adenocarcinoma cases were selected. Serum PSA values were also collected along with clinical details.

Sample size

A total of 35 prostatic needle biopsies from histologically proven cases of Prostatic Carcinoma specimens were collected.

Inclusion Criteria

All the prostatic needle biopsies with histologically proven Prostatic Adenocarcinoma

Exclusion Criteria

Prostatic biopsies which did not have representative areas of carcinoma after serial sections for immunohistochemistry

Study Design

All specimens of Prostatic needle biopsy received in formalin in the pathology department during the period of 9 months from 2012 October to 2013 June was processed and primary diagnosis made on H&E sections. Among them, adenocarcinoma cases were selected and Gleason Grading and Scoring done. Immunohistochemistry was done in cases of carcinoma to study the usefulness of six markers in prostate carcinoma. Histological diagnosis was based on architectural pattern, absence of basal layer, nuclear atypia and prominent nucleoli.

Histological grading was based on Gleason grading System.

There are 5 patterns.

Pattern 1 - Circumscribed nodule of closely packed but separate uniform rounded to oval medium sized acini

Pattern 2 - Like pattern 1, fairly circumscribed, yet at the edge of the tumor nodule, there may be minimal infiltration. Glands are more loosely arranged and not quite uniform as in pattern 1

Pattern 3 - Discrete glandular units. Typically smaller glands than seen in Gleason pattern 1 or 2. Infiltrates in and among nonneoplastic prostate acini, with marked variation in size and shape.

Pattern 4 - Fused microacinar glands. Ill defined glands with poorly formed glandular lumina.

Cribriform glands, Hypernephromatoid

Pattern 5 - Essentially no glandular differentiation, composed of solid sheets, cords or single cells

Comedocarcinoma with central necrosis, surrounded by papillary, cribriform or solid masses

Gleason Scoring System - Gleason score is a sum of two most common grade patterns - The primary

grade (representing the majority of tumor) and a Secondary grade (assigned to the minority of the tumor), and is a number ranging from 2 to 10. Immunohistochemistry was done in all cases using six antibodies. For Basal cells – 3 markers - HWCK /34βE12, CK5/6 and p63 were used. Positivity was indicated by membranous staining of cytoplasm of the basal cells for HMWCK/34βE12 and CK5/6 and nuclear staining for p63. Absence of staining indicated absence of basal layer which is one of the major criteria for the diagnosis of adenocarcinoma. AMACR, PSA and CKAE1/AE3 used to stain the neoplastic cells, hence positive staining indicated carcinoma.

Observations

Age Distribution

The age group of patients studied ranged from 57 to 86 years with majority of the patients in the age group 71- 80 years (48.5%)

Table 1 showing age distribution of cases

Age (in years)	No. of cases	%
50-60	6	17.14
61- 70	10	28.57
71- 80	17	48.57
81- 90	2	5.71

Serum PSA

Serum PSA values ranged from 13 to > 500 with 9 patients having values less than 50 (26%) and 20 above 50 (57%). In 6 patients the values were not available. Majority had values between 101-150 (31%) followed by values below 50 (26%)

Table 2 showing Serum PSA value

Serum PSA Values	No. of cases	%
< 50	9	26
50-100	5	14
101 -150	11	31
151-200	2	6
> 200	2	6
Not available	6	17
TOTAL	35	100

Gleason Scores

Gleason scores varied from 6 to 9 with majority having score 7

Table 3 showing distribution of Gleason score

Gleason score	No. of cases	%
6	6	17.14
7	13	37.14
8	9	25.71
9	7	20

IHC for basal cell markers

HMWCK, CK 5/6 and p63 were negative in the basal cells of all 35 cases (100%)

Table 4 for showing frequency of basal cell markers

HMWCK,CK5/6 AND P63	FREQUENCY	%
NEGATIVE	35	100
POSITIVE	NIL	NIL
TOTAL	35	100

IHC for epithelial lineage marker

KAE1/AE3 was positive in 31 cases (88.57%) and negative in 4 cases (11.42%)

Table 5 showing frequency of CK AE1/AE3

CKAE1/AE3	FREQUENCY	PERCENTAGE
POSITIVE	31	88.57
NEGATIVE	4	11.42
TOTAL	35	100

PROSTATE LINEAGE-SPECIFIC MARKER

PSA was positive in 31 cases (88.57%) and negative in 4 cases (11.42%)

Table 6 showing frequency of PSA

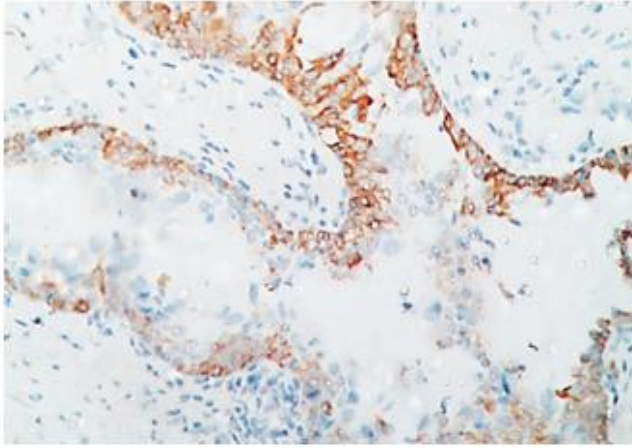
PSA	FREQUENCY	PERCENTAGE
POSITIVE	31	88.57
NEGATIVE	4	11.42
TOTAL	35	100

IHC FOR PROSTATE CARCINOMA-ASSOCIATED MARKER

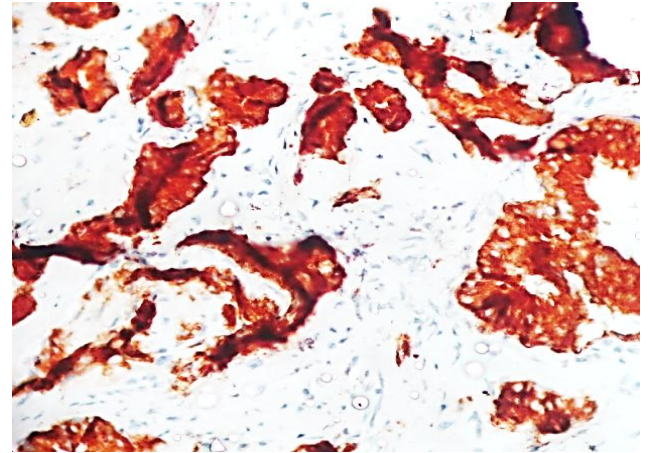
AMACR/p504S was positive in 9 cases (20%) and negative in 26 cases (80%)

Table 7 showing frequency of AMACR

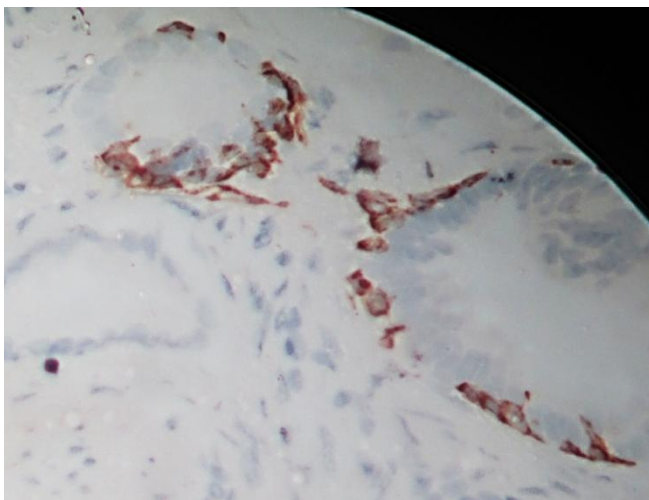
AMACR	FREQUENCY	PERCENTAGE
POSITIVE	9	20
NEGATIVE	26	80
TOTAL	35	100



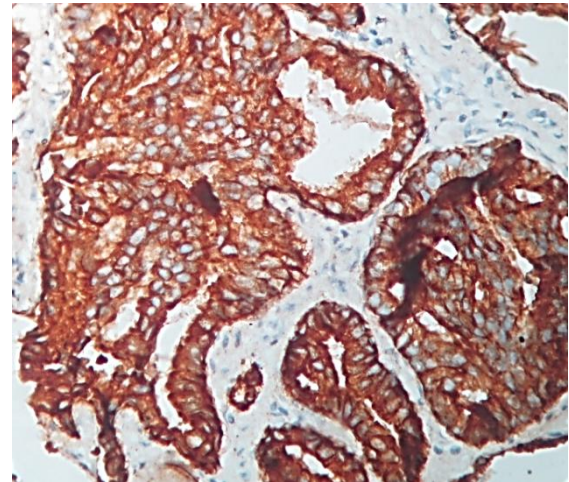
H&E 40 X – CK5/6 Positive in Basal Cells of Benign Glands



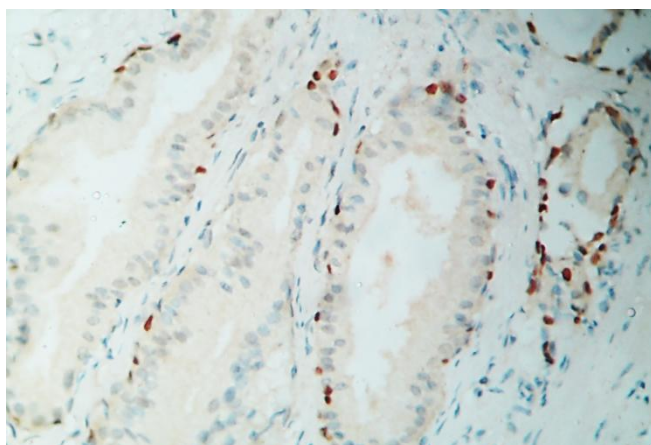
H&E 40 X – PSA Staining In Neoplastic Cells



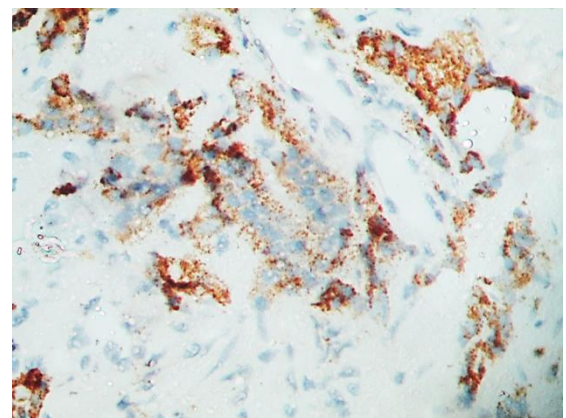
H&E 40 X – HMWCK Positive in Basal Cells of Benign Glands



H&E 40 X – CKAE1/AE3 Staining in Neoplastic Cells



H&E 40 X – P63 Positive in Basal Cells of Benign Glands



H&E 40 X – Amacr Staining in Neoplastic Cells

Discussion

Prostate cancer is the most commonly diagnosed non-epidermal cancer and second-most common cancer-related cause of death in men in the western world.

The diagnosis of prostatic cancer is based on a combination of architectural, cytological and

ancillary features rather than any single diagnostic feature none of which is absolutely sensitive and specific. Accurate tissue diagnosis can be very challenging due to the presence of either a small focus of cancer or due to the presence of many benign mimickers of malignancy. Due to the widespread use of serum PSA as a mass screening test for prostate cancer there has been an ever increasing number of prostate needle biopsies and hence the need to give an accurate diagnosis despite the limitations.

Immunohistochemistry (IHC) has emerged as an important tool that can aid in confirming the diagnosis of minimal carcinoma and/or in distinguishing between prostatic adenocarcinoma and its mimickers. We undertook this study to find out the usefulness of immunohistochemical markers in the diagnosis of carcinoma in prostate biopsy specimens. 6 markers were used – 3 basal cell markers – HMWCK, CK5/6 and P63 which will be negative in carcinoma, Prostate carcinoma associated marker AMACR, Prostate specific marker PSA and Epithelial lineage marker cytokeratin AE1/AE3 which will be positive in carcinoma. In this study majority of the patients in the age group 71- 80 years (48.5%) (Table 1) This is comparable to the WHO statistics where it is mentioned that Worldwide, about three-quarters of all cases occur in men aged 65 or more. Serum PSA values ranged from 13 to > 500, majority had values between 101-150 (31%) followed by values below 50 (26%) (Table 2). PSA is elevated beyond the arbitrary cut off point of 4.0 ng/ml in the majority of patients with prostate cancer as per WHO. Gleason scores varied from 6 to 9 with majority having score 7 (37.14%) followed by 8 (25.17%) (Table 3)

IHC for Basal Cell Markers

HMWCK, CK 5/6 and p63 were negative in the basal cells of all 35 cases (100%) (Table 4).

IHC FOR EPITHELIAL LINEAGE MARKER

CKAE1/AE3 was positive in 31 cases (88.57%) and negative in 4 cases (11.42%) (Table 5)

The cocktail of AE1 and AE3 detects acidic (CK10,CK14–16, and CK19) and basic (CK1–CK6 and CK8) cytokeratins and is the most universally used epithelial

Marker. In the post treatment setting, CK AE1/AE3 is helpful in highlighting individual atrophic prostate cancer cells and is superior to PSA, which can be suppressed by therapy and is, therefore, not detectable by immunohistochemistry following treatment.

Prostate Lineage–Specific Marker

PSA was positive in 31 cases (88.57%) and negative in 4 cases (11. 42%) (Table 6)

This is comparable to the study by Elizabeth M. Genega et al titled Immunophenotype of high grade prostatic adenocarcinoma and Urothelial carcinoma where PSA stained 94% of prostatic adenocarcinomas, but no urothelial carcinomas. Angela Quesser et al compared the different prostatic markers in lymph node and distant metastasis and found that Prostate-specific antigen having the highest sensitivity (97%)

IHC For Prostate Carcinoma–Associated Marker

AMACR/p504S was positive in 9 cases (20%) and negative in 26 cases (80 %)(Table 7)

This is in contrast to various studies where AMACR/p504S is seen in 75% to 95% of prostate carcinomas in diagnostic material staining observed across the spectrum of Gleason 5 to 10 carcinoma. Immunoreactivity to AMACR may be absent in 5% to 25% of typical prostate carcinomas. This may be explained by the loss of representative areas in serial sections or technical errors. Cutting and saving interval sections and performing immunohistochemistry on destained haematoxylin and eosin- are stained sections methods that can be used to increase the diagnostic yield of immunohistochemistry in the assessment of prostatic lesions.

p63/AMACR cocktail immunostaining are equivalent to those using each antibody individually.34bE12/AMACR and p63/34bE12/AMACR antibody cocktails results are quite similar to those using a p63/AMACR cocktail.

Pitfalls in the interpretation of Immunohistochemistry

Basal cells markers may be positive in benign

prostatic glands and it should not be taken as a feature against malignancy. AMACR may be positive in benign glands but the staining is weak. PSA is also positive in benign glands, hence caution is advised when using IHC for prostate cancer as it is only an adjuvant to histopathological diagnosis as the diagnosis of Prostatic adenocarcinoma is made on histopathology.

Limitation of our study

Controls were not studied along with prostate carcinoma cases and Lack of use of cocktails of antibodies to basal cells and AMACR which gives better results and makes interpretation easy.

Conclusion

35 prostate biopsy specimens with histopathological diagnosis of adenocarcinoma prostate received in the Department of Pathology, Government Medical College Thrissur were included in the study.

The age group of patients studied ranged from 57 to 86 years with majority of the patients in the age group 71- 80 years (48.5%)

Serum PSA values are above 50 in more than half cases of carcinoma.

HMWCK, CK 5/6 and p63 were negative in the basal cells of all 35 cases hence are the best markers useful in the diagnosis of Carcinoma prostate.

PSA and CKAE1/AE3 were positive in most of the cases hence maybe useful in the diagnosis of Carcinoma

AMACR was positive in one fifth cases only and hence is less useful than basal cell markers in the diagnosis of carcinoma prostate.

References

1. Siegel R, Naishadham D, Jemal A. Cancer statistics, 2012. *CA Cancer J Clin* 2012;62:10–29.
2. Epstein JI, Yang XJ: Prostate biopsy interpretation. 5th ed. Philadelphia, PA: Lippincott Williams & Wilkins. 2015.
3. Allis Demas, Soriano Talban, Elena Lazar, Angela Board, Cordoba Lăzureanu, Diana Herman et al. Pseudobeneign prostate carcinomas: causes of false-negative biopsy results. *Rom J Morphol Embryol* 2011, 52(3 Suppl):963– 974.
4. Omar Hameed and Peter A. Humphrey. Immunohistochemistry in the diagnosis of minimal prostate cancer. *Current Diagnostic Pathology* 2006; 12: 279–291.
5. Gladell P. Paner, Daniel J. Luthringer and Mahul B. Amin. Best Practice in Diagnostic Immunohistochemistry Prostate Carcinoma and Its Mimics in Needle Core Biopsies. *Arch Pathol Lab Med.* 2008; 132:1388–1396.
6. Katia R. M. Leite, Miguel Srougi, Adriana Sanudo, Marcos F. Dall’oglio, Adriano Nesrallah, Alberto A. Antunes, Jose Cury, Luiz H. Camara-Lopes. The Use of Immunohistochemistry for Diagnosis of Prostate Cancer. *International Braz J Urol.* Vol. 36 (5): 583-590, September - October, 2010
7. K Kumaresan, Nandita Kakkar, Alka Verma, Arup Kumar Mandal, Shrawan Kumar Singh and Kusum Joshi. Diagnostic utility of alpha-methylacyl CoA racemase (P504S) & HMWCK in morphologically difficult prostate cancer. *Diagnostic Pathology* 2010, 5:83.
8. Elizabeth M. Genega, Brian Hutchinson, Victor E. Reuter, Paul B. Gaudin. Immunophenotype of High-Grade Prostatic Adenocarcinoma and Urothelial Carcinoma. *Mod Pathol* 2000; 13(11):1186–1191.
9. Jeffrey S. Ross, Christine E. Sheehan, Hugh A. G. Fisher, Ronald P. Kaufman, Prabhjot Kaur, Karen Gray et al. Correlation of Primary Tumor Prostate-Specific Membrane Antigen Expression with Disease Recurrence in Prostate Cancer. *Clin Cancer Res* 2003;9:6357-6362.
10. Jae Y Ro, Alberto G Ayala, Steven S Shen. *Advances in Surgical Pathology. Prostate cancer.* Lippincott Williams 2012
11. Angela Queisser, Susanne A Hagedorn, Martin Braun, Wenzel Vogel, Stefan Duensing and Sven Perner. Comparison of different prostatic markers in lymph node

and distant metastases of prostate cancer
Modern Pathology (2015) 28, 138–145;

12. World Health Organization Classification of Tumours. Pathology and Genetics of Tumours of the Urinary System and Male Genital Organs Edited by John N. Eble Guido Sauter Jonathan I. Epstein Isabell A. Sesterhenn IARC Press Lyon,2004