



Comparative Study of Soft Tissue Neoplasm with Reference to Cytology & Histopathology

Authors

**Dr Kamlesh Yadav¹, Dr Mukesh Kumar Khinchi², Dr Manish Kumar Singhal³,
Dr Yogesh Gupta⁴, Dr Ashish Bagaria⁵, Dr. Rachna Agrawal⁶, Dr Vinod Kumari⁷**

¹Associate Professor, Dept of Pathology, SMS Medical College, Jaipur

^{2,4,5}Assistant Professor, Dept of Pathology, SMS Medical College, Jaipur

³Assistant Professor, SMS Medical College, Jaipur

^{6,7}Senior Demonstrator, Dept of Pathology, SMS Medical College, Jaipur

Abstract

Although tradition open incisional biopsy remains the diagnostic gold standard, FNAC has been identified as a useful diagnostic technique in the initial diagnosis of soft tissue neoplasm and is gaining importance because it is safe, cost effective, outdoor procedure along with high diagnostic sensitivity and specificity. Current study aimed to find out sensitivity, specificity and diagnostic predictive value of FNAC in soft tissue neoplasm assuming histopathology as gold standard. FNAC results in present study of soft tissue tumor had 100 % sensitivity, 97.36 % specificity, 89.28 % positive predictive value and 100 % negative predictive value in context of benign and malignancy.

Introduction

For over 100 years, the discipline of anatomical pathology has centered on diagnostic histopathology of surgical biopsy material by which therapy is determined. For the last 60 years, exfoliated and abraded samples of cells have also been collected from accessible anatomical surfaces; especially from the uterine cervix and the bronchus.

The purpose of aspiration biopsy is to obtain diagnostic material for cytological study from organs that do not shed cells spontaneously. The term fine needle aspiration cytology (FNAC) was chosen to clearly distinguish aspiration from exfoliative cytology and to emphasize its simplicity. The optimum success of this procedure requires an interdisciplinary approach among clinicians, radiologists and pathologists.

The ease of FNAC procedure coupled with a rapidity of obtaining the cytological diagnosis makes the procedures valuable diagnostic tools, particularly in pre-operative management of soft tissue tumors.

Although traditional open incision biopsy remains the diagnostic gold standard, FNAC has been identified as a useful technique in the initial diagnosis of soft tissue neoplasm and is gaining importance because it is safe diagnosis of soft tissue is gaining importance's because it is safe, cost effective, outdoor procedure along with high diagnostic sensitivity and specificity.

The Present study was conducted in 159 patients of soft tissue tumors in the Department of Pathology, SMS Medical College & Hospital, Jaipur. Details of case history and clinical

examination were recorded. Cytomorphological observations were recorded and cytodiagnosis was made after routine tissue processing. Cytology findings were then correlated with histopathological findings. Out of 159 cases of soft tissue tumor subjected to FNAC, 153 cases were followed by excisional biopsy.

Material and Methods

This study was conducted in the department of pathology at SMS medical college and hospital jaipur during the period of one year .it was hospital based validational observational study. All eligible cases of FNAC slides were stained by H& E and MGG and were confirmed by histopathological diagnosis and by immunohistochemistry whenever required.

The aspirate was spread rapidly over the slide to form a thin flim with the help of other slides, 3-4 wet slides were fixed in ethyl alcohol and 2-3

films were air dried for MGG staining. The Haematoxylin and eosin, May grunwald and giemsa stain stains were used on cytologic smears.

Observation

The Present study was conducted in 159 patients of soft tissue tumors in the Department of Pathology, SMS Medical College & Hospital, Jaipur. Details of case history and clinical examination were recorded. Fine needle aspiration was done with 22-23 gauze needle. Smears were fixed and subsequently stained by haematoxylin & eosin and May-Grunwald Giemsa stains. Cytomorphological observations were recorded and cytodiagnosis was made after routine tissue processing. Cytology findings were then correlated with histopathological findings. Out of 159 cases of soft tissue tumor subjected to FNAC, 153 cases were followed by excisional biopsy.

The finding are as follows-

- Total number of cases aspirated 159
- Unsatisfactory Smear 14
- Adequate aspirates 145
- Cytological diagnosis not consistent with histopathological diagnosis 3
- Cytological diagnosis consistent with histopathological diagnosis 136
- Six cases refused to operate so Histopathological diagnosis could be made in 153
- Accuracy of aspiration cytology in comparison to histopathological diagnosis 88.88%

Percentage distributions of different types of lesions on cytology

S.no	Cytodiagnosis	No. of Cases	Percentage
A.	Benign	117	
	Lipoma	66	56.41
	Schwannoma	11	9.40
	Neurofibroma	10	8.55
	Fibromatosis	14	11.97
	Cystic Lymphangioma	6	5.13
	GCT of tendon sheath	2	1.71
	Leiomyoma	2	1.71
	B.Mesenchymal neo. (Undifferentiated)	6	5.13
B.	Malignant	28	-
	Spindle cell Sarcoma	13	46.43%
	Myxoid Cell Sarcoma	2	7.14%
	Round Cell Sarcoma	10	35.71%
	Pleomorphic sarcoma	1	3.57%
	Non specified malig. Mesen. Neoplasm	2	7.14%
C.	Unsatisfactory	14	-

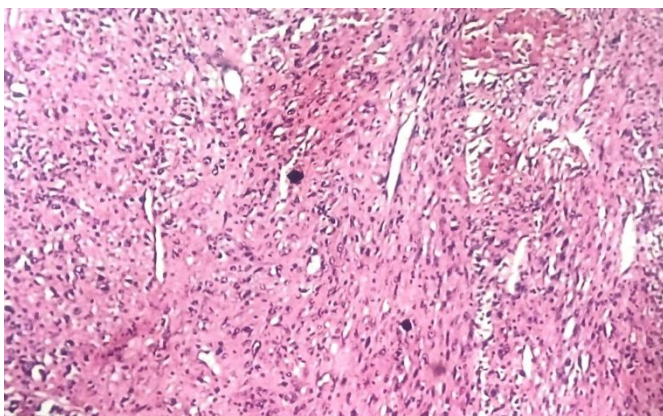
Histopathological appraisal – Nature of lesion –age wise

Age Group	Benign	Percentage	Malignant	Percentage	Total	%(Total)
0-10	1	0.65%	1	0.65%	2	1.31%
11-20	12	7.84%	5	3.27%	17	11.11%
21-30	35	22.88%	1	0.65%	36	23.53%
31-40	38	24.84%	4	2.61%	42	27.45%
40-50	00	0.00%	2	1.31%	2	1.31%
41-50	27	17.65%	3	1.96%	30	19.61%
50-60		0.00%	2	1.31%	2	1.31%
51-60	13	8.50%	1	0.65%	14	9.15%
61-70	2	1.31%	6	3.92%	8	5.23%
Grand Total	128		25		153	

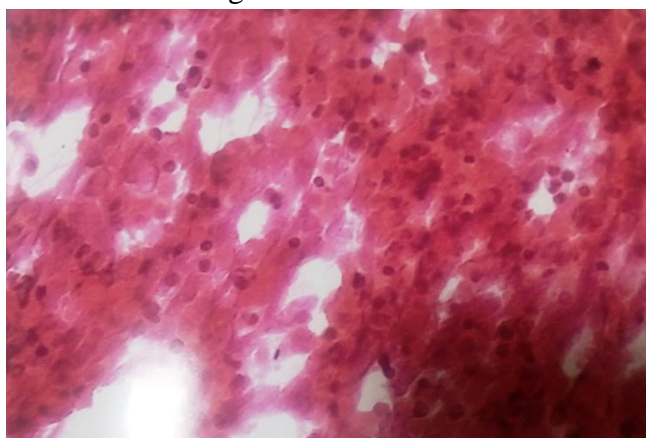
Highest number of cases in the present study were in 31-40 year age group, 42 cases (27.45 %) next in order of frequency were 36 (23.53%) cases in 21-30 years age group.

Maximum number of benign cases were found in 31-40 years age group, 38 cases (24.84%), next in order of frequency were 35 (22.88%) in 21-30 years of age group.

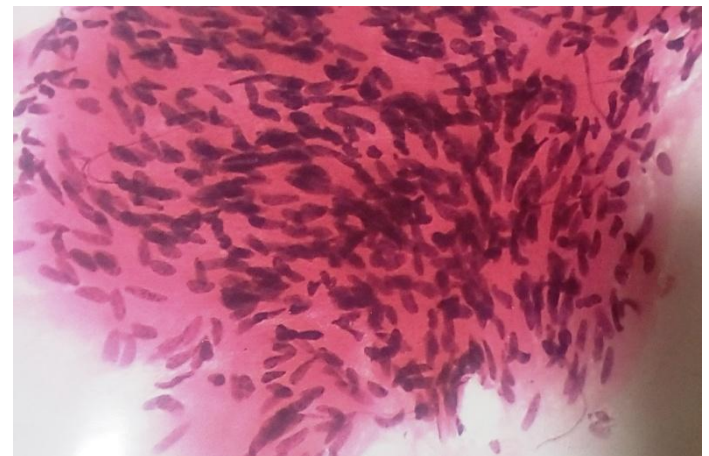Maximum number of malignant cases were found in 61-70 years of age group 6 cases (3.92%)



Leiomyosarcoma- fascicular pattern with tumour bundle intersecting each other.



Fna smear synovial sarcoma- highly cellular smear showing mixture of tissue fragments and dispersed cell and vague acinar like structure.



FNA Smear-Leiomyoma benign smooth muscle cell with blunt ended bland looking nuclei.

Discussion

In the present study 159 Patients suffering from soft tissue tumors admitted in various surgical wards or attending outpatients department of SMS Hospital, Jaipur were included.

Fine needle aspiration of soft tissue tumors was performed. From each case four smears were prepared, two of them were fixed in 95 % alcohol and rest of the two were air-dried. The wet smears were stained by hematoxylin and eosin and one dried smear was stained with may grunwald – Giemsa stains (Franzen and Zanicek, 1968).

Out of 159 cases, which were subjected to FNA in present series 117 cases were reported as benign, 28 cases were reported malignant. 14 cases were reported as unsatisfactory because of very low cell content. In present study ratio of benign : malignant lesion was 4.44:1. The age distribution of these cases revealed that benign lesion were more common in 3rd & 4th common in 6th decades. Out of 117 cases categorized cytologically as

benign, 66 cases were lipoma, 11 neurilemmoma, 10 fibromatosis, 14 neurofibroma, 6 cases of cystic lymphangioma and 2 cases were each of giant cell tumor of tendon sheath and leiomyoma while six cases were non specified.

Cytosmear of lipoma showed that lipoma is same as that of normal adipose tissue, thus the diagnosis requires typical clinical findings. In the present study as well in others the lipoma is the most frequently diagnosed benign neoplasm. Layfield et al (1986) conducted fine needle aspiration cytology in a series of 136 primary soft tissue tumor⁽¹⁾. 52 of the cases were given a specific benign diagnosis of which 14 were lipomas . Miralles et al (1986) reviewed the use of fine needle aspiration cytology in 117 cases of soft tissue lesion. Out of which 34 cases were benign mesenchymal tumors. The most frequently diagnosed benign mesenchymal tumors were lipomas.

In the present study the total number of cases of neurilemmoma and neurofibroma were 11 and 14. The cytomorphology was characterized by benign looking spindle cells having long and slender nuclei with pointed ends chromatin were uniformly bland. Intercellular stroma was fibrillar. Ten cases of fibromatosis revealed good cellularity, loose aggregates of benign cells with collagen, which suggested diagnosis of benign spindle cell neoplasm. Nodular fasciitis fibroma, neurofibroma and low grade fibrosarcoma were considered in the differential diagnosis. However, exact cytomorphologic diagnosis was possible only by histopathology.

Nine case was reported as capillary hemangioma from the present analysis (by histopathology). Six cases were reported as cystic lymphangioma, smear of which showed numerous mature small lymphocytes in a background of eosinophilic proteinaceous material.

Shaham beg et al (2012) also found in their study that out of the 25 vascular tumors histology, there were 20 cases of hemangioma and 1 case of Lymphangioma⁽²⁾ diagnosed mainly on clinical history and examination as FNAC showed only blood and lymph respectively with few

endothelial cells in occasional cases. Three cases of hemangioma were inconclusive on cytology.

Two cases were reported as leiomyoma, cellular smear reveal stromal tissue fragment comprising of spindle cells having oval to spindle nuclei arranged in bundles . Nucleus were vesicular with rounded ends moderate amount of cytoplasm, inconspicuous cell boundaries.

Two cases were reported as giant cell tumors of tendon sheath, smears comprised of individually dispersed round to plump spindle shaped mononuclear cells having smooth round to oval nuclei with fine chromatin and single small nucleoli. The smear also showed a fair number of multinucleated giant cells with many hemosiderin laden macrophages.

In the present study the total number of malignant cases was 28. The cellularity was adequate in 23 (82.14 %) of the cases and low in 5 (17.85%) of the cases.

Out of 28 cases subjected to FNAC 13 were cytologically reported as fasciculated spindle tumors (Low grade sarcoma), 2 cases were reported as myxoid soft tissue lesion, 10 cases were reported as round cell sarcoma, 1 case reported as pleomorphic sarcoma.

Two cases were diagnosed as malignant mesenchymal neoplasm, (not specified) and they turned benign (lipoma) on histopathology.

Three cases of neurogenic tumor were reported in present study by cytology it was not possible to differentiate between neurosarcomas, Low grade Fibrosarcomas and Leiomyosarcoma Miralles et al (1986) had similar observation⁽³⁾.

Five case of synovial sarcoma were reported . The specific diagnosis was only possible by histopathology in comparison to fibrosarcoma. Some of the cells were more plump, monophasic architectural pattern was discernable on performing IHC tumor cells were positive for Vimentin and showed focal positivity for NSE, Bcl-2 and EMA.

The group formed a heterogeneous category except for the myxoid background that stained pink MGG and was eosinophilic with

histopathological examination. Miralles et al (1986) have included myxoid malignant fibrous histiocytoma, myxoid liposarcoma, Mesenchymal chondrosarcoma, and rarely malignant Schwannoma with myxoid areas.

In the present study one case revealed an admixture of fibroblasts, histiocytes and few giant cells in a myxoid background having features of malignant. These findings were suggestive of malignant fibrous histiocytoma.

One case reported suggestive of myxoid liposarcoma. Cytological features were considered as described by the Szadowska A et al (1993)⁽⁴⁾ The most consistent cytological features were: abundant myxoid matrix, several small tissue fragments with uniform small, round or stellate cells and a network of branching thin-walled capillaries. The presence of univacuolated or multivacuolated lipoblasts was noted frequently, but not in all aspirates.

The present series had 2 cases in which diagnosis of embryonal rhabdomyosarcoma was suggested on cytology and confirmed by histopathology. The presence of large cell with large nuclei with eosinophilic greasy cytoplasm and few spindle cells gave clue. Linsk and Franzen (1986) and miralles et al have also emphasized the presence of rhabdomyoblasts in the diagnosis⁽⁵⁾. Jerzy Klijanierko (2007) et al also similar findings in their series⁽⁶⁾. On performing IHC tumor cells showed positively for vimentin and desmin. Tumor cells were negative for CD3, CD20, CD99, chromogranin, NSE and PAN-CK.

In three cases in this category adequate cellularity was obtained. The cases were reported as round cell liposarcoma on cytological examination round to oval plump cells was found. Cells were mostly dispersed. Nuclei were round. Chromatin was bland. Cytological diagnosis was confirmed by histopathologic examination.

One case turned out to be benign (Lipoma) on histopathology. The case was cytologically categorized as well-differentiated liposarcoma. However, it turned out to be lipoma on histological examination (this constituting one

false positive case). It seems that aspirates of Lipoma show more cellularity and pleomorphism as compared to histologic sections and when correlated with size and rapid growth false diagnosis can be made. Miralles et al (1986) also had one cellular lipoma in their series with false positive diagnosis of well differentiated liposarcoma.

5 cases in this category were reported as Ewing's sarcoma (extra skeletal)

FNAC revealed cellular smears composed of densely dispersed, small, monomorphic round cells with fine nuclear chromatin and round nuclei and scanty clear cytoplasm. Occasional mitoses were noted at places.

Many cells showed irregularly vacuolated cytoplasm which on periodic acid schiff (PAS) stain revealed intense PAS Positivity. Focal areas showed striking clusters, occasional rosette-like formations and molding of nuclei. The background was clean. On performing IHC, Neoplastic cells were positive for CD-99. These findings were consistent with finding of Archana C Buch et al (2010)⁽⁷⁾

Sensitivity, specificity and positive predictive values were calculated as per feichter et al (1997). High sensitivity rate is observed by many authors. Kline et al (1997) reported 86 % of sensitivity. Bharat rekhi et al (2007) observed 100 % sensitivity⁽⁸⁾. In our study sensitivity was 100 % A very high specificity nearly 100 % was observed by most of the author. Abele et al (1983), Kline et al (1979), Zajdela (1975)⁽¹⁰⁾ choukimath M et al (2012)⁽⁹⁾ had observed 100 % specificity. Bharat et al (2007) reports specificity as 83.3 %. In our study specificity was 97.36 % Overall diagnostic accuracy defined as overall proportion of correct diagnosis made by aspiration cytology.

Parajuli S et al (2012) reported 86 % diagnostic accuracy of fine needle aspiration cytology in soft tissue tumors⁽¹¹⁾.

Conclusion

Cytological Technique like FNAC can be adopted to give a preoperative diagnosis of the lesion. Diagnosis of benign mesenchymal neoplasm in general do not pose a diagnostic problem. Overall exact type specific diagnostic accuracy of cytology was 88.88 % in comparison to histopathology. The diagnostic accuracy of FNAC for malignant lesion was 89.28 % and for benign lesion was 86.71%. FNAC results in present study of soft tissue tumors had 100 % sensitivity , 97.36 % specificity, 89.28 % positive predictive value and 100 % negative predictive value in context of benign and malignancy. There were 3.27 % cases of malignancy in relatively younger age group of 21-30 years. It showed the importance of FNAC in early diagnoses of malignancy in unsuspected soft tissue tumors.

Bibliography

1. Layfield LJ, Anders KH, Glasgow BJ, Mira JM. Fine needle aspiration of primary soft-tissue tumors. *Arch Pathol Lab Med.* 1986;110:420–424.
2. Shaham Beg et al; A comparison of cytological and histopathological findings and role of immunostains in the diagnosis of soft tissue tumors; *Journal of Cytology, Vol. 29, No. 2, April-June, 2012, pp. 125-130*
3. Miralles TG, Gosalbez F, Menendez P, Astudillo A, Torre C, Buesa J. Fine needle aspiration cytology of soft tissue lesions. *Acta Cytol* 1986;30:670-7
4. Szaadowska A, Lasota j, fine needle aspiration cytology of myxoid liposarcoma 1993 4(2).
5. Linsk JA, Franzen S. Aspiration biopsy of the testes. In: Linsk JA, Franzen S, editors. *Clinical aspiration cytology.* 2nd ed. Philadelphia: JB Lippincott; 1983. pp. 267–79.
6. Jerzy Klijanienko M.D.,Jean-Michel Caillaud M.D.,Daniel Orbach M.D.,Hervé Brisse M.D.,Réal Lagacé M.D., F.I.A.C.,Xavier Sastre-Gareau M.D. et al Cyto-histological correlations in primary, recurrent, and metastatic bone and soft tissue osteosarcoma. *Institut Curie's experience. diagnostic cytopathology Vol. 35, Issue 5 May 2007 Pages 270–275*
7. Archana C Buch, NK Panicker, Sweta Sarawagi, Sampada Anwekar, and Amit T Kharat; Fine needle aspiration cytology diagnosis of paravertebral extraosseous Ewing's sarcoma; *J Cytol.* 2010 Oct; 27(4): 146–148
8. Bharat rekhi et al ; Scope of FNAC in the diagnosis of soft tissue tumors-A study from a tertiary cancer referral center in India; *CytoJournal* 2007, 4:20
9. Choukimath M Sharanabasav and Rangappa P K; Fine Needle Aspiration Cytology Of Soft Tissue Tumors With Special Emphasis On Grading Of Spindle Cell Sarcomas.Ijabpt; Volume 3,issue-2,april-june-2012
10. Zajdela MD,N. A. Ghossein MD,J. P. Pilleron MD,A. Ennuyer MD; The value of aspiration cytology in the diagnosis of breast cancer: Experience at the fondation curie; Volume 35, Issue 2 February 1975 Pages 499–506
11. S Parajuli, M LakheyM; Efficacy of fine needle aspiration cytology in diagnosing soft tissue tumors; *Journal of Pathology of Nepal > Vol 2, No 4 (2012)*