



Unilateral Subarachnoid Block for Surgeries in Neoplastic Breast Diseases- A Novel Trend

Authors

Dr S D Yannawar¹, Dr Sarfaraz Ahmed², Dr R G Pathak³, Dr N K Nandanwankar⁴,
Dr Nazima Memon⁵

^{1,4}Associate Professor, ^{2,5}Assistant Professor, ³Professor and Head
Department of Anesthesia Dr Shankarrao Chavan Govt Medical College Nanded – India

Corresponding Author

Dr Sarfaraz Ahmed

Assistant Professor, Dept of Anesthesia Dr Shankarrao Chavan Govt Medical College Nanded – India

Abstract:

Background: Carcinoma breast is the most common malignancy in Indian women which has recently overtaken cervical carcinoma as leading cause of cancer related morbidity and mortality. In India the incidence of carcinoma breast had been traditionally lower than in developed world. Some of this low incidence may have been due to lack of screening programs but lifestyle, reproductive and dietary factors also had a favorable outcome on low incidence. But this scenario is fast changing and along with change in life style in developing countries, awareness in general public and availability of equipments to detect the disease at peripheral health centers may be the reasons for increase in the incidence of carcinoma breast. Surgeries for carcinoma breast like simple or radical mastectomy are usually done under general anaesthesia. Spinal anaesthesia for mastectomies appears to be a promising new trend having advantage of decreased morbidity, less complications and early recovery.

Aims and Objectives: (1) To evaluate utility of unilateral subarachnoid block for surgeries for carcinoma breast and to study amount of analgesic and anesthetic drug if required. (2) To study complications associated with subarachnoid block in surgeries for carcinoma breast.

Materials and Methods: This was a prospective study conducted at a medical college in an urban area. Patients who had undergone surgeries for neoplastic breast diseases (carcinoma, breast phyllodes tumor) under unilateral subarachnoid were included in the study after considering inclusion and exclusion criteria of the study. Age, sex, weight, any associated co-morbidity and ASA status of the patients were recorded. For subarachnoid block inj. bupivacaine (0.5%) 2.8 ml with 0.2ml (60mcg) inj. buprinorphine were used. Events during surgery, hemodynamic stability and complications were studied.

Results: Total 90 patients were given unilateral subarachnoid block for their respective neoplastic breast diseases. 8 patients required conversion to general anaesthesia hence were excluded from the study. Out of 82 cases 47 cases were of simple mastectomy and 35 were of Modified radical mastectomy with Axillary dissection. Out of these 35 cases 15 cases required IV sedation. Out of 47 simple mastectomy cases none required additional analgesia. Inj. mephentermine for hypotension and inj Atropine for bradycardia had to be used in 35 and 3 patients respectively. No patient required intubation. Recovery was excellent in all the cases.

Conclusion: Unilateral subarachnoid block is a novel method of anaesthesia during surgeries for breast tumours. It is relatively safe and associated with good muscle relaxation and less blood loss.

Keywords: unilateral subarachnoid block, Carcinoma Breast, Complications and Outcome.

Introduction

Having recently overtaken cervical cancer carcinoma breast is now the most common cancer in Indian women^[1]. Various studies have reported the incidence of breast carcinoma to be in between 15-30 per 10000 women^[2]. These neoplastic diseases are being more frequently treated by surgical interventions. Moreover the surgeries for neoplastic breast diseases are becoming more conservative. The choice of surgery depends upon type, extent and receptor status of the neoplastic diseases involving breasts^[3].

Traditionally the incidence of breast cancer has been low in developing countries like that of India but with change in life style in developing countries, awareness in general public and availability of equipments to detect the disease at peripheral health centers are the reasons that incidence of disease has been increased^[4]. The use of mammography as a tool to diagnose breast malignancies have definitely reduced the morbidity and mortality associated with carcinoma breast but it has caused an increase in prevalence of patient with carcinoma breasts due to early detection and increased survival^[5]. Early diagnosis with the use of screening mammography is one of the important causes of detection of carcinoma breast in an early stage and consequently more conservative surgeries are being done in comparison with radical surgeries^[6]. Various surgical options available for treatment of carcinoma breast include lumpectomy, simple mastectomy, Modified radical mastectomy and Axillary dissection with or without breast reconstruction depending upon availability of resources at the peripheral health centers. As sophisticated and advance modalities of treatment are not within reach of the poor sector of the community, increased number of cases at higher centers may cause delay in definitive treatment leading to progression of the disease and many patients are reluctant to go to a higher centre for treatment. In these circumstances a more practical approach emerging is operating these patients at peripheral health centers where infrastructure

for a major surgery is not always available. In all such cases surgeries at a peripheral health care centre under unilateral subarachnoid block is a practical option available with reduced post-operative morbidity and complications^[7].

For breast surgeries like simple, radical or modified radical mastectomies general anaesthesia is standard technique at tertiary care centers where expert anesthetists have modern equipments at their disposal but at peripheral health centers where the availability of inhalational agents , opioid analgesic and modern monitoring equipment is scarce and cost of treatment is also an important factor neuraxial anesthesia is an important alternative^[8,9]. Surgical procedures like modified radical mastectomy and simple mastectomy can be done under regional anaesthesia. There are many studies reporting breast surgeries under cervical as well as thoracic epidural and para-vertebral blocks but very few studies have been undertaken to report successful breast surgeries under subarachnoid block^[10,11]

One of the important aspects of breast surgeries for neoplastic lesions under anaesthesia is the effect of general anaesthesia on recurrence of malignancy due to its suppressive effects on immunity and metastasis of cancers^[12,13]. Although there is no definite evidence to prove this but being a regional anaesthesia subarachnoid block is expected to have a suppressive effect on neurohumoral response to stress of surgery and hence doesn't lead to immune suppression may have an added advantage over general anaesthesia though further studies are required to fully prove this^[14,15].

Materials and Methods

This was a prospective cohort study comprising of patients undergoing breast surgeries for various neoplastic diseases involving breasts. The study was approved by institutional ethical committee. The study was conducted at a medical college situated in an urban area. Total 86 patients who were posted for various surgeries for neoplastic breast diseases were enrolled in this study. All

surgeries in these patients were done under unilateral subarachnoid block. Age, sex, weight, any co morbidity and ASA status of the patients were recorded. Patients who was getting pain during surgery due to inadequate level and required intubation and general anesthesia were excluded from the study, method of subarachnoid block was similar for all the patients. After checking for consent, pre-anesthetic fitness and NBM status all patients were attached the monitor, ECG, pulse oximeter and NIBP. First baseline parameters were note down and 20G intaracath was put in the upper extremity of non operative side. All patients were preloaded with 500 ml of Ringers Lactate. Patients were positioned in lateral decubitus spinal position with a head tilt of 20 to 30 degrees, after cleaning and draping under all aseptic precaution lumbar puncture was done in the intervertebral space L2-L3 using a 25G spinal needle. After free and clear flow of CSF inj. bupivacaine heavy (0.5%) 2.8 ml with 0.2ml (60mcg) inj. buprinorphine were injected slowly over 1 minute, patient was kept in the same position for another 5-10 min till the time sensory block to the T2 dermatome was achieved on the operative side, sensory block of the opposite side was two to four segment lower than the operative side that is T4-T6. Continuous monitoring of the patients was continued with recording of pulse rate, blood pressure and ECG every minute for first 15 minutes followed by ECG every 5 minute. Fluid input and output charting was done. Maintenance fluid was calculated as per NBM hours and maintenance fluid requirement. To maintain normal mean arterial blood pressure some patients required vasoconstrictor in the form of inj .mephinteramine 6 mg IV boluses once or twice. The need for vasopressors was also recorded. Patients were kept in OT till full recovery from motor blockade was achieved. Events during surgery, hemodynamic stability and complications were studied.

Inclusion Criteria

1. All patients undergoing surgery for breast tumours (Benign or Malignant).
2. All patients who had undergone surgeries exclusively under unilateral subarachnoid block.
3. Age between 18-70 years.
4. ASA I and II.

Exclusion Criteria

1. Patients who refused consent.
2. Patients allergic to local anesthetic drugs.
3. Patients who required conversion to general anaesthesia.
4. ASA Grade III or more.

Results

This was a prospective cohort study in which 82 patients with ASA I or II undergoing simple mastectomy or modified radical mastectomy with axillary dissection were included as per the inclusion criteria. They were excluded from the study if any factor defined as exclusion criteria was present in any of the cases. Initially 90 patients were enrolled in this study depending upon the inclusion criteria. The patients belonged to age group between 39-60 years with a mean age of 50 years. Mean weight and height was found to be 56.5 +/- 8.6 kg and 150.6 +/- 6.7cm respectively. Out of these 90 patients 8 patients were eventually excluded because these patients were converted into general anaesthesia due to inadequate level of blockade (Figure 1).

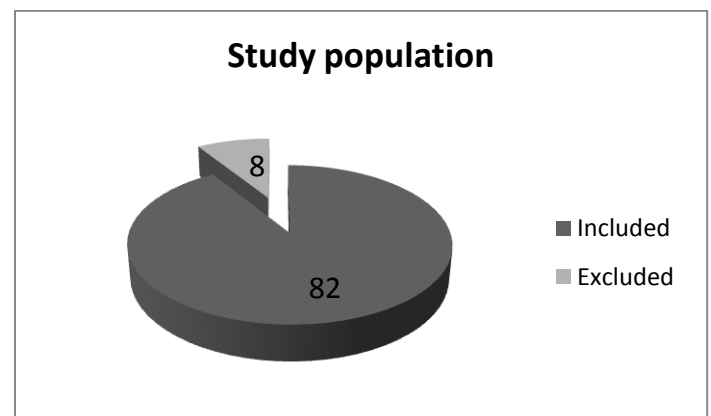


Figure 1: Details of the excluded patients due to conversion to general anaesthesia.

Out of the total 82 patients who had been included in this study 47 (57.32%) patients underwent simple mastectomy while 35 (42.68%) patients

underwent modified radical mastectomy with axillary dissection (Figure 2).

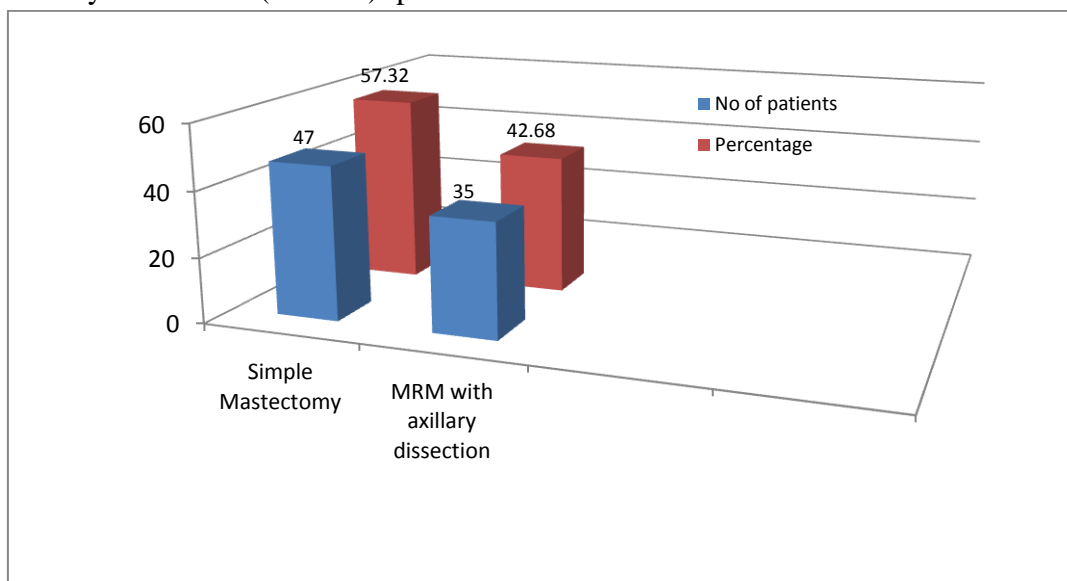


Figure 2: Distribution of the cases on the basis of surgical procedure.

The distribution of the patients on the basis of ASA grades revealed that out of 47 patients undergoing simple mastectomy 35 (42.68%) belonged to ASA I while remaining 12 (14.63%) belonged to ASA II. While amongst the 35 patients undergoing modified radical mastectomy

with axillary dissection 15 (14.29%) patients belonged to ASA I and remaining 20 (24.39%) patients belonged to ASA II. Overall 50 (60.98%) patients belonged to ASA I and 32 (39.02%) patients belonged to ASA II (Figure 3).

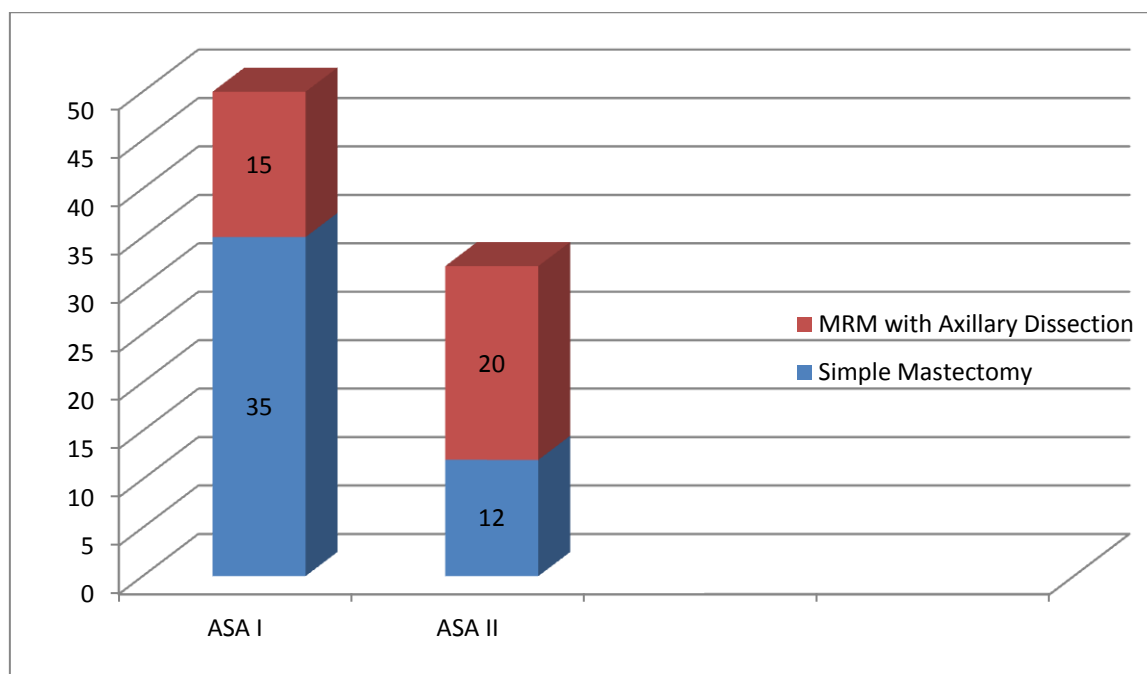


Figure 3: Distribution of the cases on the basis of ASA grades.

Adequate block level was achieved in all patients (T4-T2). The average time to achieve the adequate block was found to be between 5-15 minutes with

an average of 5 minutes. The duration of surgery ranged from 80-140 minutes with a mean time of 110 minutes.

The cases were also analyzed on the basis of whether or not they required any additional analgesia or sedation. Out of 47 patients undergoing simple mastectomy no patient

required any additional analgesia. While out of 35 patients undergoing modified radical mastectomy with axillary dissection 15 patients required Inj Midazolam and Inj Pentazocine (Figure 4).

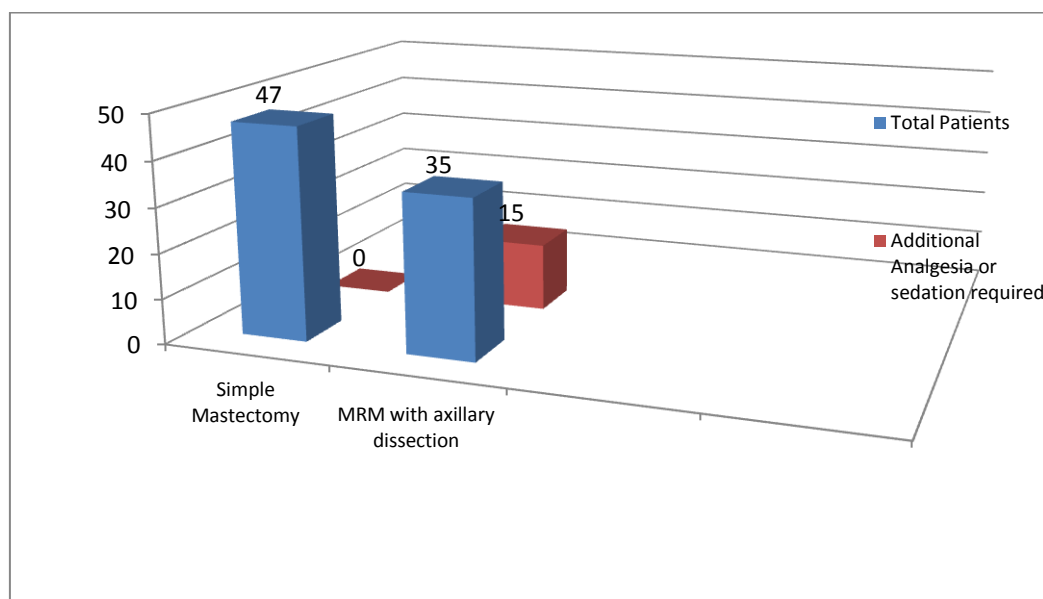


Figure 4: Distribution of the cases on the basis of requiring additional analgesia or sedation.

Systolic and diastolic blood pressure values and heart rate was recorded in all the cases before induction and after giving anasesthesia at a regular

interval. Mean systolic and diastolic blood pressures and mean heart rate values are depicted in the figure given below (Figure 5).

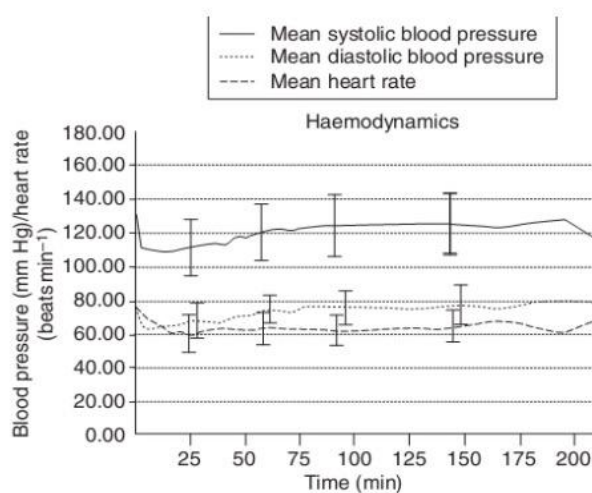


Figure – 5 Mean systolic and diastolic blood pressures and heart rate plotted against time. Lines indicate means and error bars denote range.

Just before induction and during the whole period of surgery SPO2 levels were maintained and there was no significant fall in SPO2 levels in any of

the patients undergoing simple mastectomy or modified radical mastectomy with axillary dissection (Figure 5).

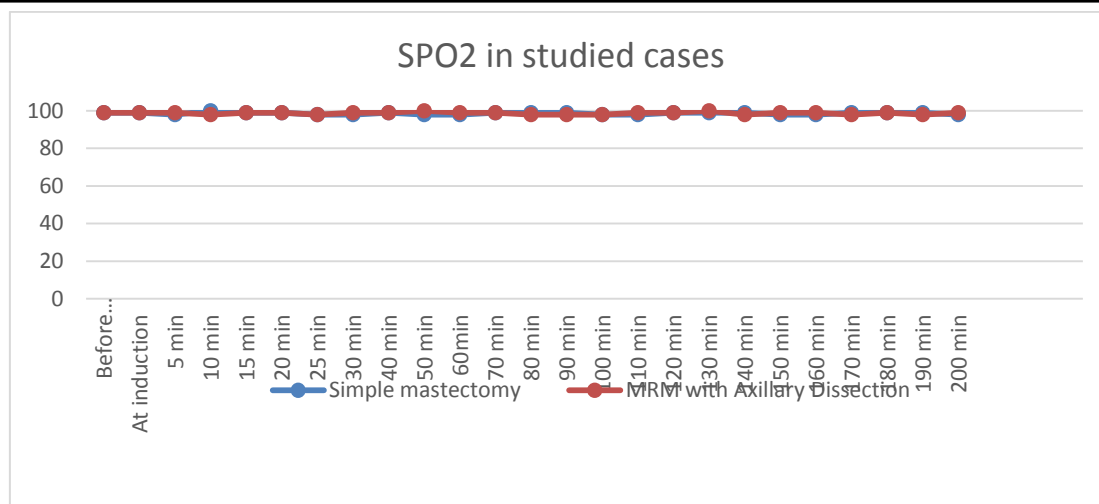


Figure 6: SPO2 levels before induction and during surgery in studied cases

The analysis of complications occurring during surgeries revealed that 35 (42.68%) patients developed hypotension and inj. Mephenteramine was required to manage this hypotension while bradycardia was seen in 3 (3.66%) patients and

was treated by inj atropine. Intraoperative nausea was seen in 10 (12.2%) patients while postoperative nausea and vomiting was also seen in 10 patients (12.2%) (Table 1).

Table 1: Incidence of complications in the studied cases

Complication	No Of patients	percentage
Hypotension	35	42.68%
Bradycardia	3	3.66%
Intraoperative nausea	10	12.2%
Post-operative nausea and vomiting	10	12.2%
Blood loss requiring transfusion	10	12.2%

The mean blood loss was found to be 500 ml and 10 patients required blood transfusion. Most of the patients requiring transfusion had pre-existing anemia. No patient went into refractory or persistence hypotension, seizures or loss of consciousness. Moreover no case required intubation for respiratory failure. Overall unilateral subarachnoid block was found to be a safe alternative to general anaesthesia in the patients undergoing simple or modified radical mastectomy.

Discussion

Unilateral spinal anaesthesia is found to be successfully performed with an adequate level of sensory block for surgeries of breast tumours. The technique was associated with a moderate degree of hemodynamic stability with very few patients

requiring additional sedation or analgesia. The main purpose of our study was to find out whether conventional technique using local anaesthesia will give the adequate sensory and motor blockade for the breast surgeries. Out of 90 patients 82 underwent surgeries for breast tumours under spinal anaesthesia without the need for additional anesthetic agent.

There are many studies which studied the effectiveness of spinal anaesthesia for breast surgeries but most of them used thoracic spinal anaesthesia at the level of D5. Ahmed Abdelal Ahmed Mahmud et al conducted a prospective study in which they performed a prospective feasibility trial of 25 patients undergoing breast surgeries under segmental thoracic spinal anaesthesia at T5 level with 1 ml plain bupivacaine (5 mg/ml) and 0.3 ml fentanyl (50 µg/ml). They

assessed the number of attempts required, paresthesia during needle insertion, sensory block level, need for supplemental analgesics or general anesthesia, and block-related complications. Hemodynamic as well as patient satisfaction were also recorded. At the end of their study they concluded that the segmental thoracic spinal anesthesia at T5 level in healthy patients undergoing breast surgery can be used successfully with minimal hemodynamic instability. However they recommended further studies involving larger number of patients before it can be recommended for routine use ^[16].

Similarly Elakany et al undertook the study to compare segmental thoracic spinal anaesthesia and general anaesthesia in patients undergoing unilateral mastectomy with axillary dissection. Forty patients were enrolled in this comparative study with inclusion criteria of ASA status I-III. Only those patients who had primary breast cancer without known extension beyond the breast and axillary nodes scheduled for unilateral mastectomy with axillary dissection were included in this study. Patients with ASA grade more than III and having metastasis were excluded from the study. The patients were divided into 2 groups. In 1 group patients received general anesthesia while in other group patients underwent surgery under segmental thoracic spinal anesthesia with bupivacaine and fentanyl at T5-T6 interspace. The authors recorded Intraoperative hemodynamic parameters, intraoperative complications, postoperative discharge time from post-anesthesia care unit (PACU), postoperative pain and analgesic consumption, postoperative adverse effects, and patient satisfaction with the anesthetic techniques. At the end of the study they concluded segmental thoracic spinal anesthesia to be having advantage over general anaesthesia. They recommended that segmental thoracic anaesthesia can be considered as a sole anesthetic in breast cancer surgery with axillary lymph node clearance ^[17].

One important concern while performing breast surgeries under spinal anaesthesia is the chances

of high level or total spinal anesthesia due to use of hyperbaric local anesthetic in a patient who is tilted head down to 20-30 degree for 5 to 10 minutes, but as seen in our study none of the patient required respiratory assistance or developed cardiac depression (only 3 cases required inj. atropine) due to higher level of blockade. It can be well demonstrated that in an average height patients (as per Indian women's average height) slow and controlled sensory blockade can be achieved with vigilantly monitoring the ascend of level of block. As the onset of block with local anesthetic inj.bupivacaine is slower compared to that of inj.lignocaine. Head tilt should be reduced once the desired level of block (T4-T2) is achieved in the operative side ^[18].

One of the important factors in success of any surgery is the operative ease created for the surgeons. A clear surgical field is of utmost importance and it can be achieved by good muscle relaxation and lesser blood loss in the procedure and spinal anaesthesia is also known for this. The issue of general anesthetic triggering recurrence of cancer due to its immunosuppressive effect is also a topic under evaluation which requires a control in the form of regional anesthesia not requiring general anesthetics can be provided with a kind of prospective study in which surgeries for breast cancer is performed under spinal anesthesia ^[19].

Lastly the issue of general anaesthesia causing spread of malignant breast disease needs to be addressed. It is a real possibility and many authors have dwelled into various aspects of this proposition. In a very interesting study Aristomenis et al examined the medical records of 129 consecutive patients who underwent mastectomy and axillary clearance for breast cancer over a period of 1 year. They found that paravertebral anesthesia and analgesia for breast cancer surgery reduces the risk of recurrence or metastasis during the initial years of follow up. They hypothesized that the process of surgery inducing profound neuroendocrine, metabolic and cytokine response was responsible for transient

preoperative inhibition of immune function which may cause dissemination of the cancer cells. They further concluded that regional anaesthesia is an important factor in preventing or attenuating the surgical stress response by blocking afferent neural transmission which was responsible for prevention of noxious afferent input from reaching the central nervous system and hence will cause less inhibition of immune function^[20].

Conclusion

Our study concludes that surgeries for breast tumors (Benign and Malignant) can be safely done under unilateral subarachnoid block using local anesthetic drugs. However more randomized controlled trials are required to recommend it as a routine practice.

Conflict of Interest: None

References:

1. Shulman LN, Willett W, Sievers A, Knaul FM. Breast Cancer in Developing Countries: Opportunities for Improved Survival. *Journal of Oncology*. 2010;2010:595167.
2. Malvia S, Bagadi SA, Dubey US, Saxena S. Epidemiology of breast cancer in Indian women. *Asia Pac J Clin Oncol*. 2017 Aug;13(4):289-295.
3. Bloom HJG, Richardson WW. Histological Grading and Prognosis in Breast Cancer: A Study of 1409 Cases of which 359 have been Followed for 15 Years. *British Journal of Cancer*. 1957;11(3):359-377.
4. Gürdal SÖ, Saraçoğlu GV, Oran EŞ, Yankol Y, Soybir GR. The effects of educational level on breast cancer awareness: a cross-sectional study in Turkey. *Asian Pac J Cancer Prev*. 2012;13(1):295-300.
5. Bleyer A, Baines C, Miller AB. Impact of screening mammography on breast cancer mortality. *Int J Cancer*. 2016 Apr 15;138(8):2003-12.
6. Fajdic J, Djurovic D, Gotovac N, Hrgovic Z. Criteria and Procedures for Breast Conserving Surgery. *Acta Informatica Medica*. 2013;21(1):16-19.
7. Singh P, Kumar A, Trikha A. Rural perspective about anesthesia and anesthesiologist: A cross-sectional study. *Journal of Anaesthesiology, Clinical Pharmacology*. 2013;29(2):228-234.
8. Ahmed Abdelaal Ahmed Mahmoud, Hazem Abdelwahab Hussein, Karim Girgis, Ahmed Mostafa Kamal, The novel use of spinal anesthesia at the mid-thoracic level: a feasibility study *Egypt J Cardiothor Anesth*, 8 (2014), pp. 21-26.
9. Lynch EP, Welch KJ, Carabuena JM, Eberlein TJ. Thoracic epidural anesthesia improves outcome after breast surgery. *Annals of Surgery*. 1995;222(5):663-669.
10. Fassoulaki A. Brachial plexus block for pain relief after modified radical mastectomy. *Anesth Analg*. 1982 Dec;61(12):986-987.
11. Dennison AR, Watkins RM, Ward ME, Lee EC. Simple mastectomy under local anaesthesia. *Ann R Coll Surg Engl*. 1985 Jul;67(4):243-244.
12. Fodale V, D'Arrigo MG, Triolo S, Mondello S, La Torre D. Anesthetic Techniques and Cancer Recurrence after Surgery. *The Scientific World Journal*. 2014;2014:328513
13. Divatia JV, Ambulkar R. Anesthesia and cancer recurrence: What is the evidence? *Journal of Anaesthesiology, Clinical Pharmacology*. 2014;30(2):147-150. doi:10.4103/0970-9185.129990.
14. Lin L, Liu C, Tan H, Ouyang H, Zhang Y, Zeng W. Anaesthetic technique may affect prognosis for ovarian serous adenocarcinoma: A retrospective analysis. *Br J Anaesth*. 2011;106:814-22.

15. Das J, Kumar S, Khanna S, Mehta Y. Are we causing the recurrence-impact of perioperative period on long-term cancer prognosis: Review of current evidence and practice. *Journal of Anaesthesiology, Clinical Pharmacology*. 2014;30(2):153-159.
16. Ahmed Abdelaal Ahmed Mahmouda, Hazem Abdelwahab Hussein, Karim Girgisb, Ahmed Mostafa Kamalb, Hesham Ahmed Nafady ; The novel use of spinal anesthesia at the mid-thoracic level: a feasibility study ., *Anesth Analg* 2000; 90:1402–1405.
17. Elakany MH, Abdelhamid SA. Segmental thoracic spinal has advantages over general anesthesia for breast cancer surgery. *Anesthesia, Essays and Researches*. 2013;7(3):390-395.
18. Miyabe M, Namiki A. The effect of head-down tilt on arterial blood pressure after spinal anesthesia. *Anesth Analg*. 1993 Mar;76(3):549-52.
19. Moller JF, Nikolajsen L, Rodt SA, Ronning H, Carlsson PS. Thoracic paravertebral block for breast cancer surgery: A randomized double-blind study. *Anesth Analg*. 2007;105:1848–51.
20. Salo M. Effects of anaesthesia and surgery on the immune response. *Acta Anaesthesiol Scand*. 1992 Apr;36(3):201-20.