



## High Resolution Computed Tomography in the Evaluation of Temporal Bone Cholesteatoma

Authors

**Seema .V<sup>1</sup>, Raini. K.P<sup>2</sup>, Suny Thomas<sup>3</sup>, Mini .M.V<sup>4</sup>, Elizabeth Daniel<sup>5</sup>**

<sup>1</sup>Junior resident in Radiodiagnosis, Govt Medical College, Thrissur, Kerala, India

<sup>2,4,5</sup>Assistant Professor in Radiodiagnosis, Govt Medical College, Thrissur, Kerala, India

<sup>3</sup>Additional Professor in Radiodiagnosis, Govt Medical College, Thrissur, Kerala, India

Corresponding Author

**Raini. K.P.**

Assistant Professor in Radiodiagnosis, Govt Medical College, Thrissur Kerala, India

Email: [rainisuresh@gmail.com](mailto:rainisuresh@gmail.com)

### Abstract

**Introduction:** High Resolution Computed Tomography (HRCT), a modification of routine CT, provides a direct visual window in the temporal bone providing minute structural details. Purpose of the present study was to evaluate the normal variations, pathological processes and their extent involving the temporal bone along with their complications on HRCT and to correlate these imaging findings surgically, wherever available.

**Methodology:** The prospective study included 50 patients who were referred to the radiology department with clinically suspected temporal bone or ear pathologies. After detailed clinical examination, the patients were subjected to high resolution computed tomography (HRCT) examination. The imaging findings were correlated with the surgical findings wherever available. The surgical findings were considered as final.

**Results:** From a total of 50 cases, 40% had cholesteatoma. The surgical and radiological findings showed a high level of sensitivity (95%) in the identification of cholesteatoma. HRCT provides a good sensitivity of 93.3% in the identification of changes to the ossicular chain despite the presence of surrounding soft tissue. HRCT was highly informative in identification of erosion of lateral semicircular canal. In diagnosis of facial canal dehiscence HRCT had a low sensitivity of 25%. In the evaluation of any congenital abnormality of the ear HRCT proved to be beneficial in depicting the anatomical details.

**Conclusion:** The clinical and radiological findings showed a high level sensitivity with intra operative findings as regards to the presence of cholesteatoma, changes of the ossicular chain and erosion of the lateral semicircular canal. HRCT findings, in the treatment of any congenital abnormality of the ear were a good guide to the surgeon for planning and management.

**Keywords:** High Resolution Computed Tomography, Temporal bone, Cholesteatoma, Mastoiditis.

### Introduction

The tympanic cavity is an air-containing space within the temporal bone, which communicates with the nasopharynx through the Eustachian tube and with the mastoid air cells by means of the tympanic antrum. It constitutes an extension of the upper respiratory tract and is subject to viral and bacterial

invasion through eustachian tube. Pathology of ear is the third most common reason of visiting an otorhinolaryngologist, with inflammatory conditions of the middle ear being a frequent reason to prescribe antibiotics and perform surgery in children and teenagers<sup>1</sup>.

Earlier, in majority of the cases, a diagnosis was made by clinical examination alone. However, with an increase in the prevalence of infective pathologies of the ear, it was suggested that the current approach to preventing and treating these conditions were not adequate. Therefore, especially in complicated and recurrent conditions, imaging plays an important role, as imaging findings may fundamentally influence the treatment<sup>2,3</sup>.

A major advance in diagnostic imaging has occurred with the introduction of High Resolution computed Tomography which have made it possible to obtain high quality images with exquisite demonstration of most normal temporal bone structures and numerous pathological processes. High resolution computed tomography provides excellent of bony land marks within the temporal bone, due to the temporal bone inherent contrast, its dense bone being surrounded by air of the tympanic cavity and mastoid air cells. It has also added whole new dimension to the temporal bone by allowing visualization of the of the tissue components within and adjacent to the temporal bone. Because high resolution computed tomography can assess this area with unprecedented accuracy, it has allowed better understanding of the aetiology, pathology, the disease course earlier detection of complications and treatment modality which has considerably reduced the morbidity and mortality pertaining to lesions of this region.

### **Aims & Objectives**

To assess the role of High Resolution Computer Tomography as the prime modality in the diagnosis and characterization of the temporal bone cholesteatoma

### **Materials and Methods**

The ethics committee of our institute approved this prospective study and an informed consent was taken from all patients included in it. The prospective study included 50 patients with clinically suspected temporal bone or ear pathologies seen at Govt. Medical College, Thrissur, Kerala. However patients with history of trauma

and those with known or detected neoplasm related to temporal bone were excluded.

All the patients underwent a detailed clinical ENT examination followed by HRCT temporal bone. They were evaluated with Multi-detector High Resolution Computed Tomography technique of inner ear in the SIEMENS SOMATOM EMOTION 16 CT machine. No financial burden was incurred on the patient.

Scout films are taken routinely in all patients before starting the scan. Scans were acquired in the helical mode to reduce motion artifacts. With the patient in supine position & slight extension of the head, axial projections were obtained by serial 1-2 mm thin sections of the temporal bone with the line joining the infra-orbital rim and external auditory meatus perpendicular to the table. Scanning parameters of 133 kV, 140 mAs, 1-2 mm section thickness, 0.5 mm collimation were taken. The images were reconstructed with a bone algorithm. Coronal and sagittal reformatting was done to a slice thickness of 0.75 mm. intravenous contrast was administered to study the hyper vascular lesions like glomus tumours, cerebellopontine angle masses, intracranial or extra cranial extension of middle ear diseases.

Each HRCT image were analysed for specific features relevant to the evaluation of pathologies of temporal bone and interpreted in detail to define: 1. The type, location and extent of lesion., 2. Bony erosions of middle ear walls. 3. The integrity of the ossicular chain, facial nerve canal and labyrinth. 4. Involvement of hidden area, mastoid air cell system. The final diagnosis was made by medical, per operative and histopathological examination. All pathology reports were reviewed. The findings of HRCT were correlated with medical response, per operative finding and histopathologic diagnosis.

### **Results**

Out of 50 included cases in the study, surgical exploration was done in 45 cases. Out of 50 cases studied, 32 cases (64%) were males, 18 (36%) females. In this study, the age range was 10-75. Seventeen patients (34%) belong to 21 -30 years of age group. The most common presenting symptom was ear discharge. The most common presenting

symptoms were otorrhoea 92%, head ache (84%), hearing loss(56%), otalgia (80%), vertigo/tinnitus (22%), facial weakness(20%), cerebellar sign(16%), and fever (34%).

Among the 50 cases, Patients with infection form the largest proportion of cases, finding of majority of cases were suggestive of cholesteatoma in (n=20) 40% followed by CSOM in (N=12) 24%, Acute mastoiditis in (n= 9)18%), malignant otitis externa in (n=3) 6 %, and malignant tumors in( n=6) 12%.

Infection was diagnosed in 44 patients on HRCT. Table: 1 shows distribution of infection. Out of which a/c mastoiditis was 9, CSOM were 12, cholesteatoma 20, and 3 was malignant otitis externa. Out of 12 HRCT diagnosed cases of CSOM 2 patients were found to have cholesteatoma with ossicular disruption on surgery and biopsy.1 patient on biopsy proved to be a case of paraganglioma of the middle ear.

**Table . 1:** Distribution of infection

Type of infection	Number	Percentage
Acute mastoiditis	9	20.45%
CSOM with mastoiditis	12	27.2%
Cholesteatoma	20	45.45%
Malignant external otitis	3	6.8%
Total	44	100%

HRCT diagnosis of cholesteatoma was made in 20 patient. On HRCT Bilateral ear involvement was seen in 10% cases while 90 % had unilateral ear involvement. HRCT diagnosis of cholesteatoma was made in 20 patients. 5 of the 20 cases were post operative cases. One of the patients had brain herniation as a complication of MRM. 3 of the rest were diagnosed to have cholesteatoma by HRCT, and 2 were proved to have cholesteatoma by biopsy. 1 had granulation tissue. There were 19 patients that HRCT diagnosed accurately. 1 patient was over diagnosed by HRCT. Scutum was eroded in 21 patients on HRCT (42%) and was intact in 29 patients (58%).

HRCT diagnosed facial canal dehiscence in 5 patients. 4 patients were under diagnosed by HRCT. Ossicular erosion was found in 34 patients on HRCT. The incus was the most frequently eroded ossicle, followed by the malleus and the stapes. Table.3 describes frequency of ossicular erosion in

HRCT. During surgery, ossicular erosion was found in 36 patients. Out of the 15 incus which were found at surgery to be eroded, 14 were demonstrable with the scan. Of the eroded 13 malleus, 12 were seen by scan, while all 8 cases of absent stapes were correctly predicted by imaging. Correlation between HRCT and intra operative findings in cholesteatoma, facial canal dehiscence and ossicular erosion is shown in Table. 2.

There were 3 patients had brain abscess as a complication of cholesteatoma, which was diagnosed by HRCT and confirmed by surgery. Table.3 shows complications in cholesteatoma. HRCT diagnosed congenital anomalies in 1 patient. There were 3 patients with surgically confirmed labyrinthine fistula. The lateral semicircular canal was found eroded in 3 (6%) cases and intact in 47 (94%) cases preoperatively. All 3 involved the lateral semicircular canal, and 1 had additional fistula of the superior semicircular canal. Out of the 9 cases with surgically confirmed facial canal dehiscence only 5 could be detected by the radiologist.

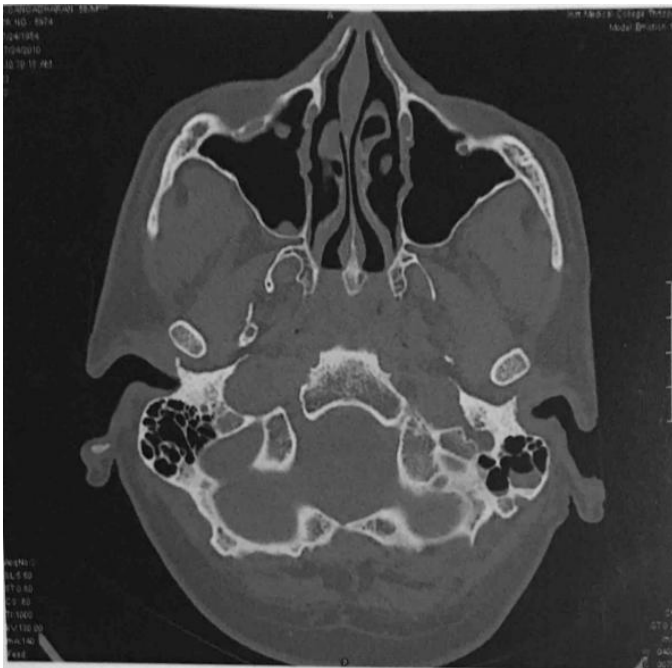
One of the patients with cholesteatoma had a high riding jugular bulb on the left side. This was confirmed during surgery. There was a 100% correlation between HRCT and intra-operative findings. 5 patients refused surgery.

**Table. 2** Comparison between HRCT and per operative findings with Sensitivity/ specificity of HRCT.

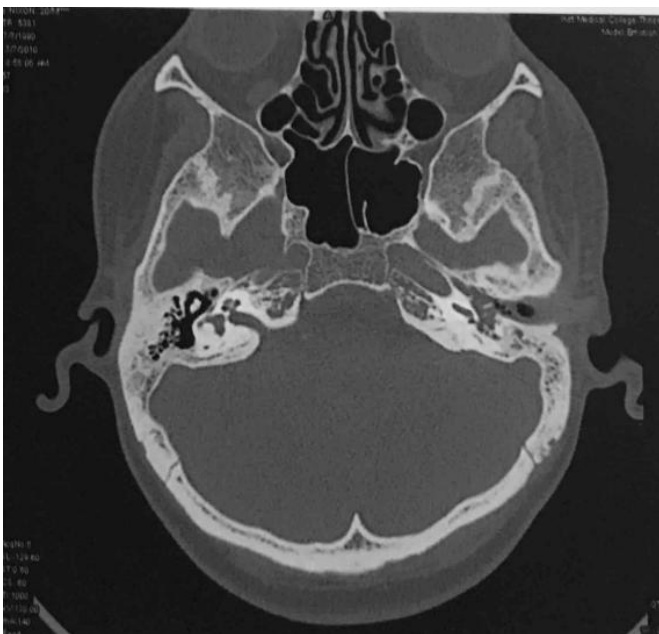HRCT Diagnosis (Positive in 'n' no. of patients)	Neg a-tive	Intraoperative findings (In 'n' no. of patients)		Sensitivity	Specificity
		Positive	Negative		
Cholesteatoma	20	19	1	1.00	0.05
Malleus erosion	12	13	4	0.923	1.00
Incus erosion	14	15	2	0.933	1.00
Stapes erosion	8	8	9	1.00	1.00
Mastoid opacification	17	17	0		
Tegmen tympani destruction	9	4	5	0.556	1.00
Jugular bulb	1( high riding)	1(high riding)			
Inner ear erosion	3	3	0		

**Table.3:** Complications in cholesteatoma

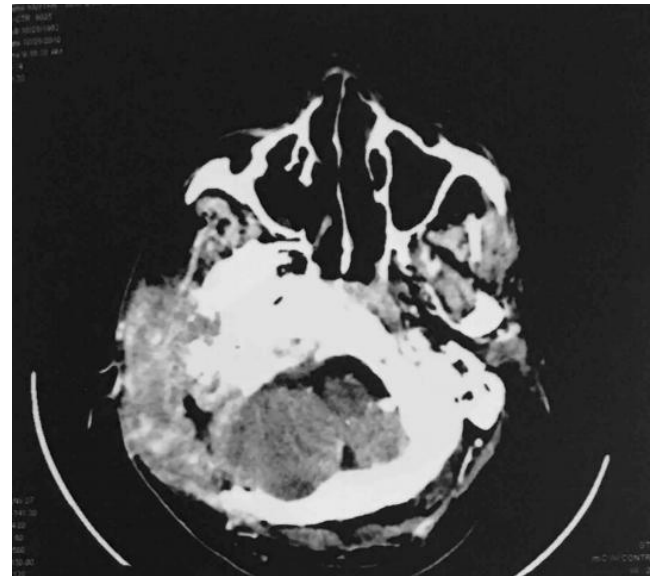
Complications	HRCT	Surgery
Brain abscess	3	3
Labrynthine fistula	3	3
Facial nerve canal erosion	5	9



**Figure. 1:** A case of left acute mastoiditis



**Figure. 2:** Left cholesteatoma with ossicular and facial canal erosion.



**Figure.3:** Giant cholesteatoma right side with extensive enhancing soft tissue component and bone destruction

**Discussion**

HRCT imaging is necessary for anatomic determination which acquiring an increasingly important role in the radiographic assessment of temporal bone. Radiographic assessment of temporal bone is difficult owing to complicated anatomical structure of middle and inner ear. This study is undertaken to develop a systemic method for evaluation of temporal bone as there are a variety of other imaging modalities. The lowest radiation dose to the lens, visualization of small bony structures, technical factors, ease of patient positioning, interpretation of the images and economical factors were all considered.

HRCT has the advantage of excellent topographic visualization, devoid of artifacts from superimposition of structures. It helps in accurate assessment of pathology prior to surgical exploration regarding location, extent and complication of the disease.

Patients with infection form the largest proportion of cases studied. The age range 10-75. 44 cases were studied and out of which a/c mastoiditis were 9, CSOM were 12, cholesteatoma 20 and 3 was malignant otitis externa. Study by GAS Lloyd et al (1980),<sup>4</sup> in 30 patients with CT showed infection as the 3rd most common cause of temporal bone lesion. 1st and 2nd were tumor and temporal bone trauma respectively. This variation could be due to the

increasing number of complications associated with the infections because of the late presentation of the disease in our study.

Out of the 12 HRCT diagnosed cases of CSOM 2 patients were found to have cholesteatoma with ossicular disruption on surgery and biopsy. 1 patient on biopsy was a case of paraganglioma<sup>5,6,7,8,9,10</sup> of the middle ear. The difficulty in diagnosis was mainly because of the lack of contrast as the patient refused contrast study for fear of allergic complications.

The incidence of cholesteatoma could not be estimated in the general population. In a study of the general population in Iowa, Horker and Koontz (1977) reported the overall incidence of cholesteatoma to be 6 per 1,00,000. It is however estimated that 15-25% of all cases of chronic suppurative otitis media are associated with cholesteatoma. Bilateral cholesteatoma are rare. 2 Cases were found to be bilateral.

Mohammad F. Maffee et al (1988)<sup>11</sup> studied cholesteatoma in 48 patients with computed tomography preoperatively. Operative reports of these patients were correlated with CT findings in all the patients. The hallmarks of cholesteatoma on CT scans are a soft tissue mass in attic and mastoid antrum associated with smooth bony expansion, scalloping of the mastoid, erosion of lateral wall of attic and erosion of ossicles. Comparing the imaging changes in the attic with finding at operation they found agreement between the radiographic interpretation and surgical finding in 90% of cases. NWC Chee TYT<sup>12</sup> a proposed study at the Singapore medical journal, 2001 regarding the value of pre operative HRCT in cholesteatoma surgery. The study assessed the usefulness of a pre operative HRCT in depicting the status of the middle ear structures in the presence of cholesteatoma. The surgical findings of 36 patients with cholesteatoma operated on by the first author were retrospectively compared with the CT findings reported on by the second author. The following were analyzed: diagnostic features of cholesteatoma on CT, status of the middle ear structures (ossicles, facial nerve canal, semicircular canal and tegmen tympani), and

presence of any anatomical variations and disease complications.

All cases had at least 1, and 30 cases (83.3%) had all, of the following radiological features: (a) a non-dependent tissue mass, (b) a location typical for cholesteatoma and (c) bony erosion. The radio-surgical agreement was excellent for the malleus (kappa statistics,  $k=0.83$ ), stapes (0.94) and semicircular canals (0.8), good for the incus (0.62) and tegmen (0.65), but poor for the facial nerve canal (0.3). Potential surgical hazards detected by the scans included: low lying dura, high jugular bulb, anterior lying sigmoid sinus, facial nerve dehiscence and other situations brought about by the destructive nature of the lesion. There is good to excellent radio-surgical correlation in cholesteatoma for most middle ear structures except for the integrity of the facial canal. In our study also the radio-surgical agreement was excellent for the stapes 1 and good for the incus 0.93 and malleus 0.92 but poor for the facial nerve canal 0.5.

P Dastidar, R Pertti<sup>13</sup> et al in 1997 studied the advantage of axial HRCT images and their reconstructions. Clinical diagnoses of chronic otitis media, mastoiditis, cholesteatoma and cochlear osteosclerosis in 10 patients were studied on a third generation CT scanner. The aim was to study the ability of this technique to identify several small structures of the temporal bone in various diseases. In all cases the finer structures of the temporal bone were identified in axial HRCT images. Axial HRCT, 2D multiplanar and MIP reconstructions of the temporal bone produce images with sufficient diagnostic quality in patients with hearing loss. In our study also the anatomic detailing of small temporal bone structures were excellent with the HRCT.

T Fuse, Y Tada, M Aoyagi<sup>14</sup> et al studied the CT detection of facial canal dehiscence and semicircular canal fistula with surgical correlation in 1996. The purpose of this study was to determine the accuracy of high resolution CT in the detection of facial canal dehiscence and semicircular canal fistula, the pre operative evaluation of both of which is clinically very important for ear surgery in 46 (75%) of the 61 patients. The data for the facial

canal revealed sensitivity of 66% and specificity of 84%. For semicircular canal fistula, in 59 (97%) of the 61 patients, the HRCT image based assessment and the surgical findings coincided. In our study HRCT has a sensitivity of 55% and 100% specificity of 100% and 100% in the assessment of facial canal and semicircular canals respectively.

5 post operative patients were studied: No. of patients with recurrence by HRCT were 3 but only 2 proved to have recurrence by surgery or biopsy. 1 patient had temporal lobe herniation 22 in to the middle ear cavity which was correctly diagnosed by HRCT and proved at surgery. Cases reported by Bowes AK et al. Brain herniation, space occupying lesions eroding the tegmen typani.

#### **Limitation of the use of HRCT in evaluation of chronic middle ear disease**

HRCT scans of chronically draining ears demonstrated abnormal soft tissue densities in the middle ear or mastoid. However, if this soft tissue mass was not associated with bone erosion, it was not possible to discern whether or not cholesteatoma was present.

Infrequently the soft tissue masses were proved to be granulation tissue or mucosal hypertrophy. Of greater predictive value in the diagnosis of cholesteatoma was the presence of abnormal soft tissue densities with bony erosion.

Evaluation of postoperative mastoid is yet difficult as the altered anatomy pose difficulty in diagnosing recurrent cholesteatoma from granulation tissue. Enhancing tumors like paraganglioma may be missed in the plain films.

#### **Conclusion**

The clinical and radiological findings showed a high level sensitivity with intraoperative findings as regards to the presence of cholesteatoma, changes of the ossicular chain and erosion of the lateral semicircular canal. HRCT findings, in the treatment of any congenital abnormality of the ear were a good guide to the surgeon for planning and management.

#### **References**

1. Brogan M, Chakeres DW. Computed tomography and magnetic resonance imaging of the normal anatomy of the temporal bone. *Semin Ultrasound CT MR*. 1989;10(10):178-94. [PubMed]
2. Howard JD, Elster AD, May JS. Temporal bone: Three dimensional CT. *Radiology*. 1990;177(2):427-30.[PubMed]
3. Chakeres DW, Augustyn MA. CT and MR Imaging of the Whole Body. 4th ed. Ohio: Mosby; 2003. Temporal bone. In: Haaga JR., Lanzieri CF, Gilkeson RC; pp. 495-512.
4. Lloyds GAS, Phelps PD and Du Boulay GH. High resolution computerized tomography of the petrous bone. *Brit. J. Radiology* 1980; 53: 631.
5. Chakeres DW and Lamasters D. Paragangliomas of the temporal bones: Highresolution CT studies. *Radiology* 1984; 150: 749.
6. Larson TC , Reese DF , Baker HL. Glomus tympanicum chemodectomas: Radiographic and clinical characteristics. *Radiology* 1987; 163: 801-806
7. Lo WWM, Solti-Bohman LG, Lambert PR. High-resolutionCT in the evaluation of glomus tumors of the temporal bone. *Radiology* 1984; 150: 737-742.
8. Chakers DW, Lamasters DL. Paranganliomas of the temporal bone: High resolution CT studies. *Radiology* 1984; 150: 749-753.
9. Gupta Vineet, Gupta Abhay, Sevarajan K. Chronic Suppurative Otitis Media Aerobic Micro biological study. *Ind J Otol* 1998; 4: 79-82.
10. Paparella MM, Kim CS . Mastoidectomy: Larangoscope 1977;87: 1977-88.
11. Mahammad F Mafee, Barry C Levin, Edward L Applebaum, Maio campos, and Charles F JAMES. Cholesteatoma of the middle ear and mastoid. *J. Otolaryngologic Clinics of North America* 1988May; 21 (2): 265-293.

12. The value of pre operative HRCT in cholesteatoma surgery. N W C Chee, T Y Tan Singapore medical journal.
13. The advantage of axial HRCT images and their reconstructions. P Dastidar, R Pertti et al in 1997 in AJR.
14. The CT detection of facial canal dehiscence and semicircular canal fistula with surgical correlation T Fuse, Y Tada, M Aoyagi et al in 1996 in radiology.