



## A Study on the Clinical and Radiologic Profile of Patients with Vascular Parkinsonism

Authors

**Dr Ranjit Sanu Watson<sup>1</sup>, Dr Raji .K.L<sup>2</sup>, Dr Sabarisree M<sup>3</sup>**

<sup>1</sup>Associate Professor in General Medicine, Govt Medical College, Kottayam

<sup>2</sup>Junior Resident in Cardiology, Govt Medical College, Trivandrum

<sup>3</sup>Associate Professor (CAP) in Orthopaedics, Govt Medical College, Trivandrum

### ABSTRACT

**Objectives:** *The purpose of this study is to analyse the clinical and neuroimaging features of patients with Vascular Parkinsonism*

**Background:** *Vascular Parkinsonism is a form of secondary Parkinsonism resulting from cerebrovascular disease. It is well known as a distinct entity, very different from the classical syndrome of Parkinson's disease where the etiology is considered to be a degenerative process affecting the nigrostriatal dopaminergic pathways. Vascular Parkinsonism is considered as a form of secondary Parkinsonism, secondary to single or multiple vascular ischemic lesions. This study analyses the clinical features, neuro-imaging findings and risk factors of Vascular Parkinsonism among stroke patients.*

**Materials and Methods:** *163 patients with past history of stroke, attending the Stroke Clinic, Department of Medicine, Government Medical College, Thiruvananthapuram, Kerala between April 2013 and March 2014 were studied for features of Vascular Parkinsonism. The patients were clinically examined and the neuroimaging findings were recorded.*

**Results:** *163 post-stroke patients were studied. Among them 40 patients (24.5%) had features of Vascular Parkinsonism. Patients with age above 70 years ( $p < 0.001$ ), multiple territory involvement, history of hypertension ( $p = 0.002$ ) were more prone to develop Vascular Parkinsonism. Stroke patients with Vascular Parkinsonism as compared to the tremor-dominant Parkinson's Disease had statistically significant difference in the clinical features like early gait abnormality ( $p < 0.001$ ), lower limb predominance with frequent falls ( $p < 0.001$ ), postural instability ( $p < 0.001$ ), dementia ( $p < 0.001$ ) and urinary incontinence.*

**Conclusions:** *Elderly stroke patients with multiple territory involvement and with hypertension are more likely to develop Vascular Parkinsonism and their clinical profile is quite distinct from that of idiopathic Parkinson's disease. Lower body parkinsonism and early involvement of gait leading to falls and early incontinence can be used as important differentiating features from the classical degenerative Parkinson's disease*

**Keywords:** *Vascular Parkinsonism, Stroke, Neuroimaging.*

### Introduction

Parkinsonian syndrome can be caused by ischemic cerebrovascular disease. This is called Vascular

Parkinsonism. It was earlier known as arteriosclerotic Parkinsonism<sup>1</sup>. Vascular Parkinsonism accounts for 3–5% of all patients suffering from

Parkinsonism<sup>3</sup>. It is clinicopathologically distinct from idiopathic Parkinson’s disease. Many cases diagnosed as idiopathic Parkinson’s disease in life were having the classical post-mortem features of a multi-infarct lacunar state and lacked the degenerative features<sup>2</sup>. It is important to differentiate these conditions because of the differences in their speed of progression, response to treatment, potential strategies for secondary prevention and prognosis<sup>2</sup>.

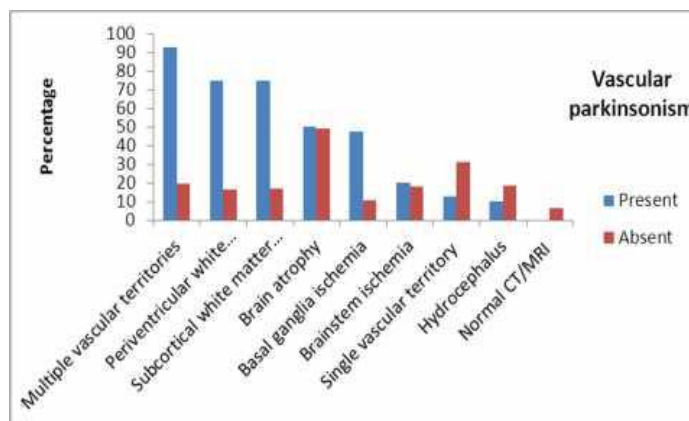
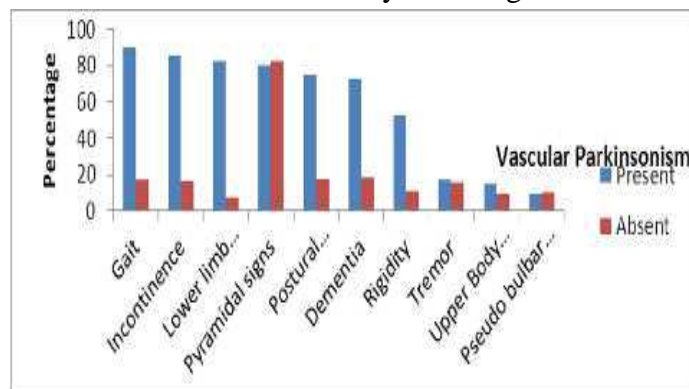
**Materials and Methods**

The study was conducted in patients attending the Stroke Clinic of Govt Medical College, Thiruvananthapuram, a tertiary care referral centre in Kerala. All patients included in the study had past history of single or multiple strokes. Acute stroke patients in the first month of stroke were excluded in the present study. The exclusion criteria included those patients with acute stroke, Idiopathic Parkinson’s Disease and Parkinson plus syndromes, those with past history of significant head injury, those in metabolic or toxic encephalopathy, drug induced Parkinsonism, Wilsons disease and those patients unwilling to participate in the study. A written informed consent was obtained from all participants after explaining the study design. The clinical features, risk factors and neuroimaging findings were assessed. The patients were clinically evaluated for the presence of tremor, rigidity, postural imbalance, bradykinesia, expressionless face, frequent falls, incontinence, dementia, slow gait, orthostatic hypotension and freezing phenomena. The results were evaluated based on the data obtained.

Data was analysed using SPSS version 17.0. Qualitative Data was expressed in its frequency and percentage. To compare different parameters, Chi square ( $\chi^2$ ) test was used for categorical variables. Odds ratio was calculated to assess the risk for each factor. For all statistical evaluations, probability value of <0.05 was considered significant.

**Results**

Of the 163 post stroke patients assessed, Parkinsonian features were detected in 40 patients (24.5%). Of the 40 patients with vascular Parkinsonism, 60% were above 70 years of age. 60% of patients were males. Hypertension was present in all the patients of vascular Parkinsonism. The major clinical features seen in Vascular Parkinsonism patients were early onset gait abnormality (90%), urinary incontinence (85%), frequent falls (82.5%), lower limb predominance (82.5%), and pyramidal signs (80%). The predominant neuroimaging findings in Vascular Parkinsonism patients were multiple vascular territories involvement (92.5%); periventricular white matter changes (75% and subcortical white matter changes (75%). Of the 163 stroke patients studied, 60% of those with Vascular Parkinsonism were above 70 years while only 26 % of those without Vascular Parkinsonism were above 70 years of age.



**Discussion**

60% of the patients with Vascular Parkinsonism were above 70 years of age. This is roughly in

accordance with study done by Vale et al <sup>5</sup>. In that study, mean age of the whole sample was 75.8±10.1 years. The higher incidence among the elderly population may be attributed to the higher incidence of cerebrovascular disease as age advances

In this study out of the 40 Vascular Parkinsonism patients, 60% of the patients were males. This is comparable to the study done by Vale et al<sup>5</sup>in which 58.8% of the patients were males. This higher incidence among males can be attributed to the higher risk of cerebrovascular disease and other vascular events among males.

Among the Vascular Parkinsonism patients studied, 60% were smokers.

Cigarette smoking is recognized as protective for Parkinson's disease <sup>6</sup>. However cigarette smoking was identified as a risk factor for Vascular Parkinsonism in a literature review done by Vale et al <sup>5</sup>. This is consistent with results obtained in this study. This association of smoking with Vascular Parkinsonism may be attributed to the higher risk of cerebrovascular disease among smokers.

In this study stage 2 hypertension was detected in 87.5% of Vascular Parkinsonism patients. This association is attributable to the higher risk of stroke among hypertensive patients. Hypertension has been reported as the most important risk factor for strokes and vascular Parkinsonism<sup>5</sup>. Diabetes mellitus was detected in 60% of the patients with Vascular Parkinsonism. This is comparable to the findings noted by Vale et al <sup>5</sup>. In their study, 47% of the Vascular Parkinsonism patients had diabetes mellitus. Diabetes mellitus has been reported as the third most common modifiable risk factor preceded by hypertension and heart disease <sup>5</sup>. Dyslipidaemia was present in 60% of the patients with vascular Parkinsonism. This is in accordance with study done by Vale et al<sup>5</sup>Dyslipidaemia has been noted as one of the important risk factor for developing vascular Parkinsonism. This association has been attributed to the higher incidence of cerebrovascular disease among patients with dyslipidaemia. Clinical

features noted among the Vascular Parkinsonism patients in decreasing order of frequency are gait abnormalities (90%), lower limb predominance (85%), frequent falls (82.5%), pyramidal signs (80%), postural instability (75%), dementia (72.5%), rigidity (52.5%), asymmetric involvement (30%), tremor (17.5%), upperlimb predominance (15%) and pseudo bulbar features (10%). This is comparable to findings noted in the study done by Winikates et al <sup>7</sup>. Winikates et al <sup>7</sup> observed gait abnormalities in 89.9%, postural instability in 72.5%, lower limb predominance in 59.4%, rigidity in 53.6%, asymmetric involvement in 50.7%, falls in 45%, tremor in 33.3%, pyramidal findings in 27.5%. The predominant features noted were gait abnormalities, postural instability, lower limb predominance, rigidity and asymmetric involvement.

Though Winikates et al observed pyramidal findings in only 27.5% of the patients, Yamanouchi et al <sup>8</sup> observed pyramidal findings in 63% of their Vascular Parkinson's patients. The other findings reported by Yamanouchi et al <sup>8</sup> were dementia in 71% and asymmetric involvement in 29% of vascular Parkinsonism patients. The neuroimaging findings observed in this study among patients with Vascular Parkinsonism in descending order of frequency were multiple territory involvement in 92.5%, periventricular and subcortical white matter changes in 75%, brain atrophy in 50%, basal ganglia ischemia in 47.5%, brainstem ischemia in 20%, hydrocephalus in 10%. This is comparable to findings observed by Winikates et al. <sup>7</sup> That study concluded that involvement of multiple vascular territories, periventricular white matter changes, subcortical ischemic white matter changes, and ischemia of the basal ganglia and brainstem were all significantly more common in the Vascular

Parkinsonism group compared with Parkinson's disease. Zijlmans et al <sup>9</sup> compared MRI findings in patients with Parkinson's disease, suspected vascular Parkinsonism, and in hypertensive controls. In that study it was found that a greater

volume of subcortical lesions and greater evidence of lesions of the subcortical grey nuclei in patients with suspected Vascular Parkinsonism compared with both idiopathic Parkinson's disease and hypertensive controls. According to the systematic review of Kalra et al. five of the 25 studies compared brain CT and/or MRI changes between Vascular Parkinsonism and Parkinson's disease. Patients with Vascular Parkinsonism were significantly more likely to have abnormal imaging, ranging from 90 to 100% compared with patients with Parkinson's disease, ranging from 12 to 43%. The main abnormalities included multiple territory infarcts, periventricular and subcortical white matter lesions and basal ganglia ischemic lesions.

#### **Comparison of sample patients with Vascular Parkinsonism and without Vascular Parkinsonism**

There was statistically significant difference in the following variables in stroke patients who developed Vascular Parkinsonism: age, hypertension, gait abnormality, lower limb predominance, postural instability, rigidity, dementia, urinary incontinence, multiple territory involvement, periventricular white matter changes, subcortical white matter changes, basal ganglia ischemia. Stroke patients above 70 years were more prone to develop Vascular Parkinsonism ( $p < 0.001$ ). This is comparable to the findings of Zijlmans et al.<sup>9</sup> In that study age above sixty years was found to be statistically associated with Vascular Parkinson disease. Statistically significant difference was noted in patients with hypertension ( $p = 0.002$ ). Hypertension has been reported to be the most common risk factor associated with Vascular Parkinsonism in most of the studies conducted previously. Few studies also reported hypertension to be present in almost 100% of the patients, similar to the findings reported in this study. Stroke patients with Vascular Parkinsonism had statistically significant difference in the clinical features like gait abnormality ( $p < 0.001$ ),

lower limb predominance ( $p < 0.001$ ), postural instability ( $p < 0.001$ ), rigidity ( $p < 0.001$ ), dementia ( $p < 0.001$ ) and urinary incontinence ( $p < 0.001$ ). This is similar to the findings reported in other studies<sup>7,8</sup>

The most common clinical features reported in these studies were gait abnormalities, postural instability, lower limb predominance, rigidity, asymmetric involvement and frequent falls.

Statistically significant difference was noted in the neuroimaging findings like multiple territory involvement ( $p < 0.001$ ), periventricular white matter changes, subcortical white matter changes ( $p < 0.001$ ), basal ganglia ischemia ( $p < 0.001$ ). This is comparable to the findings reported in other studies<sup>7,9</sup>

The most important neuroimaging findings reported in these studies were multiple vascular territory involvement, periventricular white matter changes, subcortical ischemic white matter changes, and ischemia of the basal ganglia and brainstem.

#### **Conclusions**

Majority of patients with Vascular Parkinsonism were above 70 years of age. Vascular Parkinsonism patients were predominantly males. The major clinical features seen in these patients were gait abnormality, urinary incontinence, frequent falls, lower limb predominance, and pyramidal signs. Stage 2 hypertension was present in all patients with Vascular Parkinsonism. The predominant neuroimaging findings of patients with Vascular Parkinsonism were multiple territory involvement, periventricular white matter changes, subcortical white matter changes and basal ganglia ischemia. Since stage 2 hypertension is definite risk factor for Vascular Parkinsonism, early detection and management of hypertension is vital for improving the quality of life in stroke patients.

#### **References**

1. Critchley M. Arteriosclerotic Parkinsonism. *Brain* 1929; 52: 23–83.

2. BhomrajThanvi, Nelson, Tom Robinson. Vascular parkinsonism—an important cause of parkinsonism in older people. *Age and Ageing* 2005; 34: 114–119
3. Foltynie T, Barker R, Brayne C. Vascular parkinsonism: a review of the precision and frequency of the diagnosis. *Neuroepidemiology* 2002; 21: 1–7.
4. The 7th report of the JNC on prevention, detection, evaluation and treatment of high blood pressure.
5. Vale T, Barbosa MT, Caramelli P, Cardoso F. Vascular Parkinsonism and cognitive impairment: literature review, Brazilian studies and case vignettes. *Dement Neuropsychol* 2012;6:137-144.
6. Baron JA. Cigarette smoking and Parkinson's disease. *Neurology* 1986; 36: 1490-6.
7. Winikates J, Jankovic J. Clinical correlates of vascular Parkinsonism. *Arch Neurol* 1999; 56: 98–102
8. Yamanouchi H, Nagura H. Neurological signs and frontal white matter lesions in vascular Parkinsonism. A clinic-pathologic study. *Stroke* 1997;28:965-969
9. Zijlmans J, Evans A, Fontes F, et al. [123I] FP-CIT spect study in Vascular Parkinsonism and Parkinson's disease. *MovDisord*2007;22:1278-1285
10. Kalra S, Grosset DG, Benamer HT. Differentiating Vascular Parkinsonism from idiopathic Parkinson's disease: a systematic review. *Movement Disorder* 2010;25:149-15