



An Evaluation of the Addition of Dexmedetomidine to Levobupivacaine for Axillary Block

Authors

Dr Sunita Khedkar, Bhalerao Pradnya, Vrushali Chavan

BJ Medical College
Corresponding Author
Bhalerao Pradnya

Abstract

Background: Axillary brachial plexus block is used for surgeries on forearm, hand and wrist. By adding α_2 receptor agonist to local anaesthetic drugs we can hastens the onset, duration, quality of sensory and motor block with prolong postoperative analgesia.

Aim: In this study, we studied the effects of adding dexmedetomidine to levobupivacaine for an axillary brachial plexus block.

Setting and Design: Patients of ASA grade I and II, age 18 to 60 years of either sex were enrolled in this prospective study. They were randomly allocated into two groups of thirty each by computerized method.

Methods and Material: Group L received 40 ml of 0.5% levobupivacaine + 1 ml Saline, and Group LD received 40 ml of 0.5% levobupivacaine + 1 μ g/kg dexmedetomidine.

Statistical analysis: The data was analysed using two independent sample t-tests, chi-square tests and Mann-Whitney U test as applicable.

Result: The onset of sensory and motor block was earlier in Group LD 8.09 \pm 0.48 min and 15.54 \pm 0.94 min as compared to Group L 10.94 \pm 0.85 min and 16.78 \pm 1.13 min ($p < 0.001$) respectively. The mean duration of sensory and motor blockade was 930 min and 810 min in Group LD and 680 min and 546 min in Group L ($P < 0.001$) respectively. The time to rescue analgesia was 1279.50 min in Group LD and 752 min in Group L ($P < 0.001$). More patients in group LD had excellent satisfaction than group L ($P = 0.008$).

Conclusions: Adding dexmedetomidine to levobupivacaine for an axillary brachial plexus block shortens both the sensory and motor block onset time, extends the duration of block and analgesia.

Keywords: axillary brachial plexus block, dexmedetomidine, levobupivacaine,

Introduction

Recently, the realization has grown that excellent post-operative pain relief can be provided easily and quickly with suitable local block. In the upper limb, regional anaesthesia may be used for procedures on the hand, forearm and elbow. There are various techniques to block the brachial plexus. The axillary approach is technically easy

and provides intense anaesthesia for forearm surgeries. As compare to other brachial plexus approaches, the axillary block has negligible risks of pneumothorax or phrenic nerve blockade.

Levobupivacaine is the S (-) enantiomer of racemic bupivacaine. It has less cardiotoxicity compared with bupivacaine. Dexmedetomidine is an α_2 receptor agonist that has more selectivity

than clonidine and has analgesic and sedative properties. Numerous studies have been conducted on the use of local anaesthetics agents with adjuvants such as clonidine, dexmedetomidine, tramadol for a brachial plexus block to improve the quality and duration of anaesthesia. Esmogluet et al^[1] and Kenan K et al^[2] studied on the effect of adding dexmedetomidine to levobupivacaine for an axillary brachial plexus block. In view of decreasing the dose of dexmedetomidine to reduce side effects such as bradycardia and hypotension. We thought that more studies on this issue are needed.

So, we studied the effects of adding dexmedetomidine to levobupivacaine for an axillary brachial plexus block by comparing the onset and duration of sensory and motor block, quality of block and time to postoperative rescue analgesia.

Materials and Methods

After the approval of the institutional ethical committee, the study was carried out during the period of March 2012 to August 2013. All patients of hand and forearm surgeries having physical status ASA I and II, age 18 to 60 yrs and of either sex selected for the study. Sixty patients were selected by computerized randomization and categorized into two groups 30 in each.

The patients on adrenoreceptor agonist or antagonist therapy, patient with hepatic, renal, cardiovascular, respiratory and CNS diseases, allergy to local anaesthetics, pre-existing peripheral neuropathy, massive trauma causing destruction of brachial plexus region, bleeding and coagulation disorders, pregnancy and local infection were excluded from the study.

Group L received 40 ml of 0.5% Levobupivacaine with 1 ml Saline and Group LD received 40 ml of 0.5% Levobupivacaine with 1µg /kg Dexmedetomidine.

Preoperative examination was done a day prior to surgery and written, informed consent was taken. The procedure was explained to the patient.

Intravenous (i.v.) line with 18 G cannula was secured and Ringer lactate solution started. Monitors like pulse oximeter, electrocardiogram (ECG), NIBP were attached. Baseline Pulse rate and blood pressure were taken. Premedication was given with inj. ondansetron 0.08 mg/kg, inj midazolam 0.03 mg/kg, inj pentazocin 0.3 mg/kg i.v. given 10 min before axillary the block.

We used Perivascular Technique for axillary block. In which, patient was lying supine with the arm abducted to about 90⁰, externally rotated and flexed at the elbow. Under all aseptic precaution, the axillary artery palpated and a finger was placed on it as high in the axilla as possible. A skin weal was raised superficial to the artery with 1% lignocaine and 22G one & half inch needle advanced slowly at about 30⁰ to the skin through the weal towards the side of the artery. Correct placement of the needle in the sheath was confirmed if the needle gently pulsates indicating close proximity to the artery. Needle was stabilized, aspirate to exclude intravascular placement of the needle then 1ml of test solution injected and observed for 1 min for possible intravascular placement of the needle. Then half of the study drug administered in 5ml increments following aspiration. The remaining half was injected at a second site just below the artery after relocalisation of brachial plexus. Needle was removed & gentle massage was given.

Intraoperatively the pulse rate, blood pressure, respiratory rate, Spo₂, and E.C.G. were monitored throughout.

The sensory blockade was evaluated by pin prick method. The Onset of Sensory blockade was defined as the time between the local anaesthetic administration & total abolition of pinprick response. It was evaluated at every 5 min for 30 min or until the onset of sensory blockade. The Duration of Sensory blockade was defined as the time between the local anaesthetic administration & the offset of paraesthesia. It was observed and time noted.

The Onset of motor blockade was defined as the time between the local anaesthetic administration

and total muscle paralysis of wrist & hand. It was evaluated at every 5 min for 30 min or until the onset of motor blockade. It was assessed by using a modification of Lovett's rating scale: 6 – Normal muscular force, 5 – Slightly reduced muscular force, 4 – Profound reduction of force, 3 – Slightly impaired mobility, 2 – Profound impaired mobility, 1 – Almost complete paralysis, 0 – Complete paralysis. The Duration of motor blockade was defined as the time between the local anesthetic administration and the recovery of motor blockade. It was observed and time noted. Post-operative analgesia assessed by Visual Analog Scale (VAS) 0-10. Intramuscular injection diclofenac 75mg was given postoperatively as rescue analgesia when the VAS >4. The time between onset of complete block to the time of first request for postoperative analgesia by patient was noted as duration of analgesia.

Patient's satisfaction was taken into consideration after brachial plexus block. Satisfaction was graded as Excellent, Good, Not Satisfactory.

All patients were observed for any complication like nausea, vomiting, bradycardia, hypotension and local anaesthetics toxicity.

Power analysis: The sample size of the patients was calculated by using population based formula. By exclusion and inclusion criteria and loss to follow up, we divided the patients by using simple computerized randomization in two independent groups. Power of the test for onset of motor block is 0.74. Power of test for onset of sensory block is 0.83.

Statistical analysis: Data analysis was done by using SPSS (statistical package for social science) Version 17.0. We have used two independent sample t-tests to find the significance between two groups for age, weight, onset of sensory and onset of motor block. Chi-square test used to find the significance between two groups sex, ASA grade, patient satisfaction grade.

Non-parametric test (Mann-Whitney U) was used to find the significance between duration of sensory and motor block and postoperative

analgesia. The P value <0.05 was considered as significant.

Results

Sixty patients were studied as two groups of 30 each. Group L was given levobupivacaine and Group LD was given levobupivacaine and dexmedetomidine for axillary brachial plexus block.

Both groups were comparable in terms of age, weight, sex and ASA grade. Average age of the patient was (39.13 + 11.36 years) in L group and (40.13 + 11.36 years) in LD group. Average weight of the patient was (56.40 ± 8.09 kg) in L group and (55.60 ± 8.09 kg) in LD group. The sex distribution and ASA distribution were comparable in both the groups.

As shown in [Figure 1] Group LD patients had early onset of sensory block (8.09 ± 0.48 min) than group L (10.94 ± 0.85 min.) ($P < 0.001$). As shown in [Figure 2] there was early onset of motor block in group LD (15.54 ± 0.94 min) than group L (16.78 ± 1.13 min) which was statistically significant ($P < 0.001$).

As shown in [Figure 3] the sensory duration of block was prolonged in group LD (930 min) than group L (680 min) ($P < 0.001$). As shown in [Figure 4] the duration of motor block was also prolonged in group LD (810 min) than in group L (546 min) ($P < 0.001$).

As shown in [Table 1] there is statistically significant difference between median duration of post-operative analgesia in group LD (1279.50 min) and group L (752.00min) ($P < 0.001$).

As shown in [Table 2] more patients in group LD have excellent satisfaction grade than group L ($P = 0.008$).

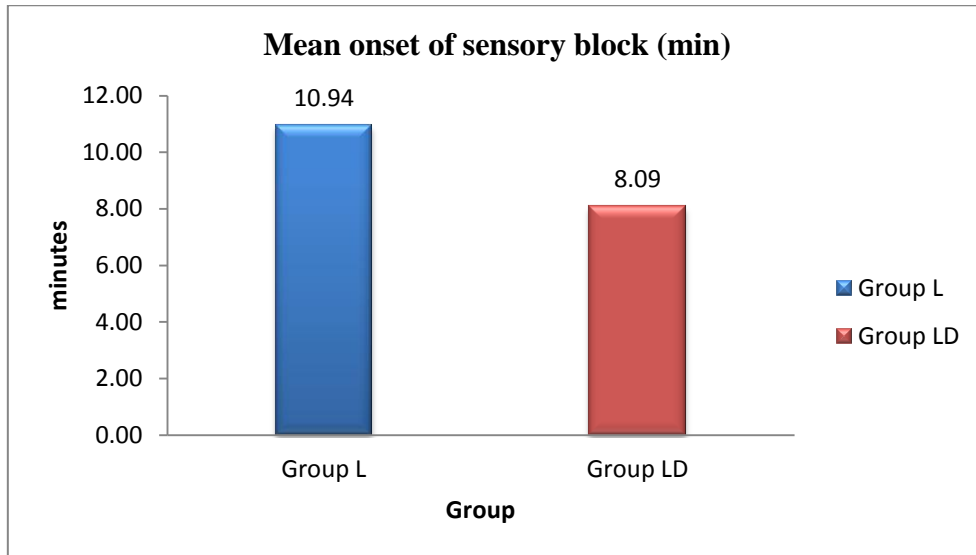


Figure 1: Onset of sensory blockade

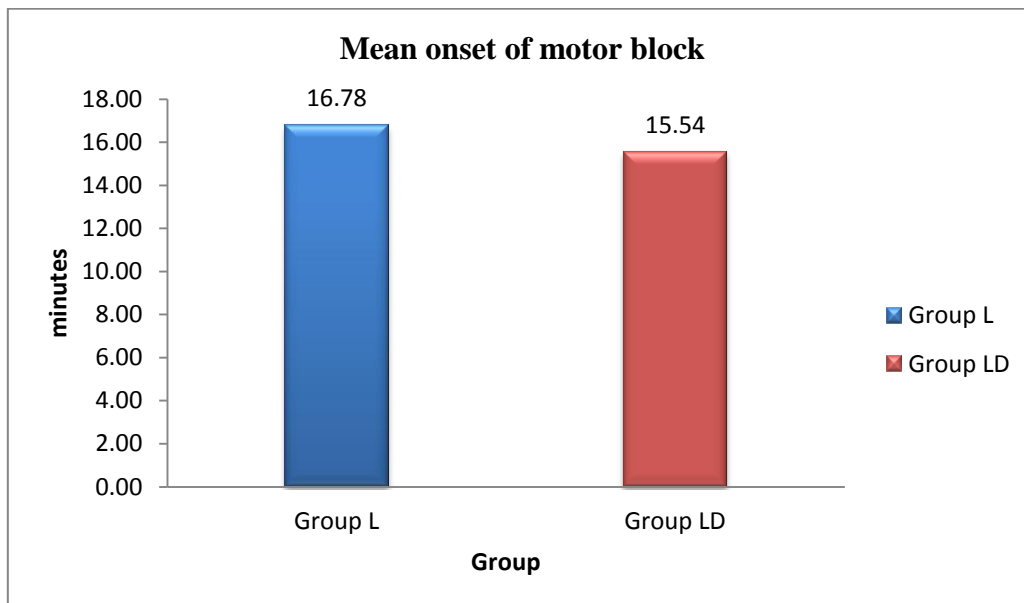


Figure 2: Onset of motor blockade

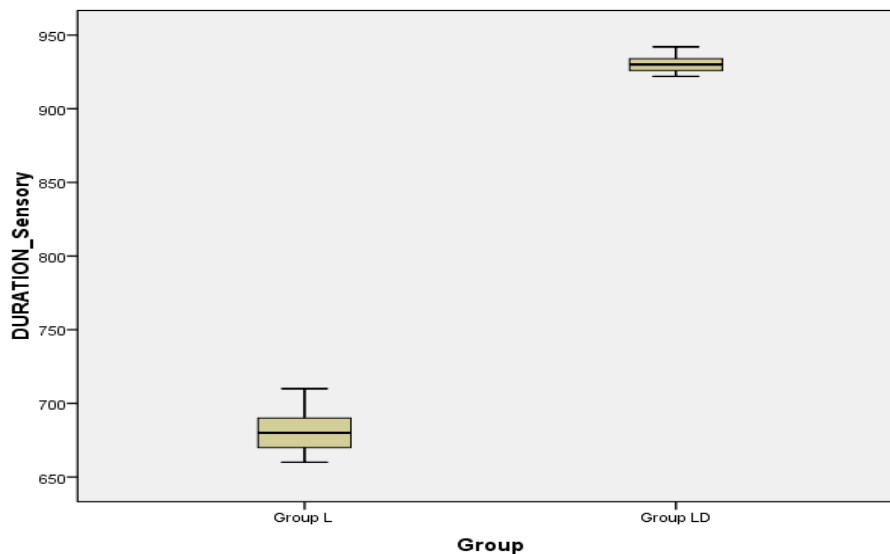


Figure 3: Comparison of duration of sensory blockade in minutes between two groups

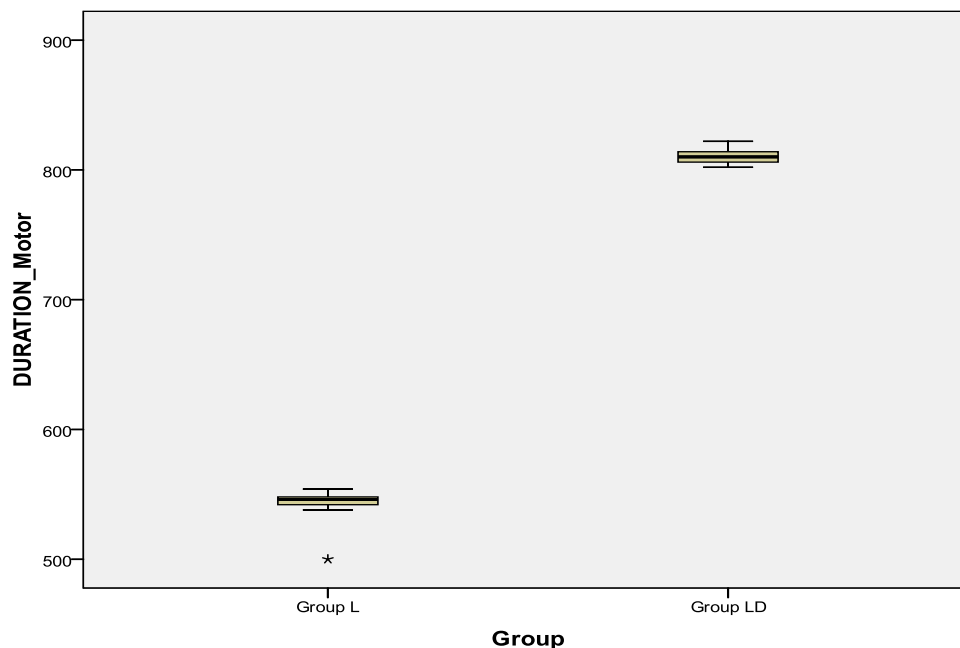


Figure 4: Comparison of Duration of motor blockade between two groups

Table 1: Comparison of duration of post-operative analgesia in group L and group LD.

Group	Median duration (minutes)	P*-value
Group L	752.00	< 0.001
Group LD	1279.50	

*sample t-test $P < 0.05$ is significant

Table 2: Distribution of patients in group L and group LD with respect to patients satisfaction grade

Patient satisfaction	Group		Total	P*-value
	Group L (n)	Group LD (n)		
Excellent	18	27	45	0.008
Good	5	3	8	
Not satisfied	7	0	7	
Total	30	30	60	

n = number of patients, *sample t-test $P < 0.05$ is significant

Table 3: Comparison of onset of sensory block in group L and group LD.

Group	Number of patients(n)	Onset of sensory block (min)		P*-value
		Mean	SD	
Group L	30	10.94	0.85	< 0.001
Group LD	30	8.09	0.48	

*sample t-test $P < 0.05$ is significant

Table No.4: Comparison of onset of motor block in group L and group LD

Group	Number of patients(n)	Onset of motor block (min)		P*-value
		Mean	SD	
Group L	30	16.78	1.13	< 0.001
Group LD	30	15.54	0.94	

*sample t-test $P < 0.05$ is significant

Table No.5: Comparison of duration of sensory block in group L and group LD

Group	Median duration(min)	P*-value
Group L	680	< 0.001
Group LD	930	

*sample t-test $P < 0.05$ is significant

Table No.6: Comparison of duration of motor block in group L and group LD

Group	Median duration(min)	P*-value
Group L	546	< 0.001
Group LD	810	

*sample t-test $P < 0.05$ is significant

Discussion

In this study we evaluated the effect of adding Dexmedetomidine with Levobupivacaine in axillary plexus block. We found that there was an early onset and significantly increased in duration of sensory and motor block by adding dexmedetomidine to levobupivacaine without any side effects.

To date, there has been an increasing use of some adjuncts for example opioids, α_2 -adrenoreceptor agonists to local anaesthetics to improve the quality of block in peripheral nerve blocks. It was suggested in some studies that the addition of α_2 agonists to local anaesthetics in peripheral nerve blocks improved the block quality and extended the block duration.^[1,3,4,5,6] The most probable mechanism of action include vasoconstriction, central analgesia and anti-inflammatory effects.^[1,4,5,6] Dexmedetomidine is a more selective α_2 agonist than clonidine. Many studies evaluated the effects of dexmedetomidine on neuroaxial and peripheral nerve blocks^[7,8,9] and dexmedetomidine was reported to be safe and effective in these studies.

To date, several studies evaluated the effects of clonidine in axillary brachial plexus blocks^[5,6,10,11,12,13] and found that clonidine had an improving effect on quality and duration of anaesthesia.

In our study, we compared Levobupivacaine with Levobupivacaine + Dexmedetomidine in axillary brachial plexus block. The concentration and volume of Levobupivacaine being same i.e. 0.5% and 40 ml in both groups and Dexmedetomidine

1 μ g/kg added in LD (Levobupivacaine+ Dexmedetomidine) group. The average age, weight, ASA distribution and sex distribution in two groups were comparable. With these doses we had stable hemodynamics.

Esmaoglu et al^[1] performed the study to evaluate the effects of dexmedetomidine in axillary brachial plexus blocks. They divided 60 patients who had been scheduled to undergo forearm and hand surgery using an axillary block into two groups. They administered 0.5% 40 ml levobupivacaine plus 1 ml saline solution in one group and 0.5% 40 ml levobupivacaine and 100 μ g dexmedetomidine in other group. Our study differs from their study in the dexmedetomidine dose that we used 1 μ g/kg dexmedetomidine. They found that adding dexmedetomidine to levobupivacaine shortens both the sensory and motor block onset time, extends the block duration, and the analgesia period. Similar results were obtained in our study.

Kenan K, et al^[2] showed that addition of dexmedetomidine to levobupivacaine in axillary brachial plexus block by using 39 ml of 0.5 % levobupivacaine +1 ml of normal saline in one group (L) and 39 ml of 0.5 % levobupivacaine + 1 ml of (1 μ g/kg dexmedetomidine + normal saline) in another group (LD) shortens the onset time of both sensory and motor block, prolongs the duration of block and the duration of postoperative analgesia

The another study done by Amany S, et al^[14] to test the efficacy of adding dexmedetomidine to

bupivacaine during placement of infraclavicular brachial plexus block by using 30 ml of 0.33% bupivacaine in group I and 30 ml of 0.33% bupivacaine with 0.75 µg/kg of dexmedetomidine in group II found that early onset of sensory and motor block and prolongation of postoperative analgesia.

The results found in above studies that the onset of sensory and motor block was earlier, and prolongation of duration and post-operative analgesia with addition of dexmedetomidine to regional block are nearly similar with our study.

No complications were found in both the groups of patients. Esmoğlu et al^[1] found that adding dexmedetomidine to levobupivacaine for an axillary brachial plexus block may lead to bradycardia. Bradycardia did not occur in our study.

In our study, the quality of block was excellent in 90% patient assessed by patient satisfaction score.

Limitation

The major limitations of our study are that we are not able to use the ultrasound guidance for block because of unavailability of equipment. Ultrasound- guided blocks could have helped in giving real time vision, reducing dose and volume of local anaesthetic drugs.

Conclusion

We would like to state that, the addition of dexmedetomidine to levobupivacaine leads to early onset and prolongation of sensory and motor block than the levobupivacaine alone. With dexmedetomidine not only quality of block was excellent but also prolongation of post operative analgesia with less complications can be obtained.

References

1. Esmoğlu A, Yegenoglu F, Akin A, Turk CY. Dexmedetomidine added to levobupivacaine prolongs axillary brachial plexus block. *Anesth Analg*.2010;111 (6):1548-51.
2. Kenan K, Iclal O, Cevdet D, Sinan G, Hayati O, Ulku K, et al. Effect of adding dexmedetomidine to levobupivacaine in axillary brachial plexus block. *Current Therapeutic Research* 2012;73 (3):103-111.
3. Kapral S, Gollmann G, Walzl B et al. Tramadol added to mepivacaine prolongs the duration of an axillary brachial plexus blockade. *Anesth Analg*1999;88:853.
4. Singelyn F, Gouverneur J, Robert A. A minimum dose of clonidine added to mepivacaine prolongs the duration of anaesthesia and analgesia after axillary brachial plexus block. *Anesth Analg* 1996;83: 1046–1050.
5. Singelyn F, Dangoisse M, Bartholomee S, Gouverneur J. Adding clonidine to mepivacaine prolongs the duration of anaesthesia and analgesia after brachial plexus block. *Reg Anesth* 1992;17:148–150.
6. Gaumann D, Forster A, Griessen M et al. Comparison between clonidine and epinephrine admixture to lidocaine in brachial plexus block . *Anesth Analg*1992;75:69–74.
7. Memis D, Turan A, Karamanlioglu B, Pamukcu Z, Kurt I. Adding dexmedetomidine to lidocaine for intravenous regional anaesthesia. *Anesth Analg*2004; 98(3):835-40.
8. Kanazi G, Aouad M , Jabbour-Khoury S, Aj Jassar M, Alameddine M, Al-Yaman R, Bulbul M, et.al. Effect of Small Dose Dexmedetomidine or Clonidine on the Characteristics of Bupivacaine-Spinal Block. *Acta Anaesthesiol Scand* 2005; 50:222-7.
9. Abosedira M . Adding clonidine or dexmedetomidine to lidocaine during Bier's block: a comparative study .*J M Sci* 2008;8:660–664.
10. Culebras X, Van Gessel E, Hoffmeyer P, Gamulin Z. Clonidine combined with a

long acting local anaesthetic does not prolong postoperative analgesia after brachial plexus block but does induce hemodynamic changes. *Anesth Analg*. 2001;92(1):199-204.

11. Sia S, Lepri A. Clonidine administered as an axillary block does not affect postoperative pain when given as the sole analgesic. *Anesth Analg* 1999;88:1109–1112.
12. Erlacher W, Schuschnig C, Orlicek F et al. The effects of clonidine on ropivacaine 0.75% in axillary perivascular brachial plexus block. *Acta Anaesthesiol Scand* 2000;44: 53–57.
13. Esmaglu, Mizrak A, Akin A et al. Addition of dexmedetomidine to lidocaine for intravenous regional anaesthesia. *Eur J Anaesthesiol* 2005;22: 447–451.
14. Amany S A, Khaled M M. “Ultrasound-guided single injection infraclavicular brachial plexus block using
15. bupivacaine alone or combined with dexmedetomidine for pain control in upper limb surgery: A prospective randomized controlled trial” . 2012 ; 6 (2) : 109-114.