



## Atypical Mooren's Ulcer: Our experience

Authors

**Ravi Kant Bamotra<sup>1</sup>, Vijayta Gupta<sup>2</sup>, Meenakshi Sindhu<sup>3</sup>, Ridham Nanda<sup>4</sup>**

<sup>1</sup>MS, SGHS hospital, advance eye care, Sector 77, Ajitgarh, Sohana, Sahibzada Ajit Singh Nagar, Punjab-140308

<sup>2</sup>MS, Senior Resident, Dept of Ophthalmology, Acharya Shri Chander College of Medical Sciences, Jammu

<sup>3</sup>MS, Department of Ophthalmology, AIIMS, Virbhadra Road, Rishikesh, Uttarakhand-249203

<sup>4</sup>MS, Senior Resident, Dept of Ophthalmology, Acharya Shri Chander College of Medical Sciences, Jammu

### ABSTRACT

**Objective:** To highlight variable clinical presentation and management of 4 cases of atypical Mooren's ulcer.

**Design:** Retrospective case series.

**Methods:** Patients presenting with bilateral peripheral ulcerative lesions were reviewed. A diagnosis of Mooren's ulcer was made after extensive medical and laboratory testing to rule out any infectious or systemic cause. All patients were managed medically or surgically according to their severity and response to treatment. Four patients between 20-40 years of age who were diagnosed as bilateral atypical Mooren's ulcer were included in the series.

**Results:** 2 cases responded well to medical management with systemic and topical steroids, cyclosporine eye drops and autologous serum. Two cases with aggressive course were managed surgically with conjunctival resection and amniotic membrane transplantation with cyanoacrylate glue application in areas of deep excavation. Systemic immunosuppressants were not required in any of the cases.

**Conclusion:** Atypical Mooren's ulcer presents as a bilateral disease in young patients and can progress very rapidly to perforation. However, with timely and appropriate treatment, the ulcers can be managed and eyes can be salvaged, minimizing the visual loss.

**Keywords:** Atypical Mooren's ulcer; Bilateral; Peripheral ulcerative keratitis; Autologous serum; Amniotic membrane; Cyanoacrylate glue.

### Introduction

Mooren's ulcer, by definition, is a rapidly progressive, painful peripheral ulcerative keratitis occurring in complete absence of any diagnosable systematic disorder that could be responsible for progressive destruction of the cornea, with no associated scleritis<sup>[1]</sup>. Corneal changes begin 2-3 mm from the limbus, first appearing as grey swellings that rapidly furrow, affecting the superficial one-third of the cornea and then

proceeding circumferentially and centrally over 4-12 months<sup>[2]</sup>. Mooren's ulcer was first described by Bowman in 1849 and then by McKenzie in 1854 as "Chronic serpiginous ulcer of cornea or ulcus rodens"<sup>[3,4]</sup>. Mooren's name, however, became attached to this rare disorder because of his publication of cases in 1863 and 1867<sup>[5]</sup>.

The exact pathophysiology of the ulcer remains uncertain, although evidences indicate that it is an autoimmune disease directed against a specific

target molecule in the corneal stroma resulting in its destruction by enzymes, probably triggered in genetically susceptible individual by one or several mechanisms<sup>[6,7]</sup>. Histopathologically, multiple types of immune cells including T cells, B cells, and macrophages are involved in the pathogenesis of Mooren ulcer [8]. Some authors have also reported association with chronic hepatitis C and helminthiasis<sup>[9,10]</sup>.

Wood and Kaufman reported 9 cases and concluded that there were two clinical types of Mooren's ulcer<sup>[11]</sup>. The first type, known as typical or benign Mooren's ulcer, is usually unilateral, with mild to moderate symptoms, generally responds well to medical and surgical treatment. This type is believed to occur in older patients. In contrast, the second type, known as atypical or malignant Mooren's ulcer, is bilateral, occurs in younger patients, with relatively more pain and generally shows a poor response to therapy.

In clinical practice, bilateral atypical Mooren's ulcer is a rare presentation and very few case series have been reported in literature. We are sharing a series of four cases of atypical Mooren's ulcer that presented to our cornea clinic over the last 5 years; which were treated according to the severity of their presentation.

### Case 1

A 30 year old male presented to cornea clinic complaining of pain, redness, watering, photophobia and diminished vision for last 4 months in left eye, with no history of trauma or ocular surgery preceding the complaints. Patient also gave history of similar episode in right eye during childhood. On examination, best corrected visual acuity (BCVA) was 6/18 in right eye and 6/36 in left eye. In right eye there was circumferential band of nebulomacular corneal opacity with thinning and vascularisation at few places suggestive of healed peripheral keratitis (Fig 1a). There was a circumferential peripheral ulcerative lesion on cornea located 1.5-2mm from limbus between 6 to 9'O clock with overhanging edges and marked thinning (50-60% of stroma) in left eye (Fig 1b).

Infiltrates were present from 10 to 12'O clock 2mm from limbus involving more than half of stromal thickness.

Patient was extensively investigated keeping peripheral ulcerative keratitis (PUK) as provisional diagnosis. All investigations including corneal scrapping culture, hemogram, urine routine and microscopy, stool examination, Fluorescent Treponemal Antibody (FTA-Abs), Rheumatoid Factor (RF), Hepatitis C virus, X- ray chest and joints, Anti-Neutrophil Cytoplasmic Antibody (ANCA), Antinuclear Antibody (ANA), were normal. So based on the clinical presentation and negative workup for underlying systemic diseases, a diagnosis of bilateral Mooren's ulcer was made and patient was started on oral and topical steroids along with autologous serum and cyclosporine eye drops. On poor response to the conservative treatment, conjunctival resection was done and amniotic membrane was transplanted after applying cyanoacrylate glue in areas of severe thinning (Fig 2a, 2b). The lesion healed gradually over 8-10 weeks (Fig 3). The steroids were slowly tapered off over 3 months.

### Case 2

A 38 year old female presented with similar complaints in both eyes for last 2 months. On examination, BCVA was 6/6 in right eye and 6/9 in left eye. Right eye showed a peripheral ulcerative lesion on cornea extending from 2 to 7 O'clock with overhanging edges with marked excavation and vascularisation (Fig 4a). In left eye, infiltrates were present from 2 to 4'O clock with a circumferential ring of opacity peripherally, sparing central cornea (Fig 4b).

After excluding systemic associations, a diagnosis of bilateral Mooren's ulcer was made and patient was started on oral and topical steroids. Topical antibiotics, cyclosporine, cycloplegics and autologous serum were also started. No surgical intervention was required in this case and the lesion healed well over 6 weeks.

**Case 3**

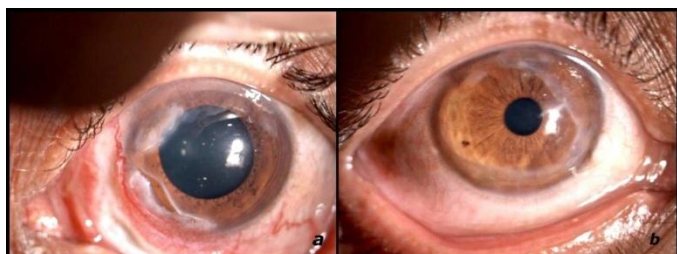A 22 year old male presented to cornea clinic complaining of pain, redness, photophobia and diminished vision for 8 months in both eyes. On examination, BCVA was 6/60 in right eye and 2/60 in left eye. Right eye showed a peripheral ulcerative corneal lesion extending from 3 to 9’O clock with thinning and vascularisation (Fig 5a). A similar lesion was present in left eye from 3 to 10’O clock with deep excavation with a 2x1.5mm descemetocoele (Fig 5b).

Patient was started on oral steroids with topical steroids, antibiotics, cyclosporine and autologous serum in both eyes. Conjunctival resection and amniotic membrane transplant was done in both eyes. Cyanoacrylate glue was also applied in left eye to the site of thinning. The lesion healed over 10 weeks with residual vascularised corneal opacities.

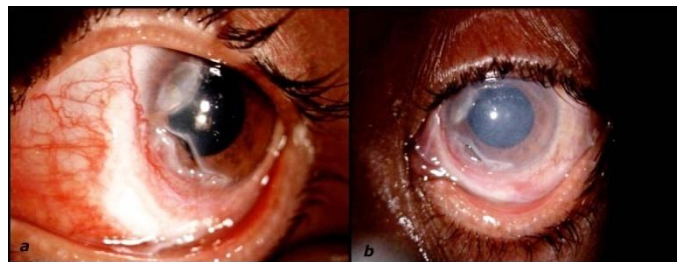**Case 4**

A 37 year old female presented with similar complains for last few days in right eye with history of similar episodes in left eye 5-6 years back. On examination, BCVA was 6/6 in both eyes. There was a peripheral ulcerative lesion on cornea from 10 to 1’O clock with infiltrates involving more than 50% of stroma (Fig 6a). In the left eye, there was a circumferential band of corneal opacity with vascularisation from 1 to 3 o’clock suggestive of healed lesions (Fig 6b).

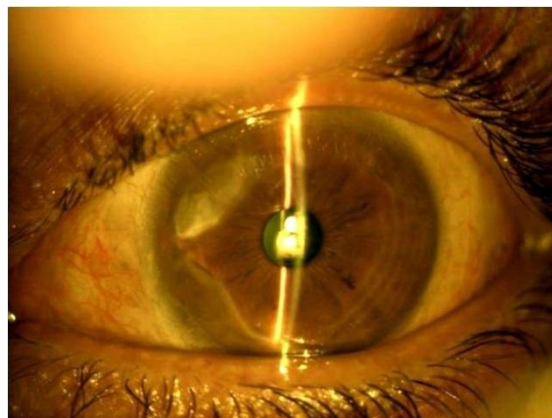
Diagnosis of bilateral Mooren’s ulcer was made after excluding systemic diseases, and patient was started on topical steroids, cyclosporine and lubricating eye drops. The lesion healed well in 3-4 weeks with the treatment.



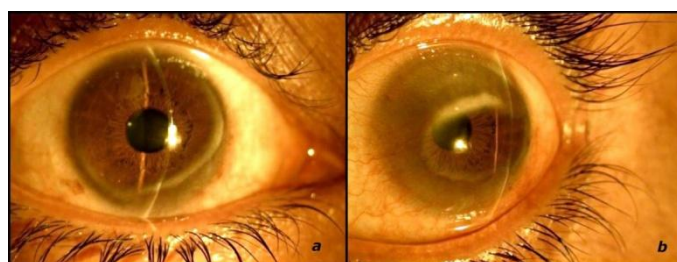
**Figure 1.a)** Healed lesion showing circumferential band of opacity in right eye. **b)** Peripheral ulceration with thinning from 6-9 o’clock in left eye



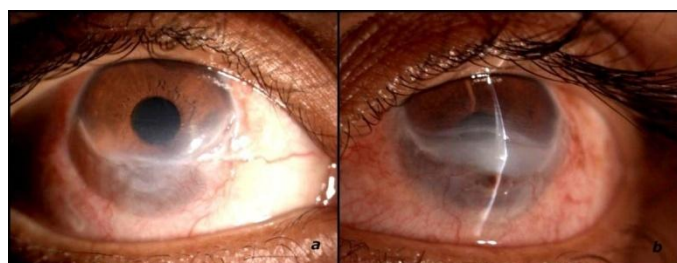**Figure 2.a)** left eye appearance after conjunctival resection. **b)** Post amniotic membrane transplantation.



**Figure 3.** Complete epithelialization with vascularisation in left eye after 10 weeks of treatment

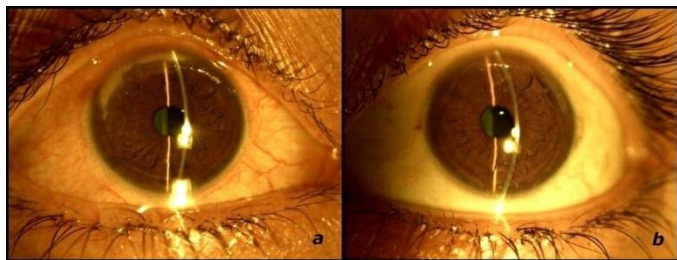


**Figure 4.a)** Peripheral ulceration from 2-7o’clock with thinning. **b)** Peripheral lesion from 2-4 o’clock with circumferential ring of opacity.



**Figure 5.a)** Inferior ulceration from 3-9 o’clock with thinning and vascularisation in right eye **b)** Inferior ulceration from 3-10 o’clock with thinning and decmetocoele.





**Figure 6.a)** Peripheral ulceration with infiltrates from 10-11 o'clock in right eye b) circumferential band of corneal opacity with vascularization from 1-3 o'clock in left eye.

### Discussion

Although the diagnosis of Mooren's is not difficult because of the characteristic clinical appearance; but the underlying systemic conditions causing PUK must be ruled out, since the entity is a diagnosis of exclusion. Mooren's ulcer is a rare disease; a study approximated the incidence to be 0.03% in China [2]. In our tertiary health center, we came across only 4 cases of bilateral atypical Mooren's ulcer in last 5 years. The disease is more common in the southern hemisphere including southern and Central Africa and India, indicating a genetic and/or geographic predisposition [12].

Studies from South India and China have suggested that patients tend to be affected between their sixth and eighth decades of life, with men being affected more than women by a ratio between 1.6:1 to 5:1 [13,14,15]. However, the epidemiology was different in African populations, as suggested by a study in Nigeria of 37 cases, where the disease mostly affected men in their 20s-30s [16]. Mathur et al described 14 cases of Mooren's ulcer in children less than 18 years of age [17]. Lewallen and Courtright, in their published series of Mooren's ulcer, suggest that younger patients had bilateral disease less frequently than older patients (1.5:1), regardless of race [18].

On literature review, we could not find any case series or review article related to atypical Mooren's ulcer. In this series, both males and females, two each, presented with bilateral atypical Mooren's ulcer with a relatively rapidly progressive course. All four patients of the series were young between 20-40 years of age.

Medical treatment of Mooren's ulcer consists of oral and topical corticosteroid, cyclosporine eye drops [2,1] and autologous serum [20,21]. If medical treatment does not control the inflammation, conjunctival resection can be performed. Surgical interventions can also include amniotic membrane transplant, lamellar keratoplasty, keratoepithelioplasty, delimiting keratotomy and conjunctival flap and patch grafts using periosteum or fascia lata [21,22,23]. Also modified LK, combined with immunosuppressive therapy, can effectively treat perforated Mooren's ulcer, with few complications. [24]. Brown et al (1975) reported 10 cases where limbal conjunctival excision was performed; eight of them healed and one developed recurring ulcers which then healed upon re-treatment [25]. Systemic immunosuppression using cyclophosphamide, azathioprine or methotrexate can be attempted if conjunctival resection yields no improvement [1]. Recently, lecithinated superoxide dismutase has also been found to decrease epithelial defect size in patients with sterile corneal ulcers that do not respond to conventional therapy [26]. Rituximab could be a new possibility for the treatment as it has completely cured 5 patients after conventional treatment failure [27].

In our series, topical steroids and cyclosporine were given in all the cases; autologous serum was required in 2 cases. Systemic steroids were given in 3 cases. Two cases with aggressive course were managed surgically with conjunctival resection and amniotic membrane transplantation with cyanoacrylate glue application in areas of deep excavation. Systemic immunosuppressants were not required in any of the four cases.

### Conclusion

Atypical Mooren's ulcer presents as a bilateral disease in young patients and can progress very rapidly to perforation. However, with timely and appropriate treatment, the ulcers can be managed and eyes can be salvaged, minimizing the visual loss.

**Acknowledgements/ Financial disclosure/ funding/support granting or sponsoring agencies:** Nothing to declare

### References

- Sangwan VS, Zafirakis P, Foster CS. Mooren's Ulcer: Current concepts in management. *Indian J Ophthalmol*, 1997; 45: 7-17.
- Chen J, Xie H, Wang Z, Yang B, Liu Z, Chen L, Gong X, Lin Y. Mooren's ulcer in China: A study of clinical characteristics and treatment. *Br J Ophthalmol*, 2000;84(11):1244-9.
- Bowman W: Case 12, p12 in the parts concerned in the operations of the eye (1849), cited by Nettleship E: Chronic Serpiginous Ulcer of the Cornea (Mooren's ulcer). *Trans Ophthalmol Soc UK*, 1902; 22:103-44.
- McKenzie H: *Disease of the Eye*, 1854; 631.
- Mooren A: *Ulcus Rodens. Ophthalmiatische Beobachtungen*. Berlin, A. Hirschwald, 1867; 107-110.
- Brown S. Mooren's ulcer: Histopathology and proteolytic enzymes of adjacent conjunctiva. *Br J Ophthalmol*, 1975; 59:670-4.
- Young R, Watson P. Light and electron microscopy of corneal melting syndrome (Mooren's Ulcer). *Br J Ophthalmol*, 1982; 66:341- 56.
- Lee HJ, Kim MK, Wee WR, Oh JY. Interplay of immune cells in Mooren ulcer. *Cornea*, 2015 Sep ;34(9) : 1164-7.
- Wilson S, Lee W, Murakami C, Weng J, Moninger GA. Mooren's type Hepatitis C virus-associated corneal ulceration. *Ophthalmology*, 1994; 101:736-45.
- Schanzlin D. Mooren's Ulceration. In: Smolin G, Thoft R, eds. *The cornea*. Boston. Little brown, 1994; 408-14.
- Wood T, Kaufman H. Mooren's ulcer. *Am J Ophthalmol*, 1971; 71:417-22.
- Taylor CJ, Smith SI, Morgan CH, Stephenson SF, Key T, Srinivasan M, Cunningham E Jr, Watson PG. HLA and Mooren's ulceration. *Br J Ophthalmol*, 2000; 84:72-5.
- Srinivasan M, Zegans ME, Zelefsky JR, Kundu A, Lietman T, Whitcher JP. Clinical characteristics of Mooren's ulcer in South India. *Br J Ophthalmol*, 2007; 91:570-5.
- Zegans M, Srinivasan M, McHugh T. Mooren Ulcer in South India: serology and clinical risk factors. *Am J Ophthalmol*, 1999; 128: 205-10.
- Li X, Wang L, Dustin L, Wei Q. Age distribution of various corneal diseases in China by histopathological examination of 3112 surgical specimens. *Invest Ophthalmol Vis Sci*, 2014; 55(5):3022-8.
- Kietzman B. Mooren's ulcer in Nigeria. *Am J Ophthalmol*, 1968;65(5):679-85
- Mathur A, Ashar J, Sangwan V. Mooren's ulcer in children. *Br J Ophthalmol*, 2012 June; 96(6): 796-800.
- Lewallen S, Courtright P: Problems with current concepts of the epidemiology of Mooren's corneal ulcer. *Ann Ophthalmol*, 1990; 22:52-5.
- Tandon R, Chawla B, Verma K, Sharma N, Titiyal JS. Outcome of treatment of mooren ulcer with topical cyclosporine A 2%. *Cornea*, 2008; 27(8):859-61.
- Mavrakanas NA, Kiel R, Dosso AA. Autologous serum application in the treatment of Mooren's ulcer. *Klin Monbl Augenheilkd*, 2007; 224(4):300-2.
- Lavaju P, Sharma M, Sharma A, Chettri S. Use of amniotic membrane and autologous serum eye drops in Mooren's ulcer. *Nepal J Ophthalmol*, 2013; 5:120-3.

22. Ngan ND, Chau HT. Amniotic membrane transplantation for Mooren's ulcer. *Clin Experiment Ophthalmol*, 2011; 13(5):386-92.
23. Alhassan MB, Rabiou M, Agbabiaka IO. Interventions for Mooren's ulcer. *Cochrane Database Syst Rev*, 2014; 1:CD006131.
24. Liu J, Shi W, Li S, Gao H, Wang T. Modified lamellar keratoplasty and immunosuppressive therapy guided by in vivo confocal microscopy for perforated Mooren's ulcer. *Br J Ophthalmol*. 2015 Jun;99(6):778-83
25. Brown SI. Mooren's ulcer: treatment by conjunctival excision. *Br J Ophthalmol*, 1975; 59(11):675-82.
26. Shimmura S., Igarashi R., Yaguchi H., Ohashi Y., Shimazaki J., Tsubota K. Lecithin-bound superoxide dismutase in the treatment of noninfectious corneal ulcers. *Am J Ophthalmol*, 2003; 135(5): 613-19.
27. Guindolet D, Reynaud C, Clavel G. Management of severe and refractory Mooren's ulcers with rituximab. *Br J Ophthalmol*. 2017 Apr;101(4):418-422