



Hair Topical Cream Containing Oxidizing Agent Causing Sudden Bilateral Sensorineural Hearing Loss

Authors

M.S Thayalen Savarathanam¹, Wan Emelda Wan Mohamad¹, Irfan Mohamad²

¹Department of Otorhinolaryngology, Hospital Sultanah Nora Ismail, Jalan Kurma 83000, Batu Pahat, Johor, Malaysia

²Department of Otorhinolaryngology-Head & Neck Surgery, School of Medical Sciences, Universiti Sains Malaysia Health Campus, 16150 Kota Bharu, Kelantan, Malaysia

ABSTRACT

Ingestion of bromate intoxication is known to cause ototoxicity and other life threatening condition such as central nervous system depression, acute renal failure, hemolytic anemia and gastrointestinal upset. Most of these manifestations are reversible, with the exception of kidney injury and deafness. We hereby present a case of 38-year-old female that develop sudden onset bilateral hearing loss with acute kidney injury after applying hair permanent wave cream. The renal function successfully recovered with hemodialysis. The hearing loss was persistent despite of trial 2 weeks systemic steroid.

Keywords: sodium bromate, hearing loss, renal failure.

INTRODUCTION

Sodium bromate (NaBrO_3), or also known as bromic acid, sodium salt and sodium bromate (V), is composed of inorganic component, which act as strong oxidizing agents. It is a colorless and odorless crystal. It is commonly used as hair permanent wave neutralizers, reagents of printing or dyeing and other chemical processes ^[1,2,3,4]

Acute symptoms following accidental or suicidal ingestion of sodium bromate are severe gastrointestinal irritation (vomiting, pain, diarrhea) and the central nervous system depression (lethargy, hypotension, hypotonicity, loss of reflexes), oliguric or non-oliguric acute kidney injury, hemolytic anemia (from intravascular hemolysis) and deafness. ^[1,5]

These effects are usually reversible. Renal function generally returns after 5-10 days of a

successful medical treatment. However hearing impairment following intoxication are normally worsening and irreversible. Hearing loss in this condition is usually common.

CASE REPORT

A 38-year-old woman was referred for sudden onset progressive bilateral hearing loss. It was associated with nausea, vomiting and spinning sensation. Further history noted that patient had slept overnight with the hair permanent wave cream prior to the symptoms.

On general examination, patient looked depressed and unable to respond to questions. Otosopic examination bilateral ears shows normal external auditory ear canal and tympanic membrane. Rinne and Weber test not applicable in view of patient unable to appreciate any sound.

Pure tone audiometry (PTA) showed bilateral profound hearing loss (Fig 1). The Distortion Product Otoacoustic Emissions (DPOAE) failed for both ears. The brainstem evoked response (BSER) done showed no response.

She was diagnosed as having bromate-induced sudden profound sensorineural hearing loss (SNHL). Trial of systemic steroid was administered with tapering doses for 2 weeks however no respond (Fig 2). The hearing impairment persisted after 6 months of follow up (Fig 3) and hearing aid was prescribed.

Following this bromate application also, she developed nausea, vomiting and abdominal pain. She was managed medically as rapidly progressive glomerulonephritis in view of worsening urea to creatinine level ratio.

Haemodialysis was done multiple times during admission. The renal biopsy showed bilateral parenchymal disease with no evidence of obstructive neuropathy. She was discharged after 2 weeks of hospitalization with improvement of her kidney function.

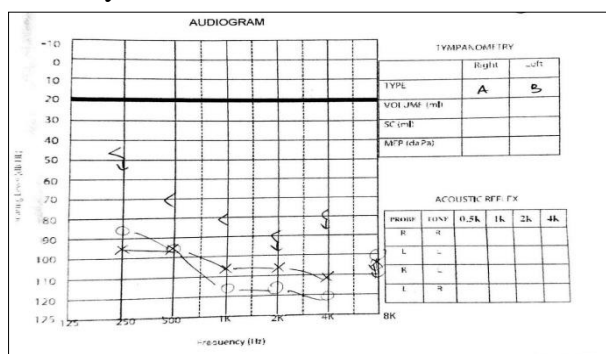


FIGURE 1: PTA on Day 1 Shows bilateral profound SNHL prior to starting steroid therapy.

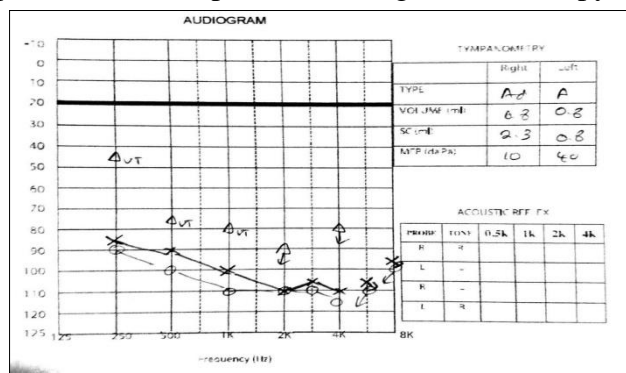


FIGURE 2: PTA on Day 3, after completing IV steroid shows no improvement. Still showing bilateral profound SNHL

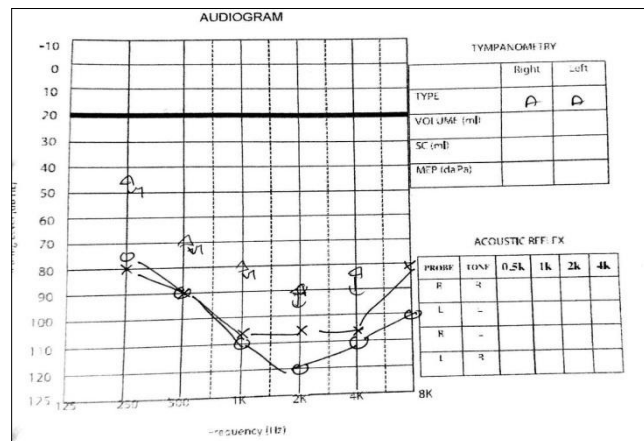


FIGURE 3: PTA repeated after 6 month, shows bilateral profound SNHL indicating no improvement

DISCUSSION

Delayed hearing impairment diagnosis after bromate intoxication may due to other life threatening condition such as acute kidney injury, severe gastrointestinal irritation and central nervous system depression that require emergency management. [1, 6, 7]

Generally, treatment for bromate intoxication is involving gastric lavage, renal replacement therapy and specific therapies intended to remove the unabsorbed bromate as possible. The dialysis should be done within a few hours of ingestion. [1,8]

In our case, this patient was referred after a day of admission in medical ward and hearing loss was diagnosed. Normally, the onset of hearing loss following bromate intoxication is rapid, occurring within 4-16 hours of ingestion [1,5]. The hearing loss is usually sensorineural in type with degree severe to profound and mostly irreversible.

Bromate ototoxicity occurs because of its inorganic component, the strong oxidizing agent. This salt is very biostable and easily able to cross the cellular biologic membranes to cause intracellular toxicity [9]. Evidence of hair cell degeneration, severe edema of the stria vascularis were demonstrated in animal study, following injection of perilymphatic cochlea of sodium bromated to guinea pigs. Histologically noted this due to decreased in enzyme activities leads to damage of these structures [7].

The other possibility of bromate ototoxicity is due to action on the stria vascularis causes breakdown of the endolymph-perilymph barriers [7].

To our knowledge, there has been several case reports of sodium bromate intoxication following bromated-ingestion. However, in our case, hearing loss and acute kidney injury was diagnosed after local application of bromate.

In this case after 6 months follow up with no recovery of hearing, hearing aid was applied and patient show a good response. Monitoring of hearing level is needed and cochlear implant may be useful in patients that have profound sensorineural hearing loss due to sodium bromate intoxication. [1]

CONCLUSION

Sodium bromate toxicity may cause acute irreversible sensorineural hearing loss. Emergency therapeutic measures should be taken as soon as possible to prevent severe intoxication and its sequelae.

REFERENCES

1. Tae-Ho Eom, Sungsu Lee, Hyong-Ho Cho, Yong-Beom Cho. A Case of Cochlear Implantation in Bromate-Induced Bilateral Sudden Deafness. *J Audiol Otol.* 2015;19(1):51-3.
2. Sashiyama H, Irie Y, Ohtake Y, et al. Acute renal failure and hearing loss due to sodium bromate poisoning: a case report and review of the literature. *Clin Nephrol* 2002;58:455-7.
3. Robert Lichtenberg, W. Patrick Zeller, Robert Gatson, R. Morrison Hurley. Bromate poisoning. *The Journal Of Pediatrics.* 1989; 114(5):891-4.
4. De Vriese A, Vanholder R, Lameire N. Severe acute renal failure due to bromated intoxication: report of a case and discussion of management guidelines based on a review of the literature. *Nephrol Dial Transplant* 1997;12(1):204-9.

5. Campbell KC1. Bromate-induced ototoxicity. *Toxicology.* 2006;221(2-3):205-11.
6. Oh SH , Lee HY , Chung SH , Kim CJ , Choi IJ. Acute renal failure due to potassium bromate poisoning. *Yonsei Medical Journal* 1980;21(2):106-9.
7. Matsumoto I, Morizono T, Paparella MM. Hearing loss following potassium bromate: Two case reports. *Otolaryngol Head Neck Surg* 1980;88:625-9.
8. Haruhito A. Uchida, Hitoshi Sugiyama, Sadahide Kanehisa et al. An elderly patient with severe acute renal failure due to sodium bromate intoxication. *Internal Medicine* 2006;45(3):151-4.
9. Dong Hwan Ryu, Kyung Ae Jang, Seok Min Kim, Jong Won Park, Jun Young Do, Kyung Woo Yoon. Acute kidney injury due to sodium bromate intoxication: a report of two cases. *Korean J Intern Med* 2011;26:463-5.