



Congenital Heart Disease (Atrial Septal Defect) With Rheumatic Heart Disease (Mitral Regurgitation)-A Rare Association

Authors

Nasreen Ali¹, Sunil Kumar Agarwalla²

¹Junior Resident, ²Associate Professor

Department of Pediatrics, M.K.C.G Medical College, Berhampur, Ganjam, Odisha-760004, India

ABSTRACT

Mitral regurgitation (MR) associated with secundum atrial septal defect could exist as an coexistent lesion or as the result of hemodynamic change occurred in secundum atrial septal defect. The etiologies are rheumatic valve, prolapsed anterior leaflet, congenital abnormality, specific pathology complex, and chronic infective endocarditis.

Here we report a case of 13 year old female child who was admitted to paediatric emergency department of MKCG medical college with complains of fast breathing and respiratory difficulty since last 7 days. On examination, there was pedal edema and murmur was heard at aortic and mitral area. On further investigations it was confirmed to be a case of Atrial septal defect (ASD) with Rheumatic heart disease (RHD).

Like in Lutembacher syndrome a combination of congenital ASD and acquired almost always rheumatic mitral stenosis, we propose that this combination of congenital ASD with MR due to rheumatic origin should be recognized with a name.

Keywords: rheumatic valve, prolapsed anterior leaflet, congenital abnormality, specific pathology complex, chronic infective endocarditis.

INTRODUCTION

Mitral regurgitation associated with secundum atrial septal defect is not uncommon. Its incidence ranged from 4% to 9.1%.^[1] The etiologies are as follows: rheumatic valve, prolapsed anterior leaflet, congenital abnormality, specific pathology complex, and chronic infective endocarditis^[2-5].

The causes of mitral regurgitation associated with secundum atrial septal defect can be classified into extrinsic and intrinsic factors. The extrinsic factors maybe the coexistent disease such as rheumatic valve disease or infective endocarditis which are also common disease in the developing

country. For the intrinsic factors, there were many evidences from the literatures that secundum atrial septal defect itself could give rise to mitral regurgitation. The incidence of mitral valve prolapse in patients with atrial septal defect has been reported for a several decades.

CASE REPORT

A 13 year old girl was admitted to paediatric emergency of MKCG with complains of fast breathing and respiratory distress for last 7 days. The child was born out of non-consanguinous marriage by normal vaginal delivery. The child

had attained all developmental milestones at right time and there was no history of sore throat or joint pain previously. On examination, the child was tachypnoeic, respiratory rate was 56/min. Heart rate was 60/min and regularly irregular and all peripheral pulses were palpable. There was engorgement of neck veins lateral to sternocleidomastoid muscle, precordial bulge and an epigastric pulsation was visible. There was B/L pitting edema. On palpation, there was para sternal heaving of grade 2 and on auscultation, two systolic murmurs were heard one at the apex and other at the pulmonary area which was of grade 3/6. There was hepatomegaly of 7 cm below the right costal margin. Because of the age group and findings, a provisional diagnosis of RHD with MR and TR in failure with superimposed carditis was made. On doing chest radiography there was cardiomegaly, ECG showed right ventricular hypertrophy. ECHO cardiography, it was found to be congenital ASD with MR, TR with pericardial effusion and mitral valve thickening. High

ESR,CRP and ASO titre with pericardial effusion pointed towards rheumatic origin.

The child improved with bed rest, oxygen, iv ceftriaxone, oral steroids and diuretics. She was given intra muscular long acting penicillin for prophylaxis and was advised for surgical correction.

Fig 1 Chest Radiography Showing Cardiomegaly

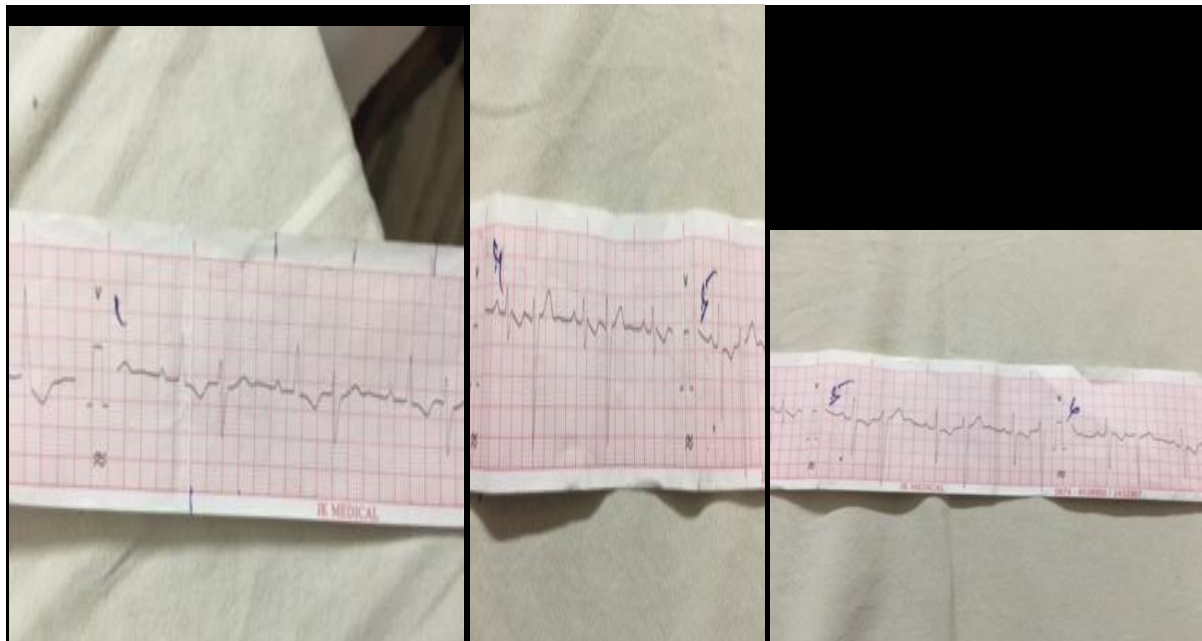
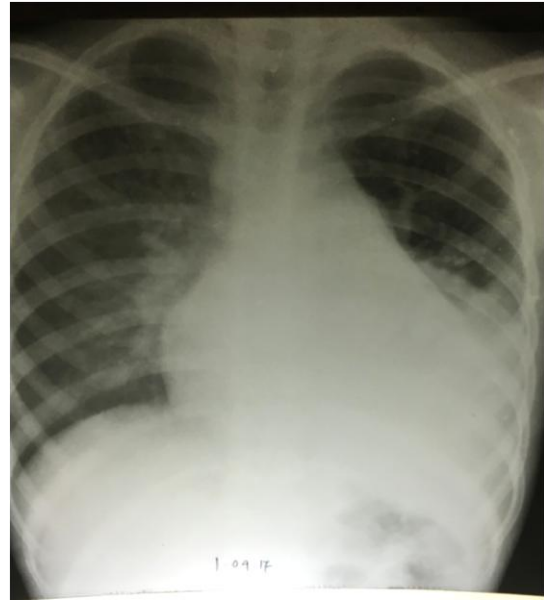


Fig 2 ECG Showing Right Ventricular Hypertrophy

DISCUSSION

By angio-graphic and echocardiographic studies, Ballester et al ^[6] proposed that prolapse of the mitral valve in patients with secundum atrial

septal defect may be related to the distorted left ventricular shape and small left ventricular volume. Davies,^[7] by pathological studies, demonstrated thickening of the medial half of the

anterior cusp and some fusion of adjacent chordae. He also demonstrated histologically that the lesion was a surface fibrosis without vascularisation or myxomatous change to suggest a rheumatic or myxomatous origins. Furuta and colleagues in 1982.^[8] By intra-operative studies, they found abnormal fibrous thickening at the medial half of mitral valve at which leakage of the valve occurred. They proposed the specific pathophysiology called “ASD, MR complex” that friction between anterior and posterior mitral leaflets due to abnormal left ventricular motion secondary to the right ventricular volume overload might be responsible to the genesis of this lesion. So the pathogenesis of mitral regurgitation in ASD could be due to abnormal hemodynamic change in ASD itself, just similar to the aortic regurgitation caused by VSD.

Rheumatic valvular heart diseases were still common problem in our area, so it could have the opportunity to co-exist with ASD.

From whatever cause it might be, most of the mitral valves in mitral regurgitation associated with secundum atrial septal defect could be repaired with satisfactory results, as reported from many literatures.

CONCLUSION

Mitral regurgitation associated with secundum atrial septal defect could exist as an coexistent lesion or as the result of hemodynamic change occurred in secundum atrial septal defect itself. Its recognition is important and most of them could be repaired with satisfactory results. In India it is mostly of rheumatic origin.

CONTRIBUTORS

Dr Nasreen Ali-conception, design and drafting

Dr Sunil Kumar Agarwalla-revising it critically for important intellectual content.

CONFLICT OF INTEREST

There was no conflict of interest and no funds received.

ACKNOWLEDGEMENTS

The authors are thankful to the parents for giving us the consent for writing the case report.

REFERENCE

1. Waikittipong S. Mitral Regurgitation Associated with Secundum Atrial Septal Defect. Thai Journal of Surgery. 2010 Oct 1;31(4).
2. Leachman RD, Cokkinos DV, Cooley DA. Association of secundum atrial septal defects with mitral valve prolapse. Am J Cardiol 1976;38:167-9
3. Davies RS, Green DC, Brott WH. Secundum atrial septal defect and cleft mitral valve. Ann Thorac Surg 1977;24:28-33.
4. Boucher CA, Liberthson RR, Buckley MJ. Secundum atrial septal defect and significant mitral regurgitation : incidence, management and morphologic basis. Chest 1979;75:69.
5. Furuta S, Wanibuchi Y, Ino T, Aoki K. Etiology of mitral regurgitation in secundum atrial septal defect. Jap Circulation J 1982;46:346-51.
6. Ballester M, Presbitero P, Foale R, et al. Prolapse of the mitral valve in secundum atrial septal defect: A functional mechanism. Eur Heart J 1983;7:472-
7. Davies MJ. Mitral valve in secundum atrial septal defects. Br Heart J 1981;46:126-8.
8. Furuta S, Wanibuchi Y, Ino T, Aoki K. Etiology of mitral regurgitation in secundum atrial septal defect. Jap Circulation J 1982;46:346-51.