



Alveolar Ridge Deformities and Corrections - A Review

Authors

**Dr Vishal Yadav, Dr Praveen B. Kudva, Dr Monika Rao Goswamy,
Dr Geetha K. Bhat, Dr Hema P. Kudva**

Department of Periodontology and Implantology, Jaipur Dental College and Hospital, Dhand, Tehsil Amer, Jaipur, Rajasthan, India

Abstract

An alveolar ridge deficiency or ridge collapse may occur, when a tooth is extracted and the dento-alveolus and soft tissue collapses inward. Ridge deformities can create esthetic and functional dilemmas for the patient and restorative dentist. This article reviews the various techniques and procedures of alveolar ridge preservation and reconstruction.

Keywords: Alveolar ridge preservation, Alveolar ridge reconstruction, ridge augmentation.

Introduction

An alveolar ridge deficiency or ridge collapse may occur, when a tooth is extracted and the dentoalveolus and soft tissue collapses inward. Ridge deformities can create esthetic and functional dilemmas for the patient and restorative dentist.¹

Ridge deformities have both soft-tissue (papilla and attached gingiva) and bony-alveolus components. Soft-tissue deformities can occur when surgical incisions are made in delicate areas (thin gingiva, alveolar mucosa, and papillae). Deformities of bone can occur following extraction of a tooth that has a thin dentoalveolus, previous endodontic surgery, endodontic failure, and iatrogenic bone removal, intentional bone removal to gain a purchase, root fracture, or periodontal bone loss.¹

Alveolar Ridge Reconstruction

Reconstruction of a proper ridge form to receive pontics or dental implants is a plastic surgery

procedure. Proper pontic-residual ridge relationship is a critical factor in fixed prosthodontics.

A properly constructed pontic must satisfy demanding requirements of function, esthetics and cleansability. Topographical aberrations in the residual edentulous ridge often prevent the establishment of an ideal pontic-to-ridge relationship, and in such cases residual ridge surgery maybe indicated. A ridge that is excessive in its dimensions may be reduced by appropriate hard and soft tissue resective procedures.²

Seibert presented a classification of ridge deformities. Seibert placed ridge defects in three general categories.³

Class I : Buccolingual loss of tissue with normal ridge in the apicocoronal dimension.

Class II : Apicocoronal loss of tissue with normal ridge width in a buccolingual dimension.

Class III : Combination buccolingual and apicocoronal loss of tissue resulting in loss of height and width.

According to Allen et al, in a modification of Seibert's original classification, different types of ridge deformities may be described as follows^{2,3}

Type A - Apicocoronal loss of ridge contour.

Type B - Buccolingual loss of ridge contour.

Type C - Combined loss of ridge Contour in both apicocoronal and buccolingual dimensions.

The ridge deformity may be further described by assessing the depth of the defect relative to the adjacent ridge:

- ❖ Mild - less than 3 mm.
- ❖ Moderate - 3 to 6 mm.
- ❖ Severe - greater than 6 mm.

The goal of reconstructing an alveolar ridge is to restore the patient functionally, phonetically, and esthetically. The anatomical configuration of the defect often determines the selection and sequence of treatment procedures.

Outline of ridge augmentation procedures⁴

Soft tissue procedures

A. Pouch procedures

1. Contiguous soft tissue autograft or "roll" procedure
2. Subepithelial connective tissue procedures
 - a) Intraconnective tissue placement of graft
 - b) Connective tissue or supraperiosteal tissue placement of the soft tissue graft
 - c) Subperiosteal placement of soft tissue graft

B. Interpositional grafts

C. Onlaygrafts

D. Soft tissue enhancement in implant therapy

Osseous ridge augmentation procedures

A

1. Non-sintered resorbable hydroxyapatite implants
2. β -tricalcium phosphate resorbable implants
3. Autogenous bone implants (jaw, chin, hip marrow, iliac crest etc)
4. Freeze-dried decalcified bone allograft implants

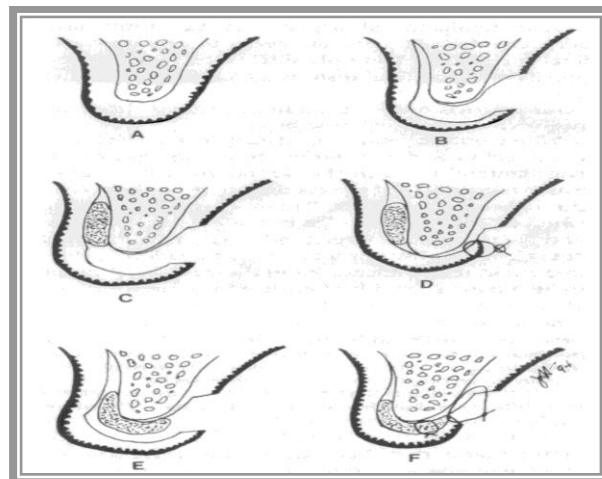
B. Guided bone regeneration procedure

1. Preprosthetic procedures
2. Immediate post-extraction site implant placement

3. Delayed post-extraction site implant placement

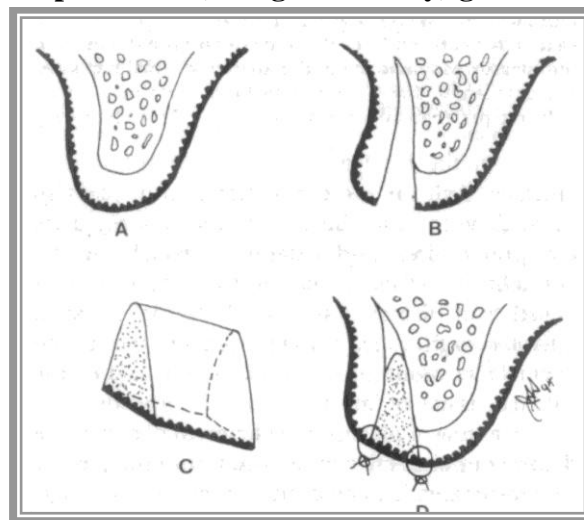
Pouch Procedure

Abrams described a pedicle type pouch graft derived from the connective tissue overlying the edentulous area, which was de-epithelialized, detached from the palatal aspect and "rolled" under itself to enhance the buccal dimension.



Pouch procedure

Inter positional (Wedge and Inlay) graft



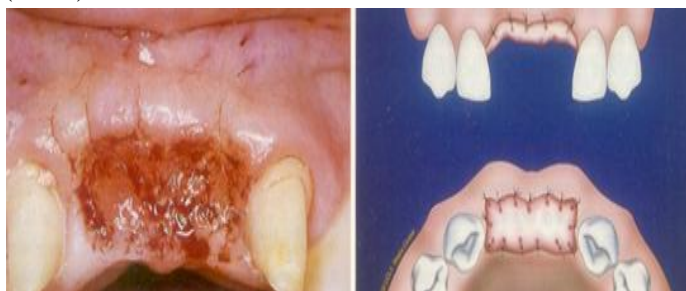Inter positional graft

Interpositional graft differs slightly from pouch procedures in which a subepithelial interconnective tissue, or subconnective tissue graft is used.

A free graft that is pie (wedge) shaped in its cross section is removed from the palate or tuberosity area and inserted like a wedge into opening of the pouch.

Soft tissue Onlay Graft: ⁵

The technique utilizing onlay graft for ridge augmentation has been described by Seibert (1983).



Soft tissue onlay graft

Recipient site is prepared by de-epithelization of the ridge in the area where augmentation is intended. A series of evenly placed buccolingual incision are made perpendicular to the ridge, sufficiently deep into the connective tissue to engage the larger blood vessels and to encourage enhanced blood supply. Graft is obtained from palatal aspect. Instead of 2 mm partial thickness graft, a full thickness graft often in the 4-6 mm range is harvested.

The donor site is filled with haemostatic agent and covered with the previously prepared well-fitting acrylic or plastic surgical stent. The graft is transferred to the recipient site and adjusted to fit the preparation. Interrupted stabilizing sutures are placed at the opposite corners on the same side of the graft.

Augmentation of deficient ridges

Guided tissue regeneration is an osteopromotion technique whereby soft tissue is excluded from the defect site by the utilization of a membrane in order to encourage bone healing and bone neogenesis.

In experiments using guided tissue regeneration Gotlow et al. found that the volume and shape of the tissue generated under the membrane seemed to be determined by the configuration of the "artificial space". Seibert & Nyman presented a pilot study of localized ridge augmentation in dogs. Their findings suggested that in areas where the membrane was not supported, some collapse

occurred. In addition, less regeneration was observed in the areas where the membrane did not retain its shape. Therefore, space maintenance under the membrane is a critical component, especially in treating large defects.

Nyman et al. presented a case report wherein an implant site deficient in the buccolingual dimension was augmented using guided tissue regeneration prior to implant placement. Buser et al. also reported on the osseous augmentation of short edentulous spans with an emphasis on creating and maintaining a space for guided bone regeneration during healing by the utilization of mini-screws. Spacemaking membranes are available to establish and maintain the regenerative space.

Flap management that ensures the continued coverage of the membrane during the 6-12 months of healing has also been shown to be an important factor in successful guided bone regeneration. Becker et al. and Simion et al. suggested that, although a certain degree of osseous augmentation can still occur even in the presence of hygienic membrane exposure, it does so at a significantly reduced rate than when the membrane remains covered throughout the healing phase.

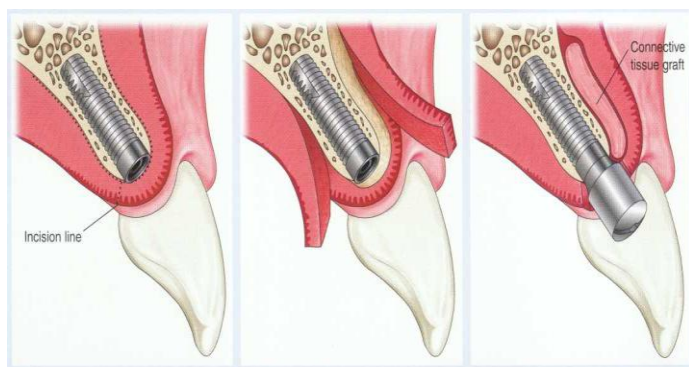
Guided bone regeneration is a predictable therapeutic technique that can be used separately in a staged approach to first augment the ridge or in conjunction with implant placement when primary stability of the implant is achievable. When a staged approach is used, a 9- to 12-month healing period is recommended to allow fuller maturation of the new osseous tissue prior to implant placement.⁴

Soft tissue enhancement in implant therapy

For severe soft tissue deficiencies, as well as onestage implant systems, it is more predictable to augment the sites before or during implant placement surgery. Onlay gingival grafts and sub-connective tissue grafts are the most common techniques used in this approach to early enhancement.

The popular use of two-stage implant systems and the need to consolidate surgical procedures, however, have necessitated the sequencing of most soft tissue enhancement procedures in conjunction with stage II implant exposure surgery.⁴

A palatal or lingual incision is used to acquire the maximum amount of keratinized tissue into the flap. An initial full thickness reflection over the heads of the implants is followed by a partial thickness dissection on the buccal dimension. The principal benefit of this surgical design is to position the flap buccally and apically to gain optimal harmony with adjacent teeth and restorations.⁴



Connective tissue grafts at second-stage implant surgery

Conclusion

Soft and hard tissue ridge deformities are prevalent in areas of tooth loss and trauma and can significantly compromise aesthetic outcomes. Complete understanding of the dimensional defects, surgical techniques available and the aesthetic and functional needs of the final implant or fixed prosthetic restoration will allow the design of a treatment approach that will achieve the desired outcome.

References

1. W. Peter Nordland. The Role of Periodontal Plastic Microsurgery in Oral Facial Esthetics Journal of the California Dental Association. 2002;34:45-52
2. Cary Galler. The periodontal infrastructure. Dental clinics of North America 1998; 42: 579-595.
3. Michael K, McGuire. Periodontal Plastic Surgery. Dental Clinics of North America 1998;42:411-437
4. Jay s. Seiber&t h, Enrsya lama. Alveolar ridge preservation and reconstruction. Periodontology 2000, Volume. 11, 1996, 69-84
5. Paulom. Camargo, Philip R.Melnick & E. Barrie Kenney. The use of free gingival grafts for aesthetic purposes. Periodontology 2000. 2001;27:, 72–96
6. Acocella A, Bertolai R, Ellis E 3rd, Nissan J, Sacco R. Maxillary alveolar ridge reconstruction with monocortical fresh-frozen bone blocks: a clinical, histological and histomorphometric study. Journal of Craniomaxillofacial Surgery. 2012 Sep; 40 (6): 525-33.
7. Orsini G, Stacchi C, Visintini E, Di Iorio D, Putignano A, Breschi L, Di Lenarda R. Clinical and histologic evaluation of fresh frozen human bone grafts for horizontal reconstruction of maxillary alveolar ridges. International Journal of Periodontics Restorative Dentistry. 2011 Sep-Oct; 31 (5): 535-44.
8. Mardas N, D'Aiuto F, Mezzomo L, Arzoumanidi M, Donos N. Radiographic alveolar bone changes following ridge preservation with two different biomaterials. Clinical Oral Implants Research 2011 Apr;22(4):416-23.