



Primary Ewing Sarcoma at Rare Sites – A Study of Few Cases

Authors

**Guddi Rani Singh¹, Rawi Agrawal¹, Vijayanand Choudhary², Ajeet Kumar¹,
Amit Kumar Sinha¹, Krishna Kumar Singh³**

¹Senior Resident, Dept. of Pathology, IGIMS, PATNA

²Additional Professor, Dept. of Pathology, IGIMS, PATNA

³Assistant Professor, Dept. of Psychiatry, IGIMS, PATNA

Abstract

The Ewing family of tumors includes classic Ewing Sarcoma (ES), atypical ES, primitive neuroectodermal tumor (PNET), and Askin tumor. It is a small round blue cell tumor involving most commonly the diaphyses of long bones. We present a series of four cases of ES occurring at rare sites.

Keywords: Ewing's sarcoma, PNET, small round cells, FLI-1, CD99.

Introduction

Ewing Sarcoma is an aggressive malignant small round cell tumour usually seen in children and young adults with a peak incidence in the second decade of life.⁽¹⁾ Ewing's sarcoma family of tumours incorporates both primary bone sarcomas and extra skeletal tumours. Skeletal tumours most frequently arise from the femur or pelvis in males aged 10–20 years. Within the long bones, the tumor is almost always meta diaphyseal or diaphyseal. Only 0.5% patients present with a lesion in the epiphysis. Primary Ewing Sarcoma of the cranial bone is rare, contributing to only 1% of all Ewing Sarcomas⁽²⁾ and involvement of the Sphenoid bone is uncommon. Extra skeletal tumours are far less common. Different locations of primary tumors include chest wall, paravertebral region, lower extremities, mediastinum, retroperitoneal cavity, diaphragm, duodenum, perigastric space, parapharyngeal space, parotid gland, hard palate, kidney etc.⁽³⁾ A

primary Ewing's sarcoma arising from the breast or pleura is exceedingly rare.

Observations and Results

History, clinical and radiological findings:

Case 1: A 20-month-old male child presented with a rapidly increasing, painful swelling over the right cheek for over 2 months. On examination, the swelling extended from the lateral canthus of right eye up to the right cheek. There were no neurological deficits. CT scan showed a 5cmx6cm enhancing soft tissue mass arising in the body and right wing of sphenoid bone with extension into right cavernous sinus, right maxillary sinus and right retro or bital space and erosion of the frontal bone, right temporal bone, right zygomatic bone, lateral wall of the right orbit and the right mandible.

Case 2: A 20-year-old female presented with a swelling in the right breast of about 15x13cm since 1 year. The swelling was freely mobile with

respect to skin and underlying structures, non tender and nodular. Axillary lymph nodal swelling of 3x3 cm was also present. Chest radiograph showed an opacity in the right hemithorax with no involvement of bony rib cage. CT scan revealed a large expansile lytic lesion measuring 18x17x16cm involving the right breast with intra thoracic extension.

Case 3: A 10 years old male child presented with dyspnoea and cough since 9 months. On chest X-ray there was massive left sided pleural effusion. CT scan revealed left sided massive pleural effusion and a heterogeneous, enhancing mass located at the left pleural cavity causing collapse of the adjacent lung. There was no bony destruction.

Case 4: A 24 years old male presented with pain, swelling and restriction of movements of left shoulder since 6 months. Plain radiography and CT scan revealed a lytic lesion involving the proximal humeral epiphysis.

Cytological findings

FNAC from each of the four swellings revealed cellular smears with round to oval cells with high nucleus:cytoplasmic (N:C) ratio in clusters and dispersed singly. Occasional rosettes were also seen. Features were suggestive of Round Cell Tumor.

Histological findings

Haematoxylin and Eosin (H&E) stained sections from all the four cases showed a tumour composed of small round cells. Tumour cells had a high N/C ratio, round to oval uniform nuclei with finely dispersed chromatin, inconspicuous nucleoli and scant cytoplasm. On immunohistochemistry, CD99 (MIC2) and FLI 1 were positive. Final diagnosis of Ewing's Sarcoma (ES) was made in each case.

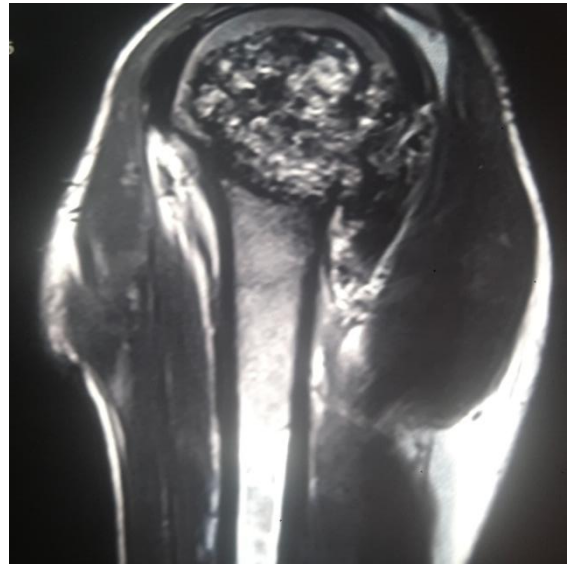


Figure 1: CT scan showing mass arising in the epiphysis of the humeru

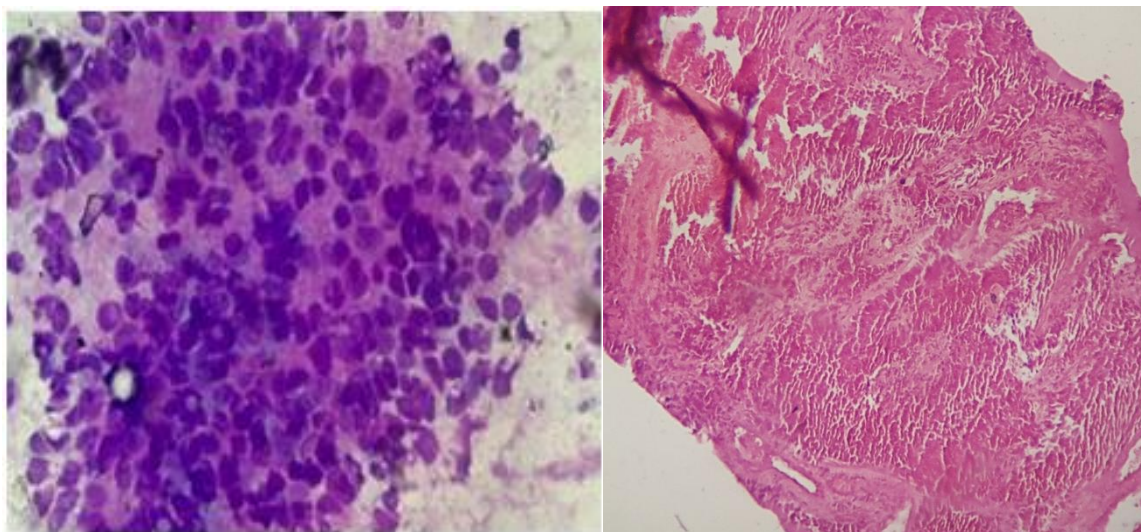


Figure 2: FNAC smear from the breast mass & Microsection from cranium showing small round to oval cells with high N/C ratio with rosette (arrow) formation. (Giemsa stain, × 400)

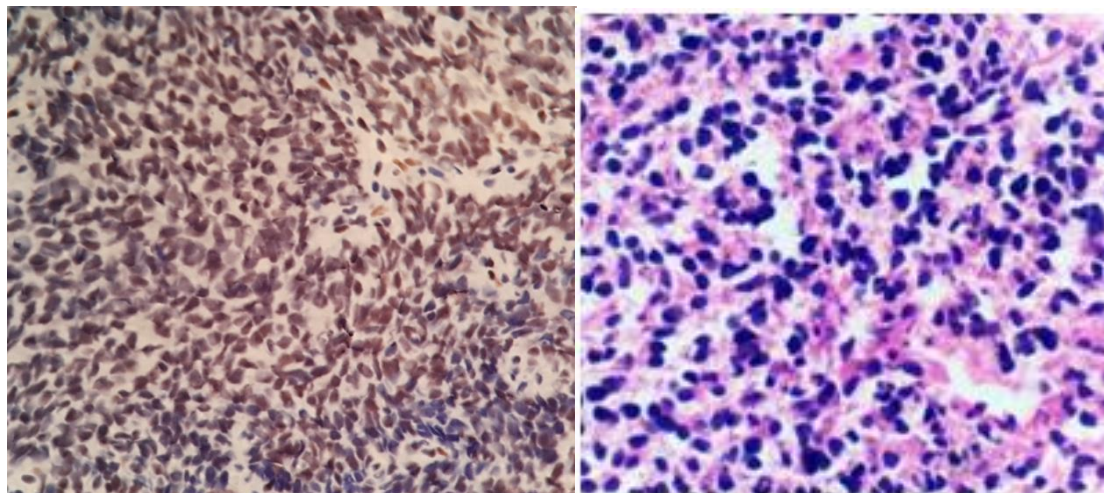


Figure 3 & 4: Microsection from the tumour in pleura & humerus showing small round cell tumor. (H&E stain, × 400)

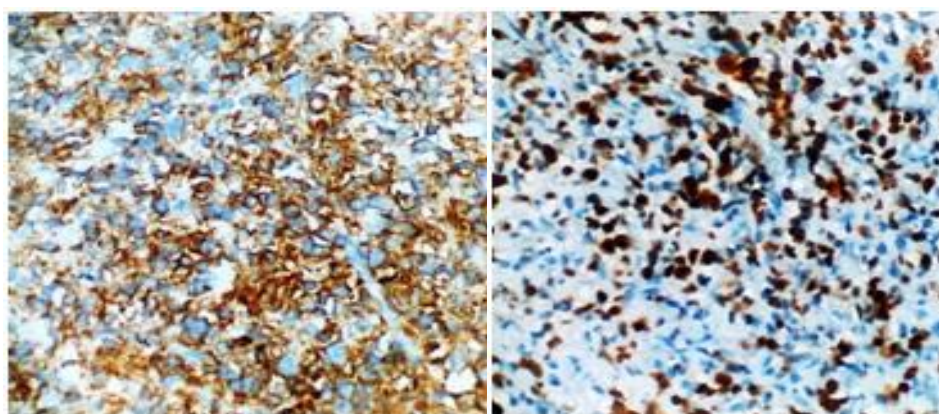


Figure 5 & 6: Tumor cells showing CD 99 & FLI 1 positivity (IHC stain, × 400)

Discussion

The Ewing family of tumors includes classic ES, atypical ES, primitive neuroectodermal tumor (PNET), and Askin tumor. Ewing tumors are derived from postganglionic parasympathetic primordial cells and can occur in any part of the body.⁽⁴⁾ ES primarily occurs in bones, with rare occurrences in soft tissues. Most extra-skeletal ESs affect patients between 10 and 30 years of age, with a peak incidence at approximately 20 years old. The most common sites are the chest wall, paravertebral muscles, extremities, buttocks and retro-peritoneal space. Extra-skeletal ES present with rapid growth and frequent distant metastases, similar to ES of bone.⁽⁵⁾ We report four cases of Ewing's sarcoma at rare sites.

Primary ES of skull is very rare and its incidence is less than 1%.⁽⁶⁾ Most common bone involved by ES in skull is temporal bone followed by

parietal bone and occipital bone. Sphenoid and ethmoid bones are least commonly involved.⁽⁷⁾

Carcinomas are the majority of malignancies involving the breast; sarcomas represent less than 1% of breast malignancies.⁽⁸⁾ EWS/PNET of the breast is extremely rare, with several of primary tumors previously reported in the literature.⁽⁹⁾ ES can involve any bone in the axial or appendicular skeleton, with approximately 30% of cases involving the pelvis and approximately 50% occurring in long bones.⁽¹⁰⁾ Long bone lesions typically arise in the diaphysis or metadiaphysis. The Intergroup Ewing's Sarcoma Study group reported that out of 206 patients with ES of bone; approximately 57% were located in the meta diaphysis, approximately 35% presented in the diaphysis and only 1 (0.5%) patient presented with a lesion in the epiphysis.⁽¹¹⁾

Primary ES of pleura is extremely rare. Patients typically present with painful chest wall mass and

presentation of pleural effusion as in our case, is an unusual finding.⁽¹²⁾ Extraskelatal ES arises in the soft tissues of the trunk or the extremities and although is a primary soft tissue tumor it can invade the adjacent bones. In our case there was no involvement of the bones.

The radiological appearance of these tumours is very variable, but they usually have clearly aggressive appearance. Diagnosis of ES depends primarily on cytological and histological evaluation combined with immunohistochemistry. Extra osseous ES morphologically is indistinguishable from osseous ES.

Treatment of ES should include aggressive surgical resection and multiagent chemotherapy. Adjuvant radiationtherapy should also be considered.^(13,14) A patient age < 16 is associated with a favorable prognosis³. Other major prognostic factors include the size of the tumor, complete resection of the tumor with wide surgical margins, the location of the mass the presence of metastases, the extent of necrosis, the initial response to chemotherapy and the presence of EWS/FL 11 transcripts.⁽¹⁴⁾

Conclusion

ES should be considered in the differential diagnosis of any patient, of any age with a mass of the breast, extremities or cranium. Whenever a patient presents with hemorrhagic pleural effusion, especially in tuberculosis endemic countries like India, it is worthwhile to perform histopathological examination before starting the patient on antituberculosis treatment. All patients even those who present metastases at the time of diagnosis should be treated and may benefit from an aggressive multimodal management strategy.

References

- Desai KI, Nadkarni TD, Goel A, Muzumdar DP, Naresh KN, Nair CN. Primary Ewing's sarcoma of the cranium. *Neurosurgery*. 2000;46:62-68.
- Sim FH, Unni KK, Beabout JW, Dahlin DC. Osteosarcoma with small cells simulating Ewing's tumour. *Bone and Joint Surg*. 1979;61:207-15.
- Karatziou C, Pitta X, Stergiouda T, Karadimou V, Termentzis G. A case of extraskelatal Ewing sarcoma originating from the visceral pleura. *Hippokratia* 2011, 15, 4: 363-365.
- van den Berg H, van Rijn RR, Merks JH. Management of Tumors of the Chest Wall in Childhood: A Review. *J Pediatr Hematol Oncol* 2008;30:214-221.
- Iwamoto Y. Diagnosis and Treatment of Ewing's Sarcoma. *Jpn J Clin Oncol* 2007;37:79-89.
- Sim FH, Unni KK, Beabout JW, Dahlin DC. Osteosarcoma with small cells simulating Ewing's tumour. *Bone and Joint Surg*. 1979;61:207-15.
- Singh P, Jain M, Singh DP, Kalra N, Khandelwal N, Suri S. MR findings of primary Ewing's sarcoma of greater wing of sphenoid. *Australas Radiology*. 2002;46:409- 11.
- Pollard SG, Marks PV, Temple LN, Thompson HH. Breast sarcoma. A clinicopathologic review of 25 cases. *Cancer* 1990;66:941-4.
- Vindal A, Kakar AK. Primary primitive neuroectodermal tumor of the breast. *J Clin Oncol* 2010;28:e453-5
- Peersman B, Vanhoenacker FM, Heyman S, et al. Ewing's sarcoma: imaging features. *JBR-BTR*. 2007; 90(5):368-376.
- Reinus WR, Gilula LA. IESS Committee: radiology of Ewing's sarcoma: intergroup Ewing's sarcoma study. *Radiographics*. 1984; 4:929-944.
- Ozge C, Calikoglu M, Cinel L, Apaydin FD, Ozgur ES. Massive pleural effusion in an 18-year-old girl with Ewing sarcoma. *Can Respir J* 2004 Jul- Aug;11(5):363-365.
- Wolf G, Aigner RM, Schwarz T. Massive pleural effusion with dyspnea in a 17-year-old boy as the first sign of Ewing sarcoma.

- J Pediatr Hematol Oncol 2002 Jun-Jul;24(5):420.
14. Ozge C, Calikoglu M, Cinel L, Apaydin FD, Ozgur ES. Massive pleural effusion in an 18-year-old girl with Ewing sarcoma. Can Respir J 2004 Jul- Aug;11(5):363-365
 15. Lee WS, Kim YH, Chee HK, Hwang JJ, Kim JS, Lee SA, et al. Multimodal Treatment of Primary Extraskkeletal Ewing's Sarcoma of the Chest Wall: Report of 2 Cases. Cancer Res Treat.2009; 41: 108–112.