



Multidetector Computerized Tomography -- Is It Indispensable In Management of Gastric Carcinoma?

Authors

**Dr Saritha K.R.¹, Dr Suny Thomas², Dr Mohanan K.³, Dr Brahmadathan M.N.⁴,
Dr Paul V. Puthussery⁵, Dr Suma Job⁶**

¹⁻⁶Department of Radiodiagnosis, Government Medical College, Thrissur, Kerala, India

Corresponding Author

Dr Suny Thomas

Additional Professor of Radiodiagnosis, Government Medical College, Thrissur

Email: drsunytony@gmail.com

ABSTRACT

Introduction: *The role of Multidetector Computerized Tomography (MDCT) in gastric carcinoma evaluation and management is a matter of debate. Early and accurate detection, staging and management significantly improve the prognosis.*

Aim of the Study: *To evaluate the efficacy of MDCT in comparison with the surgical and histopathological findings in gastric carcinoma.*

Materials and Methods: *50 patients with diagnosed gastric adenocarcinoma were evaluated with MDCT. Staging was done and correlated with surgical and histopathological findings which were the gold standard. Various statistical calculations and significance are assessed.*

Results: *The sensitivity, specificity, positive and negative predictive values and accuracy of MDCT were calculated with regards to T staging, N staging, regional infiltration and metastases.*

Conclusions: *There was statistically significant correlation between MDCT and histopathological findings in T staging and N staging. Sensitivity was more in advanced carcinoma. The limitations in T staging were in differentiating T3 and T4 and in assessing regional infiltration. This was most probably due to the reduced intraabdominal fat in thin, cachexic patients. The incidence of micro metastases in normal sized lymph nodes and reactive enlargement of lymph nodes were the limitations in N staging. MDCT can reliably rule out metastases. Overall, MDCT is a highly reliable tool in accurate staging of gastric carcinoma, which helps in accurate management and improves prognosis.*

Keywords: *multidetector computerized tomography, gastric carcinoma.*

Introduction

Gastric carcinoma is the third leading cause of cancer deaths in the world¹ even though the incidence of gastric cancer is decreasing worldwide.² Patients with advanced gastric cancer (AGC) have a 5-year survival rate of 7%–27%, whereas those with early gastric cancer (EGC) have

a 5-year survival rate of 85%–100%^{3,4,5,6}. A wide arena of therapeutic options is in practice, from endoscopic mucosal resection for selected mucosal cancers to more radical treatments for advanced cancers. An accurate evaluation of the local and distant extent of the disease is essential to select an optimal therapeutic approach. Hence accurate

preoperative staging, particularly with regard to depth of mural invasion, adjacent organ invasion, nodal involvement, and distant metastases is vital in determining the most suitable therapy and avoiding inappropriate attempts at curative surgery in patients presenting with advanced disease.

Computed tomography (CT) in the preoperative staging of gastric cancer has been suggested as an accurate imaging modality for evaluating the extent of primary gastric cancer and nodal involvement of the disease^{7,8,9}. The reported results comparing preoperative CT with histopathological findings do vary^{10,11}. Some studies say that Multidetector CT is an excellent modality for preoperative staging while some studies do not support this. They are of the opinion that CT is not an accurate tool for preoperative staging. In this study, we have attempted to assess the efficacy of MDCT in determining the accurate management of gastric carcinoma.

Aim of the Study

To compare and correlate the findings of preoperative staging of carcinoma stomach with surgical and histopathological findings which is the reference standard.

Materials and Methods

A prospective study was conducted in the Department of Radio diagnosis, Govt. Medical College, Thrissur from January 2013 - June 2014 with the approval of the Institutional Ethics Committee. The sample size was 50, calculated using the formula $4pq/d^2$. (Sensitivity of transverse images in T stage in a study by AEM Hameed 12 et al was 75% and was used in $N=4pq/d^2$ to calculate sample size with $p=75$, $q=25$ $d=75 \times 20/100$; hence $N=$ at least 33.33). Inclusion criterion was biopsy proven gastric adenocarcinoma patients in need of preoperative staging. Exclusion criteria were previous gastric surgery, neoadjuvant chemotherapy, CT-surgery interval >1month and those patients with metastases. All patients coming for preoperative staging of carcinoma stomach were evaluated with multi detector computed tomography (SIEMENS SOMATOM 16). CT staging done was

compared with surgical and histopathological findings.

Patients were kept nil orally for at least 4 hours prior to the CT scan to avoid complications while administering contrast medium. Risk of contrast administration was explained to the patients and informed consent was obtained prior to the study. Routine anteroposterior topogram of the abdomen was taken initially in all patients in supine position with the breath held in inspiration. Axial plane sections of 5mm thickness were taken from the level of lung bases to the ischial tuberosities. Plain scan was done initially followed by contrast scan including oral contrast and intravenous contrast in arterial and venous phase at 40-60s and 80-120s in supine position and right lateral decubitus scan was taken at 180s in distal stomach lesions. Post study reconstructions were done at 1.5mm. Sagittal and coronal reconstructions were also made. Newer techniques in multislice CT like curved planar reformatting, volume rendering, maximum intensity projection, minimum intensity projection were done when in need. The magnification mode was employed and scans were viewed on a direct display console at multiple window settings (Abdomen window at 320/40, lung window at 1400/-600, bone window of 2400/200). The lesions were evaluated in pre and post contrast images for enhancement, size, fat plane, adjacent structure invasion, lymphadenopathy and metastases.

The data were managed in Microsoft excel and descriptive statistics on the population of interest were generated from data obtained. Statistical analysis was done using Epi info 7 and SPSS. Diagnostic statistics such as sensitivity, specificity, positive predictive value, negative predictive value and accuracy were calculated to compare CT scan with pathological findings. Correlation is assessed with SPSS.

Results

From Table 1 and 2, it is observed that there was no pathologically proven T1 case. There were 3 T2 cases, 17 T3 cases and 30 T4 cases given in CT. In T2 staging there were 2 true positive cases. There

were 12 true positive cases in T3 stage and 23 true positive cases in T4 stage. For T2 stage, sensitivity comes to 66.6% and specificity to 97.87%. For T3 stage, sensitivity comes to 63.16% and specificity to 83.87%. For T4 stage sensitivity is 82.14. % and specificity is 68.18 %. Positive predictive value for T2, T3 and T4 were 66.67%, 70.59% and 76.67% respectively. Negative predictive value for T2, T3 and T4 were 97.87%, 78.79% and 75%.

Table 3 and 4 shows that 15 cases were N1 stage, 29 cases were in N2 stage and 6 cases in N3 stage. Pathologically there were 5 N0 cases, 15 N1cases, 24 N2 cases, and 6 N3 cases.

There were no true positive cases in N0 stage. There were 0, 8, 19 and 4 true positive cases in N0,N1,N2 and N3 respectively and 45,28 ,16 and 42 true negative cases respectively in N0,N1,N2 and N3 stages. Sensitivity of N0, N1,N2 and N3 stages were 0 ,53.3%,79.17%, and 66.67% respectively, Specificity of N0, N1,N2 ,and N3 were 100%, 80%, 61.5%,and 95.45% respectively. Positive predictive values for N1 were 53.3%, N2 was 65.51% and N3 was 66.67%. Negative predictive values for N0, N1, N2, N3 were respectively 90%, 80. %, 76.19% and 95.45%.

Adjacent organ infiltration was present in 2 cases (4%) with pancreatic infiltration in 1 case and mesocolon invasion in the other. 96% cases had no regional infiltration.

47 cases had no metastases, while 3 cases had metastases. These 3 cases were not detected by CT. The specificity is 100%. Lesions involving various parts of stomach in CT are depicted in Fig 1-3.

Table 1: Comparison between CT T staging versus pathological T staging

CT T STAGING	PATHOLOGICAL STAGING			
	P T1=0	P T2=3	P T3=19	P T4=28
T1=0	0	0	0	0
T2=3	0	2	0	1
T3=17	0	1	12	4
T4=30	0	0	7	23

Table 2: Sensitivity, specificity, PPV, NPV and accuracy of CT in T staging of gastric carcinoma.

T staging	Sensitivity	Specificity	PPV	NPV	Accuracy
T1	-	100	-	100	100
T2	66.67	97.87	66.67	97.87	96
T3	63.16	83.87	70.59	78.79	76
T4	82.14	68.18	76.67	75	76

Table 3: Comparison between CT N staging versus pathological N staging

CT N STAGING	PATHOLOGICAL N STAGING			
	P N0=5	PN1=15	PN2=24	P N3=6
N0=0	0	0	0	0
N1=15	3	8	4	0
N2=29	2	6	19	2
N3=6	0	1	1	4

Table 4: Sensitivity, specificity, PPV, NPV and accuracy of CT in N staging of gastric carcinoma.

N staging	Sensitivity	Specificity	PPV	NPV	Accuracy
N0	-	100	-	90	90
N1	53.3	80	53.3	80	72
N2	79.17	61.5	65.51	76.19	70
N3	66.7	95.45	66.67	95.45	92

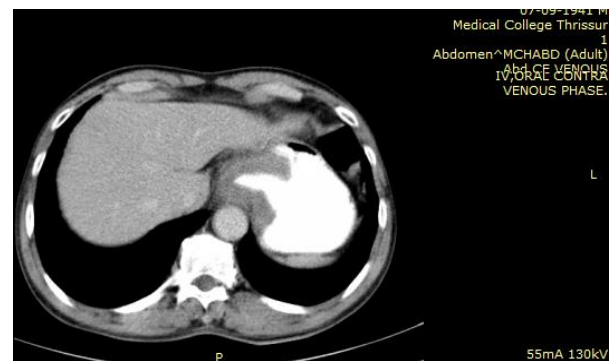

Fig 1: Post contrast CT image of gastric carcinoma involving gastric fundus.

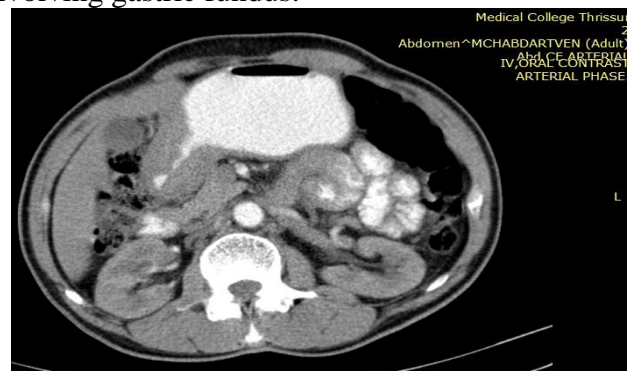


Fig 2: Circumferential growth which was biopsy proven to be gastric carcinoma involving gastric pylorus.

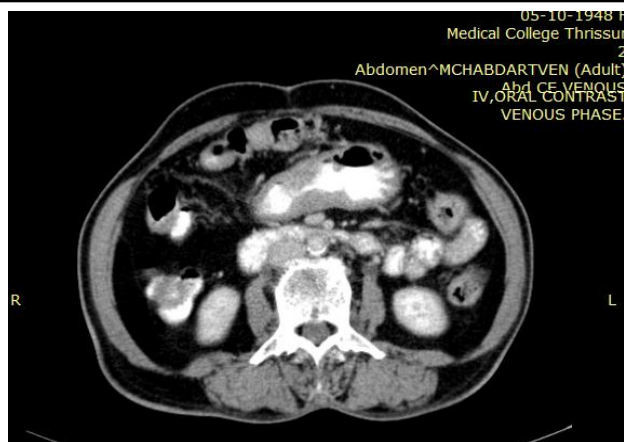


Fig 3: Irregular wall thickening involving gastric body which on histopathological correlation was proved to be carcinoma.

Discussion

Regarding T staging, accurate staging was done in 37 cases, upstaging was done in CT in 8 cases and down staging in 5 cases. 7 of the T3 cases were given as T4 and 4 of the T3 case were given as T3. Overall sensitivity for T staging was 74%, specificity 87.48% and accuracy 87.5%.

In a study by Zhong BY¹³ et al done to review the 64-slice spiral 3-phase CT enhanced scanning of 120 patients with gastric cancer, the accuracy of 64-slice spiral CT enhanced scan was 79.2%(95/120) for T staging, 66.7%(10/15) for T1, 66.7%(14/21) for T2, 84.0%(42/50) for T3, and 85.3%(29/34) for T4.

In a study by Zompetta¹⁴ et al on 25 patients with adenocarcinoma of the stomach, the performance values of CT in detecting tumor extension to the serosa were sensitivity of 78%, specificity of 63%; and overall accuracy of 72%. Kim¹⁵ et al reported on the diagnostic performance of 64-channel MDCT using 2D MPR images and virtual gastroscopy for T-staging according to the AJCC 7th edition guidelines. In that study, the sensitivities for correct T-staging were 62.5%-93.0%, and the specificities were 90.5%-97.9%; the overall T-staging accuracy was 77.2%

Regarding N staging, accurate staging was done in 31 cases. Over staging was done in CT in 13 cases and down staging was done in 6 cases. Overall sensitivity for N staging was 66.39%, specificity 84% and accuracy 81%.

In a study by Kwee RM et al the sensitivity and specificity of MDCT for N staging varied between 62.5% and 91.9% (median, 80.0%) and 50.0% and 87.9% (median, 77.8%). Grenacher¹⁷ et al found that the sensitivity for the lymph nodes is between 64 and 88%. In a study by Zompetta¹⁴ et al in the detection of metastatic involvement of lymph nodes, CT demonstrated to be 70% sensitive, 62% specific with an efficacy of 68%. In a study by Zhong BY¹³ et al the accuracy of 64-slice spiral CT enhanced scan was 73.9%(85/115) for N staging, 75.5% (37/49) for N0, 70.3%(26/37) for N1, 75.9%(22/29) for N2.

Regarding regional infiltration, adjacent organ infiltration was present in 2 cases (4%) with pancreatic infiltration in 1 case and mesocolon invasion in the other.

Regarding omental deposits and liver nodule, omental deposits were pathologically positive for metastases in 2 cases. Liver nodule was seen in 1 case which was found to be pathologically positive for metastasis. These cases were not identified in CT. Overall sensitivity of metastasis to omentum and liver was nil and specificity 94%. Negative predictive value was 94.92 %.

F. D'Elia¹⁹ et al correctly staged liver metastases in 105 of 107 patients with an overall sensitivity of 87.5 % and specificity of 99 % and the sensitivity of peritoneal involvement was 30 % when ascites or peritoneal nodules were absent. In a study by Chamadol N²⁰ on twenty eight patients with gastric carcinoma who underwent preoperative CT scan, peritoneal metastasis could not be identified by CT, but CT had 100% sensitivity for evaluating hepatic metastases. In the study by Bang Bin Chen²¹ et al in 64 patients with gastric cancers, there was good correlation between MDCT images and pathology in 73% of T staging and 69% of N staging.

In our study, Pearson coefficient for T staging was .68 with p value <.05 and for N staging was .37 with p value .007. Thus there was significant correlation of CT staging with pathological staging. In our study for T4 and T3, the sensitivity was 82.1% and 73.1% and specificity was 83.87% and 68.1% and for T2 the sensitivity and specificity was 66.67 %

and 98.7%. Thus sensitivity is more for advanced carcinoma.

In our study in 37 cases T stage was correctly staged. Upstaging was given in 8 cases and 5 cases were given down staging. 7 of the T3 cases were given as T4 and 4 of the T4 cases were given as T3. One T2 case was given as T3 and one T4 case was given as T2. There is difficulty in differentiating T3 from T4 when the fat plane is not well demonstrated as in thin cachexic patients.

In our study the sensitivity for N2 and N3 were 79% and 66.7% and specificity was 80 % and 61.5%. Sensitivity was nil and 53.3% for N0 and N1. Thus sensitivity is more for advanced carcinoma. There was upstaging in CT in 13 cases out of which 6 N1 cases were given as N2 and up staging may be due to reactive changes and enlargement of lymph nodes and down staging in 6 cases out of which 4 N2 cases were given as N1 which may be due to microscopic metastases.

Adjacent organ infiltration was present in 2 cases (4%) which could not be well demonstrated in our study probably due to significantly decreased intra abdominal fat. Metastatic deposit in omentum and liver had sensitivity of 33.3%. Lesser sensitivity in our study may be due to inoperability of most cases identified with metastases. Overall accuracy was 96 % and specificity was 96% .Thus CT can be reliably used to rule out distant metastases.

Conclusion

Preoperative staging of carcinoma stomach by Multidetector CT has statistically significant correlation and accuracy in overall T staging and N staging with resultant accurate management. For advanced gastric carcinoma, the sensitivity is high compared to early carcinoma. The difficulty in differentiating T3 and T4 in some patients causes over staging and down staging. Lymph node metastasis in normal sized lymph nodes has lesser sensitivity causing down staging Also reactive inflammation in enlarged lymph nodes leads to upstaging. Multi detector CT is a reliable imaging modality in metastatic work up even though omental deposit may be difficult to detect in the

absence of generalized ascites. Thus multi detector CT can be a highly reliable tool in deciding the treatment modality and further management of gastric carcinoma.

References

1. Jemal A, Bray F, Center MM, Ferlay J, Ward E, Forman D. Global cancer statistics. *CA Cancer J Clin* 2011; 61: 69_90. doi: 10.3322/caac.20107. PMID: 21296855.
2. Davies J, Chalmers AG, Sue-Ling HM, et al. Spiral computed tomography and operative staging of gastric carcinoma: a comparison with histopathological staging. *Gut*. 1997; 41:314–9.
3. Martin RC 2nd, Jaques DP, Brennan MF, Karpeh M. Extended local resection for advanced gastric cancer: increased survival versus increased morbidity. *Ann Surg* 2002; 236(2):159–165.
4. Yan-Quiroz EF, Díaz-Plasencia JA, Burgos-Chávez OA, et al. Five-year survival prognosis factors in patients with resectable advanced serosa exposed gastric carcinoma. *Rev Gastroenterol Peru* 2003; 23(3):184–191.
5. Nitti D, Marchet A, Mammano E, et al. Extended lymphadenectomy (D2) in patients with early gastric cancer. *Eur J Surg Oncol* 2005;31(8):875–881.
6. Carter KJ, Schaffer HA, Ritchie WP Jr. Early gastric cancer. *Ann Surg* 1984; 199(5):604–609
7. Moss AA, Schnyder P, Marks W, Margulis AR. Gastric adenocarcinoma: a comparison of the accuracy and economics of staging by computed tomography and surgery. *Gastroenterology*. 1981; 80:45–50.
8. Dehn TCB, Reznick RH, Nockler IB, White FE. The preoperative assessment of advanced gastric cancer by computed tomography. *Br J Surg*. 1984; 71:412–7.
9. Vallgren S, Hedenbro J, Göteborg S, Walther B. Preoperative computed tomography for evaluation of tumor growth

- patients with gastric cancer . Acta Chir Scand. 1985; 151(6):571-3.
10. Frasier J, Nash R, James DC. Computed tomography in gastric cancer (letter). Br J Surg. 1985; 72:249.
 11. Cook AO, Levine BA, Sirinek KR, Gaskill HV. Evaluation of gastric adenocarcinoma: abdominal computed tomography does not replace celiotomy. Arch Surg. 1986; 121: 603-6.
 12. AEM Hameed, AH Ghazal Diagnosis of gastric cancer with Multidetector CT: correlation with surgical and histopathologic findings .Bull. Alex Fac med.45 No.3, 2009
 13. Zhong BY, Liu YX, Huang WF, Liu QQ, Liu SQ, Liu Y. [Clinical value of 64-slice spiral 3-phase CT enhanced scanning for preoperative TNM staging assessment of gastric carcinoma]. Zhonghua Wei Chang Wai Ke Za Zhi. 2012 Jul; 15(7):706-9.
 14. Zompetta C, Catarci M, Poletti E [Diagnostic accuracy of computerized tomography. Preoperative staging of gastric cancer] Clin Ter. 1995 Dec; 146(12):825-41.
 15. Kim JW, Shin SS, Heo SH, Choi YD, Lim HS, Park YK, Park CH, Jeong YY, Kang HK. Diagnostic performance of 64-section CT using CT gastrography in preoperative T staging of gastric cancer according to 7th edition of AJCC cancer staging manual. Eur Radiol 2012; 22: 654-662 [PMID: 21965037 DOI: 10.1007/s00330-011-2283-3]
 16. Kwee RM, Kwee TC. Imaging in assessing lymph node status in gastric cancer. Gastric Cancer 2009; 12: 6-22 [PMID: 19390927 DOI: 10.1007/s10120-008-0492-5]
 17. Grenacher L, Hansmann J. [Radiological imaging of the upper gastrointestinal tract. Part II. The stomach]. Radiologic. 2007 Jan; 47(1):71-88.
 18. Chen CY, Hsu JS, Wu DC, Kang WY, Hsieh JS, Jaw TS, Wu MT, Liu GC. Gastric cancer: preoperative local staging with 3D multi-detector row CT--correlation with surgical and histopathologic results. Radiology 2007; 242: 472-482 [PMID: 17255419 DOI: 10.1148/radiol.2422051557]
 19. F. D'Elia, A. Zingarelli, D. Palli, M. Grani Hydro-dynamic CT preoperative staging of gastric cancer: correlation with pathological findings. A prospective study of 107 cases European Radiology November 2000, Volume 10, Issue 12, pp 1877-1885
 20. Chamadol N , Wongwiwatchai J, Bhudhisawasd V, Pairojkul C Accuracy of spiral CT in preoperative staging of gastric carcinoma: correlation with surgical and pathological findings J Med Assoc Thai. 2008 Mar; 91(3):356-63
 21. Bang-Bin Chen, Po-Chin Liang, Kao-Lang Liu, Jong-Kai Hsiao, Preoperative Diagnosis of Gastric Tumors by Three-dimensional Multidetector Row CT and Double Contrast Barium Meal Study: Correlation with Surgical and Histologic Results [J Formos Med Assoc 2007;106(11):943-952].