



## Viral Conjunctivitis- A Clinical Study

Authors

**Dr Jasmin L.B<sup>1</sup>, Dr Nivedita Nair<sup>2</sup>**

<sup>1</sup>Assistant Professor Department of Ophthalmology, RIO, Government Medical College Trivandrum, Kerala

<sup>2</sup>Senior Resident Department of Ophthalmology, RIO, Government Medical College Trivandrum Kerala

Corresponding Author

**Dr Jasmin L B**

Assistant Professor, Department of Ophthalmology, RIO, Government Medical College Trivandrum, Kerala

Email: [jasminbennet.bennet@gmail.com](mailto:jasminbennet.bennet@gmail.com)

### Abstract

**Introduction:** According to WHO, corneal diseases are responsible for nine per cent of all blindness in India. Viral keratitis has become more prevalent now. Adenovirus is the most common cause and tends to become epidemic. It can cause nummular corneal opacities impairing visual function significantly.

**Objective:** 1. To find out commonest etiological agent of viral conjunctivitis.

2. To determine the most common serotype of adenovirus causing corneal opacity.

**Materials and Methods:** A cross sectional study was conducted for one year with informed consent among 100 patients attending the Regional Institute of Ophthalmology, Thiruvananthapuram with clinical features suggestive of Viral Conjunctivitis. Detailed clinical evaluation followed by collection of two conjunctival swab for Gram's staining and for Polymerase chain reaction was done for each patient. PCR sequences obtained were edited in Bio Edit software (V.7.0.9.0) and compared with adenoviral sequences present in GenBank using the BLAST-N program (version 2.2.18). The patients were further followed up weekly until the conjunctivitis resolved. Clinical course of the corneal lesion was followed up for three months.

**Results:** The major ocular symptoms were redness (100%), pain (59%), watering (56%) and mucoid discharge (41%). Fifty six per cent of the patients had pre-auricular lymph node enlargement. The most common conjunctival findings was acute follicular conjunctivitis with fine petechial hemorrhages (45.8%). Viral PCR was positive in 24 per cent of patients and subtyping showed adenovirus 8 (70.8%), adenovirus 3 (16.6%), adenovirus 19 (8.3%) and adenovirus 24 (4.16%). Twenty one per cent of the patients developed superficial punctate epitheliopathy. Of these, 75 per cent were viral PCR positive. Fifteen per cent of the patients had persistent subepithelial opacity at the end of three months.

**Conclusion:** Viral conjunctivitis is a common ocular condition among the outpatients. The present study shows that Adenovirus 8 was the most common etiological agent causing viral conjunctivitis and most common serotype causing corneal subepithelial opacities which affect the visual clarity.

**Keywords:** Corneal lesions ,etiological agent, Allergic conjunctivitis , chronic conjunctivitis.

### Introduction

According to WHO, corneal diseases are the second most common cause of blindness in the world today. Corneal lesions are responsible for nine percent of all blindness in our country.

Majority of the causes of blinding corneal pathology are avoidable or preventable or treatable. In the present era with improved nutrition and due to the advent of effective antimicrobials, infective keratitis of non-viral

origin is on the decline whereas viral keratitis has become more prevalent.

A variety of viruses can be responsible for conjunctival infection. Adenovirus is the most common and is highly contagious during the first 2 weeks of infection. It has the tendency to occur in epidemics known as Epidemic keratoconjunctivitis. The 54 types of adenovirus now known to be pathogenic in man. They are highly resistant to environmental influences and can survive contact with many of the usual commercially available types of disinfectant.

Ocular adenoviral infections are characterized by highly distressing local symptoms. It can occur with corneal involvement within 4-5 days after the onset of symptoms. The corneal lesions range from diffuse fine superficial punctate keratitis to epithelial defects and finally to sub epithelial nummular opacities which may last for years. These nummular opacities can impair visual function significantly and can cause glare.

Currently no specific antiviral therapy is available to shorten the course of infection or to improve distressful clinical symptom, to stop viral replication and to avoid the development of corneal opacities. Research is ongoing for topical agents that have anti-viral activity.

The rationale behind this clinical research is that there are only few studies available so far that has determined the incidence and prevalence of adenoviral conjunctivitis, the common subtypes of adenovirus causing viral conjunctivitis and subsequent corneal lesion in Kerala population. Identifying common serotypes and clinical profile of the viral conjunctivitis will help the health care system to plan programs in event of epidemics and impart awareness in population to prevent the spread of infection.

## Aims and Objectives

### Objective

1. To find out commonest etiological agent of viral conjunctivitis.
2. To determine the most common serotype of adenovirus causing corneal opacity.

## Materials and Methods

**Study Design:** Cross Sectional Study

**Study Setting:** Outpatient unit of Regional Institute of Ophthalmology

**Study Population:** Patients attending Regional Institute of Ophthalmology, Thiruvananthapuram Outpatient Department with symptoms and signs suggestive of acute conjunctivitis during the study period. Patients in all age group of either gender were included in the study.

### Exclusion Criteria

- Allergic conjunctivitis & other chronic conjunctivitis
- Partially treated patients with pre-existing corneal lesion
- Patient not willing for follow up.

**Study Period:** January 2013-January 2014.

**Sample Size:** 100 patients

**Sampling Technique:** Consecutive sampling.

**Methodology:** A cross sectional study was conducted for one year with informed consent among 100 patients attending the Outpatient Department of Regional Institute of Ophthalmology, Thiruvananthapuram with clinical features suggestive of Acute Conjunctivitis. Detailed clinical evaluation including history, clinical feature, visual acuity, slit lamp examination and other system examination, was carried out. Two conjunctival swabs were taken from inferior tarsal conjunctiva and fornices under topical anaesthesia and under strict asepsis to avoid contamination of specimen. One swab was sent for Gram's staining to rule out bacterial conjunctivitis and the other swab was stored in viral transport medium at appropriate temperature until it was transported for Polymerase chain reaction to confirm diagnosis of viral conjunctivitis and also to subtype the virus. The PCR was done in collaboration with the Rajiv Gandhi Centre for Biotechnology, Jagathy, Thiruvananthapuram. PCR sequences obtained were edited in Bio Edit software (V.7.0.9.0) and compared with adenoviral sequences present in Gen Bank using the BLAST-N program (version 2.2.18). Patients were reviewed at first week to

look for corneal involvement. Patient were assessed on the basis of a questionnaire which includes the level of improvement of symptoms while on treatment, symptoms that suggests corneal involvement, family members/ contacts having similar complaints followed by clinical evaluation using slit lamp examination to look for corneal lesion. The patients were further followed up weekly or once in 2 weeks until the conjunctivitis has resolved. Corneal lesion will be assessed in each follow up. Clinical course of the corneal lesion will be followed up with current treatment for up to 3 months. Patients in whom corneal lesion had resolved at 3 weeks or at 1 month review, there were no further follow ups.

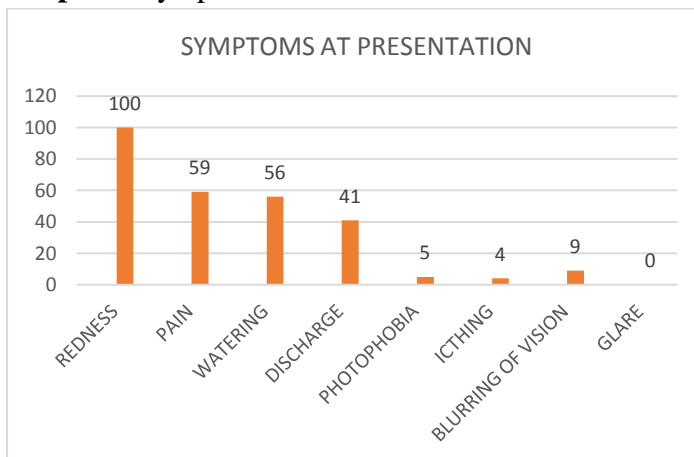
**Statistical Analysis**

Data entry was done in Microsoft Excel and statistical analysis was done using SPSS version 17. Proportion of different viruses and serotypes was expressed in percentage.

**Observations and Results**

Age of study population ranged from 3years to 77years, mean age was 34.31years. Majority of patients were in the age group 20-40years (48%). In this study, 59% males. Presentation was unilateral in 90%. 16% of study patients had coryza along with ocular symptoms. 37% had contact history from either family members or friends.

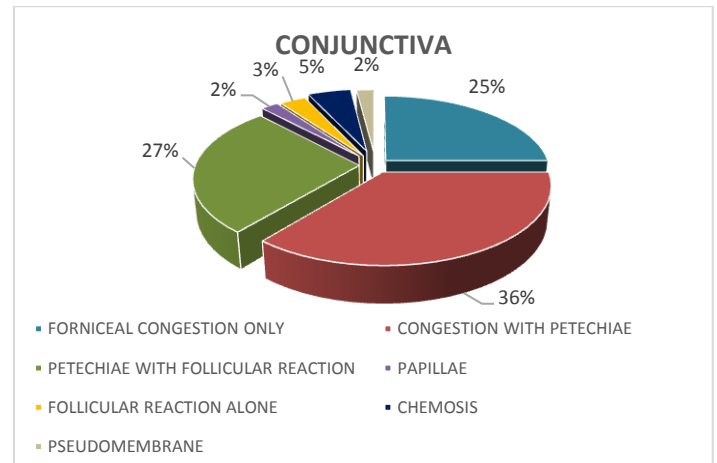
**Graph-1: Symptoms at Presentation**



Redness (100%), Pain (59%), Watering (56%) and Mucoïd discharge (41%) were the predominant features.

93% patients presented within 7days of onset of symptoms of which 48% presented within 3 days.

**Graph- 2: Findings in Conjunctiva**



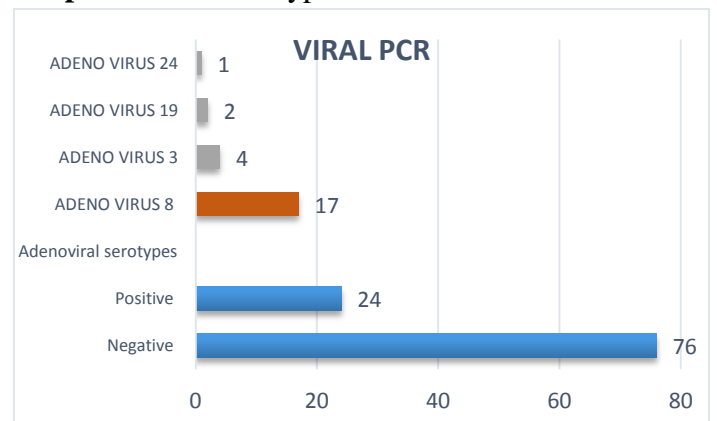
The predominant feature noted in the conjunctiva was fine petechiae in the upper and lower tarsal conjunctiva which was seen 36% of patients. Petechaie with follicular reaction of conjunctiva was present in 27% of patient.

Corneal sensation was reduced in 12%. Two third of these cases where positive on Adenoviral PCR (n=8) of which half (n=4) was adenovirus 8.

No cases of anterior uveitis were noted. 56% of patients had preauricular lymph node enlargement which was statistically significant (p=0.007).

Viral PCR was positive in 24% of patients, all were adenovirus positive.No cases of Herpes Simplex Virus, Ebstein Barr Virus or Enterovirus were isolated.

**Graph-3: Viral Serotypes Isolated**



Adenovirus 8 (70.8%) [n=17] was the most common serotype isolated. Other serotypes were

Adenovirus 3 (17%) [n=4], adenovirus 19 (8%) [n=2], adenovirus 24 (4%) [n=1].

**Table-1:** Corneal Findings in Viral, Bacterial And Nonidentified Conjunctivitis

CORNEA		PCR (N=24)		Bacterial (N=14)		Nonspecific (N=62)		Total (N=100)	
		N	%	N	%	N	%	N	%
1 week	Clear	6	25	14	100	61	98.4	81	81
	SPK	18	75	0	0	1	1.6	19	19
3 week	Clear	5	20.8	14	100	60	96.8	79	79
	SPK or SE opacity	19	79.2	0	0	2	3.2	21	21
1 month	Clear	5	20.8	3	21.4	15	24.2	23	23
	SPK or SE opacity	17	70.8	0	0	2	3.2	19	19
3 month	Clear	5	20.8	3	21.4	1	1.6	9	9
	SE opacity	14	58.3	0	0	1	1.6	15	15

21% of patients had keratitis which was characterized by superficial punctate epitheliopathy.15% of these patients had subepithelial opacity at the end of 3 month follow up which interfered with visual clarity which included mild blurring of vision and glare.

Statistical analysis was done (Fisher's Exact test) of the corneal involvement between PCR positive and nonspecific conjunctivitis cases at 1 week, 3 week and 1 month review(  $\chi^2 = 16.472$ ), it was statistically significant ( $p < 0.001$ ).

**Discussion**

The results are based on analysis of 100 cases. Majority of study group was between the age group 20-40 years (48%). Children and young adults constituted 20% (below 20 years). Similar results were obtained in studies done by Dr. Sheeja Viswanath et al and Aoki Koki et al<sup>[2,3]</sup>. In the study done by Dr. Sheeja Viswanath et al<sup>[2]</sup> Maximum Age Incidence was between 20-40 yrs (40 %) followed by 40-60 yrs (27%). In the study by Aoki Koki et al<sup>[3]</sup>, 20-39 age group being the most common.

In our study 59% were males and 41% were females. Similar results were obtained in the study by Dr. Sheeja Viswanath et al <sup>[2]</sup>, out of 55 patients they studied 29 (52.72%) were males and 26 (47.28%) were females. The slightly higher

prevalence in males is due to the fact that males are more involved in outdoor activities.

In this study, 47% involved the right eye and 43% involved the left eye.10% involved both eyes at presentation. In the study done by Dr. Sheeja Viswanath et al <sup>[2]</sup>, higher rates of bilaterality was reported (40%). In the study,<sup>[4]</sup> reported that 87% of cases were unilateral.

In our study upper respiratory symptoms with or without fever was seen in 16%. Similar reports were seen in the study done by Dr. Sheeja Viswanath et al <sup>[2]</sup>, were coryza and fever occurred in 20%. In the study <sup>[4]</sup>, 26.1% had rhinitis or sore throat during the clinical course.

In this study 37% reported contact with family member or friends or colleague. 63% of patients didn't give any history of contact with conjunctivitis. Similar reports were obtained in the study by Uchio E et al <sup>[4]</sup>, were they reported that the source of infection was contact with patients with similar illness which was seen in 30.4%.

In our study the symptoms noted were redness (100%), pain (59%), watering (56%), mucoid discharge (41%), blurring of vision (9%), photophobia (5%) and itching (4%) in the affected eye. In the study by Uchio E et al <sup>[4]</sup>, 82.6% complained of discharge, and 52.2%, 39.1%, and 30.4% complained of itching, sensation of foreign body, and lacrimation, respectively. In the study done by Dr. Sheeja Viswanath et al <sup>[2]</sup>, eye ache,

foreign body sensation, watering and discharge were present in all cases.

93% of patients presented within one week of onset of symptoms, of which 48% presented within 3 days of onset. Dr. Sheeja Viswanath et al<sup>[2]</sup> reported that 60 % visited OPD on the first six days of illness and 40% on 2<sup>nd</sup> and 3<sup>rd</sup> week after getting some treatment outside.

All patients had conjunctival congestion predominantly of for nices. Congestion of the fornix alone was present in 25%. The predominant feature noted in the conjunctiva was fine petechial hemorrhages in the upper and lower tarsal conjunctiva which was seen 36% of patients. Petechaie with follicular reaction of conjunctiva was present in 27% of patient. Thus more than half of the patients (63%) had petechiae. 3% of patients had an isolated follicular reaction in the conjunctiva. Thus 30% of patients had acute follicular conjunctivitis. The most common conjunctival finding noted in adenoviral positive cases were acute follicular conjunctivitis with fine petechial hemorrhages in tarsal conjunctiva (11 out of 24). Only one case had keratitis (SPK) at presentation to hospital. No case of uveitis were seen in this study group. Dr. Sheeja Viswanath et al<sup>[2]</sup> reported conjunctival congestion and conjunctival follicles in all patients (100%), Sub conjunctival hemorrhage was present in 10.90% and Petechial hemorrhage in 63.63 %. No cases of uveitis were reported in their study.

Corneal sensation was reduced in 12%. Of these, 66.6% were positive for adenoviral PCR (33.3% was adenoviral 8). None of these patients had any dendritic corneal lesion .This was found to be statistically significant in bivariate analysis. (p=0.0009)

In our study 56% of patients had preauricular lymph node enlargement. Of these 83.3% was adenoviral PCR positive. This was found to be statistically significant (p=0.007). 76.4% patients with adenovirus 8 positive had preauricular lymphadenopathy. 2 patients had enlarged submandibular lymph node. In the study by Aoki Koki et al<sup>[3]</sup>, the frequency of preauricular lymphadenopathy was 20-34% in adenoviruses 3

and 4 infections and higher occurrence 44-64% was noted in adenoviruses 8 and 19 infections. While Dr. Sheeja Viswanath et al<sup>[2]</sup> reported 43.63% cases with preauricular lymphadenopathy in their study. In the study by Uchio E et al<sup>[4]</sup>, 43.5% had enlarged preauricular nodes at the first visit. No submandibular or cervical lymphadenopathy was observed.

In our study, Gram staining showed three cases with gram positive cocci. Viral PCR was positive in 24% of patients. Of which 70.8% (n=17) was adenoviral 8. 16.6% (n=4) adenoviral 3, 8.3% (n=2) was adenoviral 19. 4.16% (n=1) was adenoviral 24. In the study done by Dr. Sheeja Viswanath et al<sup>[2]</sup>, viral culture was positive in 40 % cases and was found to be Adenovirus type 8. This was during an outbreak. In the study by Aoki Koki et al<sup>[3]</sup>, adenoviral isolation was 56%. Of which 63.8% was adenoviral 8, 12.3% adenoviral 3, 16.4% adenoviral 4, 7.7% adenoviral 19.

In the present study 21% of patients had keratitis which was characterized by superficial punctate epitheliopathy. 15% of these patients had subepithelial opacity at the end of 3 month follow up which interfered with visual clarity which included mild blurring of vision and glare. 6% of patients had clear cornea at the end of 3 months of follow up.

Among viral PCR positive cases, 75% (n= 18) developed keratitis at 1 week follow up. 77.7% (n=14) of these cases were adenovirus 8 positive. This was found to be statistically significant (p<0.001). 10.5% (n=2) of patients developed sub epithelial opacity at 3 weeks follow up. A case of adenovirus 3 developed SPK at 3week follow up. In 11.67% (n=2) of adenovirus 8, superficial punctate keratitis persisted for 1 month. 58.8% (n=10) of SPK in adenovirus 8 developed subepithelial opacity at 1 month of which 52.9% (n=9) had persistent corneal opacity.

Dr. Sheeja Viswanath et al<sup>[2]</sup>, reported keratitis in 10.8%. While Aoki Koki et al<sup>[3]</sup>, reported higher rates of keratitis in their study of 54.19%, of which 60.6% was due to adenovirus 8. They found that keratitis caused by adenoviruses 3 or 4 was significantly less frequent (9% or 27%) than

that caused by adenoviruses 8 or 19. While in the study by Uchio E et al [4], comparable results to our study with corneal involvement occurring in 30.8%.

### Conclusion

- 1) Majority of patients were in the age group 20-40 years (48%).
- 2) Males were more affected (59%).
- 3) The presentation was unilateral in 90% and bilateral in 10%.
- 4) 16% of study patients had coryza along with ocular symptoms.
- 5) 37% had contact history from either family members or friends.
- 6) Redness was present in all patients. Apart from redness, pain (59%), watering (56%) and mucoid discharge (41%) were the predominant feature.
- 7) 93% of patients presented to hospital within 7 days of onset of symptoms, of which 48% of patients presented within first 3 days.
- 8) All patients had conjunctival congestion predominantly of fornices. The predominant feature noted in the conjunctiva was fine petechiae in the upper and lower tarsal conjunctiva which was present in more than half of the patients (63%). 30% of patients had follicular conjunctivitis.
- 9) Cornea was clear in all patients at presentation but corneal sensation was reduced in 12%. This was statistically significant.
- 10) There was no evidence of anterior uveitis noted in this study group.
- 11) 56% of patients had preauricular lymph node enlargement. Presence of preauricular lymph node enlargement was found to be statistically significant ( $p=0.007$ ).
- 12) Viral PCR was positive in 24% of patients. Of the 24 cases only adenovirus was identified. No cases of Herpes Simplex Virus, Epstein Barr Virus or Enterovirus was isolated.

- 13) Adenovirus 8 (70.8%,  $n=17$ ) was the most common serotype isolated.
- 14) Other serotypes isolated were adenovirus 3 (17%), adenovirus 19 (8%) and adenovirus 24 (4%).
- 15) 95% patients were treated with only topical antibiotics.
- 16) 21% of patients had keratitis which was characterized by superficial punctate epitheliopathy. 15% of these patients had subepithelial opacity at the end of 3 month follow up which interfered with visual clarity due to mild blurring of vision and glare.
- 17) 75% ( $n=18$ ) of viral PCR positive cases developed keratitis at 1 week follow up. 77.7% ( $n=14$ ) of these cases were adenovirus 8 positive. This was found to be statistically significant.
- 18) 52.9% ( $n=9$ ) had persistent subepithelial opacity at the end of three month follow up.

Viral conjunctivitis is a common ocular condition among the outpatients in ophthalmology clinics. The present study shows that Adenovirus 8 was the most common etiological agent causing viral conjunctivitis and most common serotype causing corneal subepithelial opacities which affect the visual clarity.

### References

1. Conjunctivitis. I. Follicular, neonatal, and bacterial. In: Arffa RC, ed. Grayson's diseases of the cornea, 3rd ed. St Louis: Mosby; 1991.
2. Dr. Sheeja Viswanath MS, Dr. K S Chandrakanth DO DNB, Prof. (Dr). P. Vijayan MS, Prof. (Dr). Venkitachalam MS, Dr. Nirupama Balaji DO DNB, Dr. Tresa Mathew MS, Dr. Ramakrishnan MS Clinical and Virological Study of Conjunctivitis during the Epidemic in Calicut October – December 2006 June 2008 Kerala Journal of Ophthalmology Vol. XX, No. 2.

3. Koki Aoki, Michio Kato, Hideo Ohtsuka, Keizo Ishii, Naoki Nakazono, And Harumi Sawada. Clinical and aetiological study of adenoviral conjunctivitis, with special reference to adenovirus types 4 and 19 infections. British Journal of Ophthalmology, 1982, 66, 776-780.
4. Uchio E, Takeuchi S, Itoh N, et al: Clinical and epidemiological features of acute follicular conjunctivitis with special reference to that caused by herpes simplex virus type 1. Br J Ophthalmol 2000; 84:968-972.
5. Tabery H: Corneal epithelial changes due to adenovirus type 8 infection. ActaOphthalmolScand 2000; 78:45-48.
6. Elnifro EM, Cooper RJ, Klapper PE, et al: Multiplex polymerase chain reaction for diagnosis of viral and chlamydial keratoconjunctivitis. Invest Ophthalmol Vis Sci 2000; 41:1818-1822.
7. Conjunctivitis: A Systematic Review of Diagnosis and Treatment JAMA. 2013 October 23; 310(16): 1721–1729.
8. Remco P Rietveld, Henk C P M vanWeert, Gerbenter Riet, Patrick J E Bindels. Diagnostic impact of signs and symptoms in acute infectious conjunctivitis: systematic literature search BMJ Volume 327 4 October 2003.