



## The Study on Chronic Discharging Ear and Multiple Cranial Nerve Paresis

Authors

**Dr Ratnesh Kumar<sup>1</sup>, Dr Preeti Sharma<sup>2</sup>, Dr Chandan Kumar<sup>3</sup>, Dr Satish Kumar<sup>4</sup>**

<sup>1,2</sup>Senior Resident, Department of ENT, Patna Medical College & Hospital, Patna

<sup>3</sup>Senior Resident, Department of ENT, Nalanda Medical College & Hospital, Patna

<sup>4</sup>Professor & HOD, Department of ENT, Patna Medical College & Hospital, Patna

Corresponding Author

**Dr Ratnesh Kumar**

Senior Resident, Department of ENT, Patna Medical College & Hospital, Patna

### ABSTRACT

*A female patient 30 years old, mother with one child, housewife with no special habits of medical importance complained of deviation of the angle of the mouth to the right side of two days' duration. Lacrimation of the left eye and difficulty in closing the left eye were present for two days, for which she had consulted a neurologist. She had a past history of chronic left ear discharge, tinnitus, and decrease in hearing acuity of left ear.*

*General examination revealed no detectable abnormalities. Neurological examination revealed left trigeminal nerve palsy, sensory along three divisions. Corneal reflex was absent. There was decrease hearing acuity of left ear especially sensory neural affection. Left facial and hypoglossal nerves were affected. Long tract was not affected. High resolution power CT for left ear, and MRI brain with contrast were normal. ESR, CBC, C-RP were Normal.*

*Sarcoidosis battery revealed elevated serum calcium, and Angiotensin converted enzyme (ACE) with elevated CSF ACE. The patient was treated with Methyl prednisolone 100mg/day in divided doses, Calcium supplement OD and Pantazole PBI 40 mg/day, and given physiotherapy. Recovery was seen within two weeks.*

**Keywords:** *Multiple cranial nerves injury, viral encephalitis, neuro-sarcoidosis cranial neuropathy, steroids responsive neuropathy.*

### INTRODUCTION

Most studies of multiple cranial neuropathies address specific causes in small groups of cases, with emphasis on benign recurrent cranial neuropathy. Although only 5-15% of sarcoidosis patients develop neurosarcoidosis, in 50% of cases neurological involvement may be the first manifestation of the disease.

Neurosarcoidosis occurs particularly in females and involves multiple cranial neuropathies (II and

VII) (53%), hypothalamic dysfunction, intracerebral mass lesions, chronic aseptic basilar meningitis (22%) (can lead to hydrocephalus), encephalopathy, spinal cord lesions (meningeal or intramedullary) with radicular involvement, neuropathy (mononeuropathy including truncal nerves, acute multifocal or purely sensory or sensorimotor polyneuropathy) (17%), and myopathy (15%).

A female patient 30 years old, mother with one child, housewife with no special habits of medical importance presented with complaints of deviation of the angle of the mouth to the right side for two days. Lacrimation of left eye and difficulty in closing the left eye had been present for two days, for which she had consulted a neurologist. A past history of chronic left ear discharge, tinnitus, and decrease in hearing acuity of left ear was present.

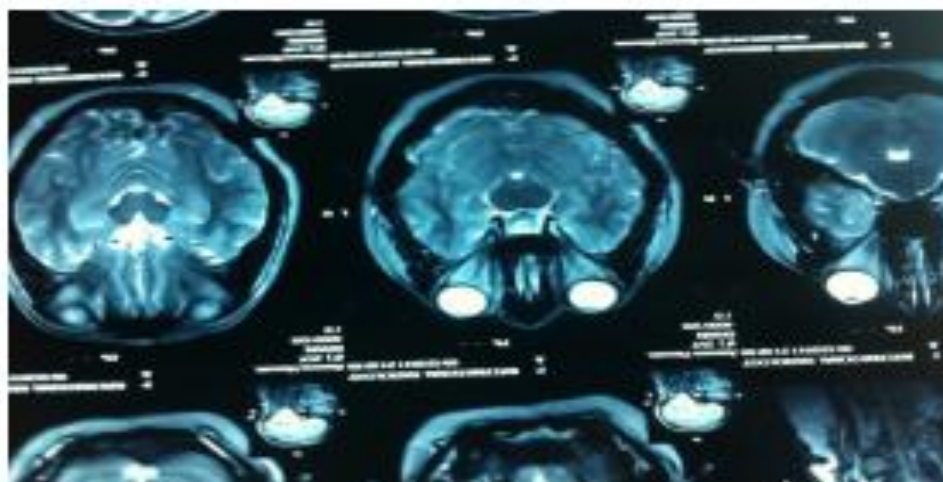
### Examination findings

General examination revealed no detectable abnormalities. Neurological examination revealed left trigeminal nerve palsy, sensory along three divisions. Corneal reflex was absent. There was decrease hearing acuity of left ear especially

sensory neural affection. Left facial and hypoglossal nerves were affected. Long tract was not affected. ENT examination showed no clear cut evidence of cholesteatoma apart from crusts, and HRCT showed no evidence of cholesteatoma. MRI brain was normal.

### INVESTIGATIONS

The investigations done included high resolution power CT for left ear, which was normal, and MRI brain with contrast, too was normal. In addition laboratory investigations showed normal ESR, CBC, C-RP. Sarcoidosis battery showed elevated serum calcium, and angiotensin converted enzyme (ACE) with elevated CSF ACE



**Figure 1:** Normal MRI brain

Management included methyl prednisolone 100mg/day in divided doses Calcium supplement OD, and Pantazole PBI 40 mg/day and physiotherapy. The patient showed full recovery within 2 weeks.

### DISCUSSION

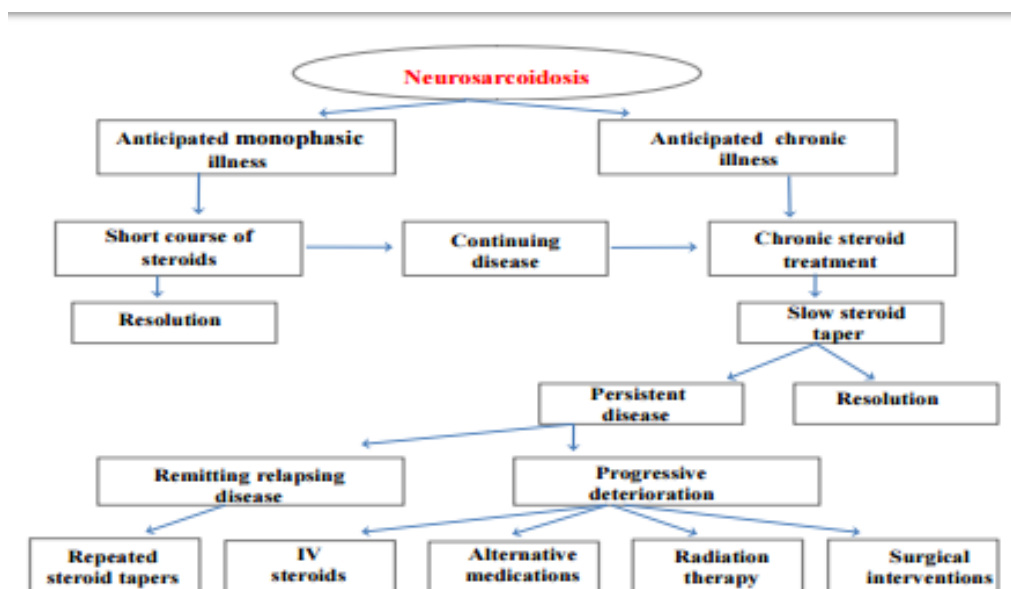
Multiple cranial nerve injury has a long list for differential diagnosis. However in this case the following differential diagnosis is more practical: Cholesteatoma, based on history of chronic left ear discharge and decrease hearing acuity), Cerebello-pontine angle lesions (CPA) which includes Petrous bone meningioma, Trigeminal schwannoma, Cholesteatoma, Acoustic neuroma).

Neurosarcoidosis, Vasculitis and Viral cranial nerve lesion.

The presence of chronic left ear discharge and decreased hearing acuity is suggestive of focal lesion with intracranial extension such as cholesteatoma, schwannoma or cerebello-pontine angle tumor (CPA). On the other hand, the presence of left trigeminal sensory affection and left hypoglossal affection is suggestive of disseminated lesion as sarcoidosis, vasculitis. Many investigations such as High resolution power CT (HRCT) of left ear and MRI brain with contrast were done to detect the possibility of a focal lesion with intracranial extension.

All results were negative. In this case the steroid response is considered as a therapeutic test for confirmation of sarcoidosis. Neurosarcoidosis (sometimes shortened to neurosarcoid) refers to sarcoidosis, a condition of unknown cause featuring granulomas in various tissues, involving the central nervous system (brain and spinal cord)<sup>1</sup>.

Approximately 5-10% of people with sarcoidosis of other organs (e.g. lung) develop central nervous system involvement. Only 1% of people with sarcoidosis will have neurosarcoidosis alone without the involvement of any other organs (isolated neurosarcoid).



**Figure 2:** Protocol of treatment of Neurosarcoidosis

The first case of sarcoidosis involving the nervous system was reported in 1948<sup>2-3</sup>. Abnormalities of the cranial nerves are present 50-70% of cases. The most common abnormality is involvement of the facial nerve, followed by reduction in visual perception due to optic nerve involvement. Rarer symptoms are double vision (oculomotor nerve, trochlear nerve or abducens nerve), decreased sensation of the face (trigeminal nerve), hearing loss or vertigo (vestibulocochlear nerve), swallowing problems (glossopharyngeal nerve) and weakness of the shoulder muscles (accessory nerve) or the tongue (hypoglossal nerve)<sup>1</sup>. The diagnosis of neurosarcoidosis is often difficult. Definitive diagnosis can only be made by biopsy. Because of the risks associated with brain biopsies, they are avoided as much as possible. Other investigations that may be performed in the presence of any of the symptoms mentioned above are computed tomography (CT)

or magnetic resonance imaging (MRI) of the brain, lumbarpuncture, electroencephalography (EEG) and evoked potential (EP) studies. If the diagnosis of sarcoidosis is suspected, typical X-ray or CT appearances of the chest may make the diagnosis more likely.

Elevations in angiotensin-converting enzyme and calcium in the blood, too, make sarcoidosis more likely. In the past, the Kveim test was used to diagnose sarcoidosis. This, now obsolete, test had a high (85%) sensitivity, but required spleen tissue of a known sarcoidosis patient, an extract of which was injected into the skin of a suspected case. Neurosarcoidosis, once confirmed, is generally treated with glucocorticoids such as prednisolone. In addition to Methotrexate, hydroxychloroquine, cyclophosphamide, pentoxifylline, thalidomide and infliximab have been reported to be effective in limited studies.

In patients unresponsive to medical treatment, radiotherapy may be required. If the granulomatous tissue causes obstruction or mass effect, neurosurgical intervention is sometimes necessary. Seizures can be prevented with anticonvulsants, and psychiatric phenomena may be treated with medication usually employed in these situations.

### CONCLUSION

Isolated neurosarcoidosis could be a reason for multiple cranial nerve injuries, with good response to steroids.

### REFERENCES

1. Joseph FG, Scolding NJ. "Sarcoidosis of the nervous system". Practical neurology 2007;7(4):234-44.
2. Colover J. "Sarcoidosis with involvement of the nervous system". Brain 1948;71(4):451-75.
3. Burns TM. "Neurosarcoidosis". Archives of neurology August 2003;60(8):1166-8.
4. Waruiru C, Appleton R. Febrile seizures: an update. Arch Dis Child. 2004; 89(8): 751-6.
5. Abuexteish F, Daoud As, Alsheyyab M, Non'man M. Demographic characteristics and risk factor of first febrile seizure: a Jordanian experience. J Trop Doct. 2000; 30(1) :25-7.
6. Mikati MA. Seizures in Childhood. In: Menrman ER, ligman RM, Jenson M. Nelson text book of pedaitrics.19th ed. Philadelphia: Suarderscompany; 2011. P. 2017.
7. Humite Haddad A, About-Khalid B. Epilepsy diagnosis and localization in patients with antecedent childhood febrile convulsions. Neurology, 1998; 50(4): 917-22.
8. Nakayama J, Hamano K, Iwasaki N, Nakahara S, Horigome Y, Saitoh H, et al. Signification evidence for the linkage of febrile seizures to chromosome. Hum. Mol. Genet.(2000; 9(1): 87-91.
9. Evans OB, Ingram JB. Top 10 facts you need to know about febrile seizures. J Miss State Med Assoc. 2011; 52(11): 346-7.
10. Auvichayapat P, Auvichayapat N, Jedsrisuparp A, Thinkhamrop B, Sriroj S, Piyakulmala T, et al. Incidence of febrile seizures in thalassemic patients. J Med Assoc Thai. 2004; 87(8): 970-3.