

**Original Article**

Role of F-18 FDG PET/CT to Identify Potential Primary Lesion in Carcinoma of Unknown Primary Site (CUPS)

Authors

**Sumit Agarwal¹, Anurag Jain², IP Dubey³, Rajeev Kumar⁴, Amit Sharma⁵,
Braj Kishore⁶, Arun Ravi John⁷, MG Vishnoi⁸, Dharmesh Paliwal⁹, Neeraj¹⁰,
Aniruddha G Pandit¹¹**

¹MBBS, DNB in Nuclear Medicine, Graded Specialist Nuclear Medicine, Army Hospital R and R, Delhi 110010, Email: rinku4994@yahoo.com

²MBBS, DNB in Nuclear Medicine, Graded Specialist Nuclear Medicine, Army Hospital R and R, Delhi 110010

³MBBS, DNB in Nuclear Medicine, Graded Specialist Nuclear Medicine, Army Hospital R and R, Delhi 110010, Email: pradeep_4926@rediffmail.com

⁴MBBS, DNB in Nuclear Medicine, Graded Specialist Nuclear Medicine, Army Hospital R and R, Delhi 110010, Email: rajeevakhariya@rediffmail.com

⁵MBBS, DRM in Nuclear Medicine, MO Nuclear Medicine, Army Hospital R and R, Delhi 110010
Email: amitsunitably@gmail.com

⁶Graded Specialist Nuclear Medicine, Army Hospital R and R, Delhi 110010

⁷MBBS, DNB resident Nuclear Medicine, Army Hospital R and R, Delhi 110010
arun_medico2003@yahoo.co.in

^{8,9,10}MBBS, DNB resident Nuclear Medicine, Army Hospital R and R, Delhi 110010

¹¹MBBS, MD, DRM, Senior Advisor Nuclear Medicine, Army Hospital R and R, Delhi 110010

Corresponding Author

Anurag Jain (MBBS, DNB in Nuclear Medicine)

Graded Specialist Nuclear Medicine, Army Hospital R and R, Delhi 110010

Email: triplea.jain@gmail.com, Mobile: 09540158095

Introduction

Carcinoma of unknown primary is a clinical state of presenting illness where there is confirmed presence of metastatic disease and primary tumor is not identified. Between 2 to 5 % of all carcinoma patients are diagnosed with carcinoma of an unknown primary tumor. The criteria for term CUPS is a histopathologically proven malignancy for which the anatomic primary is not known after detail evaluation of the patient's

history, physical examination, biochemistry, chest radiographs, computed tomography of the chest, abdomen and pelvis, mammography (in females) and serum prostate specific antigen (in males).¹ CUPS ranks as the seventh most frequent type of cancer in the world and the fourth most common cause of cancer deaths which represent both diagnostic and management challenges.²

The regression or dormancy of the primary tumor, the development of early, uncommon, systemic

metastases and the resistance to therapy are hallmarks of the heterogeneous clinical entity. Although it is widely accepted that CUPS is a heterogeneous cohort of metastatic malignancies, no consensus exists yet on the true nature of this entity.³

Histological types of CUPS.⁴

1. Well to moderately differentiated adenocarcinoma (60%)
2. Poorly differentiated adenocarcinoma (30%)
3. Squamous cell carcinoma (5%)
4. Neuroendocrine (2%)
5. Undifferentiated (3%)

While histopathologic analysis frequently provides hints as to the location of the primary site, not all tumors are identified despite a comprehensive diagnostic workup. Imaging with CT/MRI and other tumor markers the primary could be detected only in 20-27 % and even at autopsy primary site is detected in only 30-62% of patients.⁵

There are several causes of the low rate of detection of the primary. It is hypothesized that in patients who present with CUPS, the primary tumor either remains microscopic and escapes clinical detection or disappears after seeding the metastasis because its angiogenetic incompetence leads to marked apoptosis and cell turnover. Furthermore the sensitivity of conventional diagnostic procedure may not be satisfactory. The inability to detect primary, prevents the optimization of therapeutic strategies, which is dependent on tumor differentiation, tumor location and tumor stage as determined according to the TNM staging system, hence patient prognosis is negatively affected and we need a new investigation tool to detect primary site.⁶

Positron Emission Tomography (PET) is a imaging technique and has been widely used in oncologic diagnosis and response assessments (8). It produces a three dimensional image or map of functional processes in the body. Fluoro Deoxy Glucose (FDG)-PET is a functional imaging modality that characterizes different tissues in the body according to glucose metabolism. In contrast

to anatomical imaging such as CT and MRI, PET imaging is based on metabolism and tissue perfusion. PET is done using a radioactively labeled glucose analogue (FDG) that can be localized accurately due to its emission of positrons. Because FDG is taken up by the tissue in the same fashion as normal glucose, this radioactive tracer becomes concentrated in cell with high levels of glucose usage. Tumor cells have increased levels of glucose metabolism and rapid cell proliferation. The increased glucose uptake observed in tumor cells has been attributed to either an increase in transcription and translation of glucose transport proteins in tumor cells or to hexokinase activity. Because of this characteristic, FDG uptake is elevated in malignant cells compared to normal tissue. As a result neoplasia are reliably distinguishable from surrounding tissue on PET imaging. PET scans are increasingly read alongside CT scans or MRI scans, the combination (“co-registration”) giving both anatomic and metabolic information. Because PET imaging is most useful in combination with anatomical imaging, such as CT, modern PET scanners are now available with integrated high –end multidetector-row CT scanners. Because the two scans can be performed in immediate sequence during the same session, with the patient not changing position between the two types of scans, the two sets of images are more- precisely registered, so that area of abnormality on the PET imaging can be more perfectly correlated with anatomy on the CT images. This is very useful in showing detailed views of moving organs or structures with higher amount of anatomical variations.⁷

There are studies which show hybrid PET-CT scan is better than PET scans only as the former can be utilized to localize an FDG –avid site anatomically, by the superposition of CT images on PET-scan images. One such study showed that when the PET scans was done alone; it had a sensitivity of 24 – 40 % as compared to 59 % sensitivity when PET scan was co-registered with CT scans.⁸⁻¹⁰

In the past many studies were performed evaluating the efficacy of PET/CT in detecting occult primaries in patients with CUPS. A Study by Fogarty et al found that FDG-PET correctly detected a primary tumor that had gone undetected by CT/MRI in 62 of 276 cases (22.5%). A review by Rusthoven et al suggests that FDG PET/CT provides additional information beyond conventional anatomic imaging in 24.5% patients. Another study by Nanni et al (2005) detected primary tumor site in 12 out of 21 (57%) patients by 18F-FDG-PET-CT scan.

Very few similar studies have been conducted in India, moreover in the Indian scenario, the high prevalence of chronic granulomatous and inflammatory conditions, warrants a study in which efficacy of PET/CT scan could be ascertained in detecting primary in cases of CUPS. The present study is planned to evaluate the efficacy of PET-CT scans in detecting occult primaries in patients of CUPS.

Material and Methods

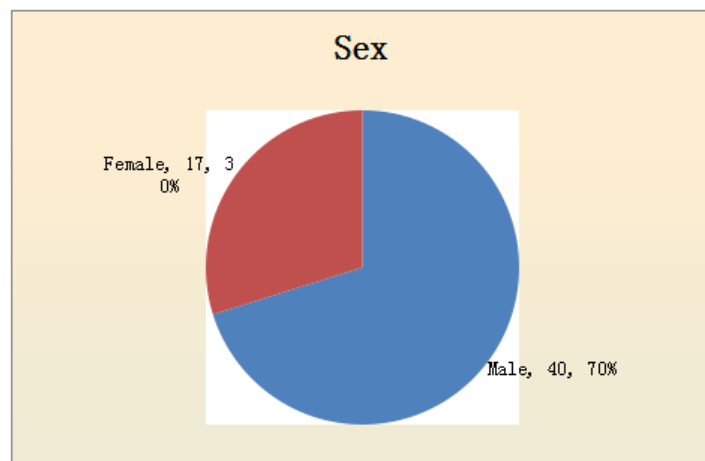
The aim and objective of this study was to diagnose potential primary by F-18 FDG PET/CT in Carcinoma of Unknown Primary site (CUPS) and to assess the sensitivity and specificity of FDG PET/CT for detection of primary. This study was a prospective, non-randomized, single group assignment, safety/efficacy study conducted in the Department of Nuclear Medicine, Army Hospital (Research & Referral), Delhi Cantt. duly approved by institutional Ethical committee. This study was completed over a period of 24 months from 01 June 2012 to 31 May 2014, included patients with diagnosis of CUPS, proven histopathologically with probability sampling method.

Detailed history of the CUPS patients referred from the Oncology dept for whole body PET/CT scan was recorded. Findings of relevant investigations carried out, recorded (CT / MRI). PET/CT scan performed using Siemens Biograph 2 scanner using FDG a radiopharmaceutical. Analysis of the findings on PET/CT scans. Any discordant findings investigated by subjecting the

positive lesion to biopsy and histopathology examination. The outcome of the results tabulated & analyzed to assess the potential diagnostic accuracy of primary in CUPS.

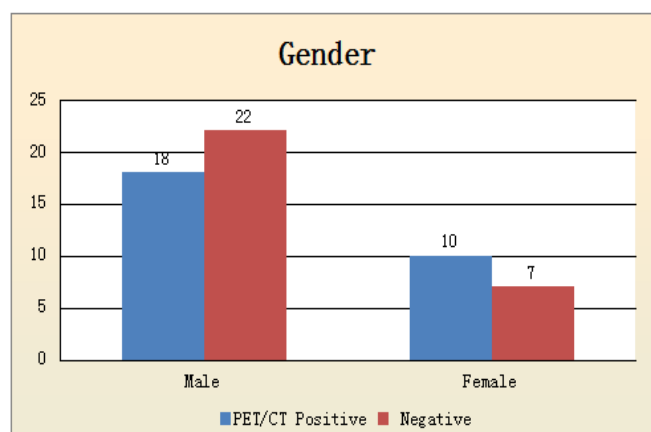
Results

Total numbers of patients accrued in to the study were fifty seven from the entitled patients. Out of fifty seven patients, forty (70%) were male and seventeen (30%) were female patients.



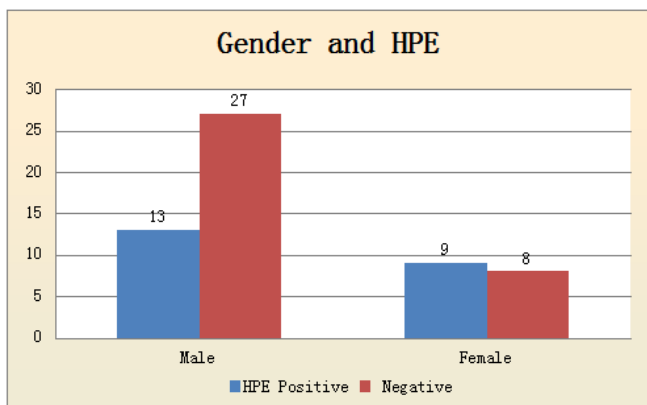
In forty male patients eighteen patients were PET/CT positive and twenty two were PET/CT negative. Similarly in seventeen female patients ten patients were PET/CT positive and seven were PET/CT negative.

| | | PET/CT | | Total |
|-------|--------|----------|----------|-------|
| | | Positive | Negative | |
| Sex | Male | 18 | 22 | 40 |
| | Female | 10 | 7 | 17 |
| Total | | 28 | 29 | 57 |

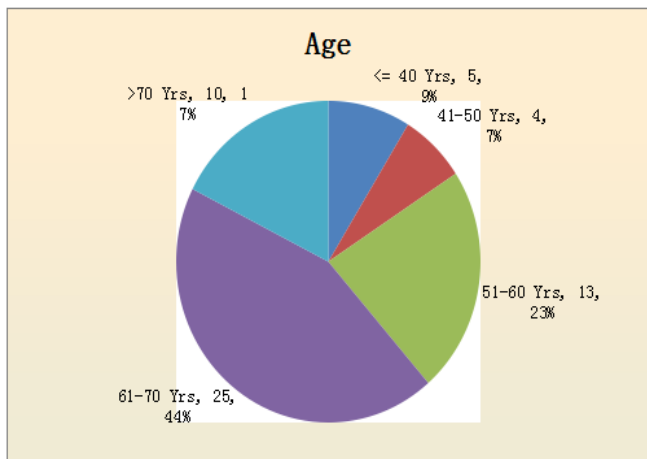


Out of forty male patients thirteen were HPE positive for primary and twenty seven were HPE negative. Similarly in seventeen female patients nine patients were HPE positive and eight were HPE negative.

| | | HPE | | Total |
|-------|--------|----------|----------|-------|
| | | Positive | Negative | |
| Sex | Male | 13 | 27 | 40 |
| | Female | 9 | 8 | 17 |
| Total | | 22 | 35 | 57 |

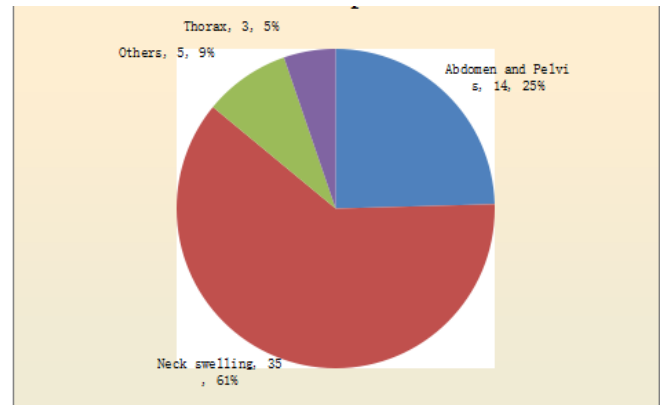


Age profile of patients varied from 23 to 83 yrs with mean age at 62 yrs. Maximum number of patients [thirty eight out of fifty seven (67 %)] belonged to sixth and seventh decades of life.

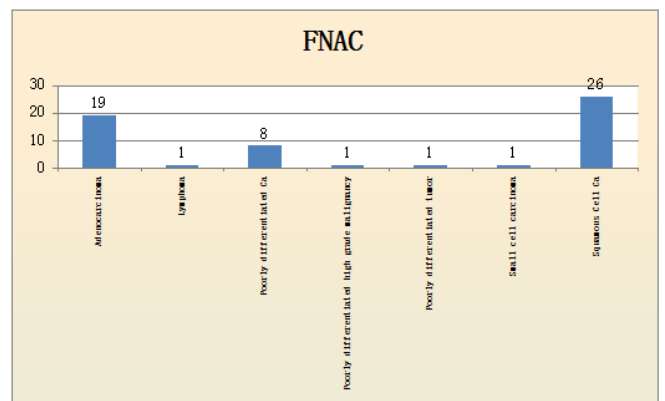


Out of fifty seven patients the clinical presentation and localization of metastases varied as, thirty five (61%) patients had neck swelling, fourteen patients (35%) had involved abdomen and pelvic region, three patients (5%) had involved thorax region and in five patients (9%) other sites were involved.

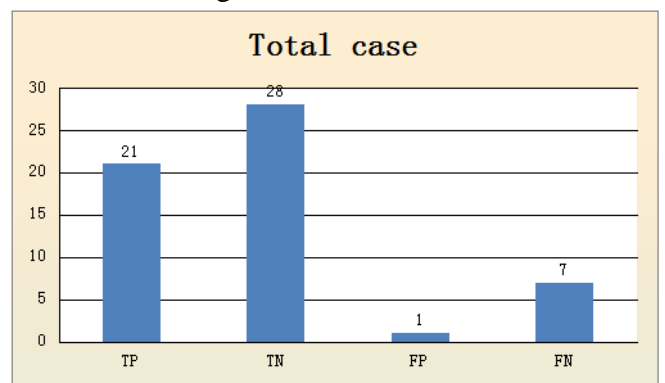
Metastatic sites with clinical presentation



Twenty six (46%) of these patients had squamous cell carcinoma, nineteen (33%) had adenocarcinoma, eight (14%) had poorly differentiated carcinoma and remaining four had other metastases.



FDG PET/CT was negative in twenty nine (51%) patients and was positive in twenty eight patients (49%). In twenty eight patients, twenty one were true positive, seven were false positive. In twenty nine patients, twenty eight were true negative and one was false negative.



In twenty one true positive cases, nine were in head and neck region, five in lung, 3 in colon and rectum, two in gall bladder, one each in thyroid

and stomach. Out of twenty one patient seven patient were squamous cell carcinoma, seven were adenocarcinoma, four were poorly differentiated carcinoma , one each was small cell carcinoma, poorly differentiated high grade malignancy and lymphoma on HPE.

In twenty eight true negative case, sixteen were in head and neck region, eight were in abdomen and pelvic region , two were in thorax and two were involving other sites in their initial presentation.

Out of seven false positive cases, six were in head and neck region and one in colon.

One case was false negative. In this patient pan endoscopy revealed slight thickening in Rt AE fold.. PET/CT did not reveal any FDG avid lesion. HPE shows squamous cell carcinoma.

On analysis the data various quantitative parameters of the study were arrived. Sensitivity and specificity of FDG -PET-CT in our study was 75 and 96 % respectively while positive and negative predictive values were 95 and 80 % respectively.

Discussion

This prospective study was conducted at Army hospital (Research and Referral), on entitled patients only, and hence incidence of our series is not a true indication of the general population. Amongst a total of fifty seven patients, nine patients were detected to have a primary tumor in head and neck region ,five in lung, three in colon and rectum , two in gall bladder, one each in thyroid and stomach.

On analyzing the Fine needle aspiration cytology (FNAC) of these cases which were accrued in as CUPS, it was found that 26 (44%) were metastases from squamous cell carcinoma, 19 (33%) were from adenocarcinoma, 8 (14%) were from Poorly differentiated carcinoma and 4 patients had other metastatic histopathological type. Literature confirms the predominance of adenocarcinoma and squamous cell carcinoma in CUPS cases.¹¹

In our study, 37 cases (65 %) were in the age group of 51-70, which is comparable to the age of

presentation of CUPS, as described in various studies, as about 66 % in the age group of 61-70.¹² The overall detection of true positive cases by PET/CT was 21 which accounts to 37 % of cases, in whom the primary could not be detected by the diagnostic protocol followed hitherto. The rate of primary tumour detection by FDG-PET/CT found in our study is in agreement with most studies in literature, with site detection rates of between 21% and 47%.^{13,14,15,16,17,18}

The low rate of detection of primary in CUPS, by imaging modalities employed so far, attributed to various factor; spontaneous regression, immune modulated destruction of the primary cancer , faster proliferation rate of lymphnodal metastases .and removal of primary site by sloughing of a necrotic tumour from the gastrointestinal tract are discussed . Bronchogenic carcinoma mistaken for a lymph node metastasis may also be an explanation for an unsuccessful primary tumour search.^{19,20,21,22}

In our study, there were 29 (51%) cases in which PET/CT did not suggest any evidence of primary; this high number has been attributed , apart from the above mentioned factors, to the fact that the in- plane resolution for a typical FDG- PET scan is approximately 9-10 mm in actual clinical use. Significant base line activity can occur within head and neck as a result of normal uptake in salivary glands, mucosa, tonsils and salivary secretion. Significant base line activity can also occur in liver, small and large intestine as physiological uptake. Some of the primary tumour may be too small to resolve above this normal FDG background activity. Imaging with a different PET tracer as C-11 methionine, may improve detection of occult primary tumours.²³

In our study 7 out of 57 (12%) cases show false positive results, six cases were in head and neck region and one in colon. Various other studies mentioned a wide range of false positive result (7 to 31 %).^{14,15,16,17,18,19} These false positive result could be due to a few factors like a high physiological uptake in head and neck region and GIT. The small size of the tumour has also been attributed to missing the lesion on biopsy, wherein

a sampling error, could lead to apparent false positive FDG - PET results. Strauss discusses other reasons for false positive findings include acute inflammatory conditions.²⁴

There was a false negative case in which the thickening in the Rt AE fold was not picked by PET-CT. HPE revealed well differentiated squamous cell carcinoma. This one case out of 57 cases forms about 2 % and review of other studies revealed a false negative rate between 5 to 8 %. Sensitivity of any diagnostic tool depicts the ability to bring out true positive and thereby correctly diagnose the presence of disease factor being studied; lesser the false negative, higher the sensitivity. Sensitivity of the PET- CT in our study was 75%, while review of other studies revealed sensitivity ranging from 67 to 100%. Specificity of a diagnostic tool represents the ability to bring out the true negative, thus correctly measure the absence of the disease factor being studied; hence lesser the false positive higher is the specificity. Specificity of PET- CT in our study was 96% and review of studies by other authors showed specificity of PET-CT ranging from 56 to 79 %. The positive predictive value (PPV) and negative predictive value (NPV) of our study was 95% and 80 % respectively, while it ranged between 33 to 88 % and 50 to 100 % respectively for studies conducted by other authors.^{14,15,16,17,18,19}. This wide range in various studies have been attributed to the fact that higher sensitivity, specificity, PPV, and NPV were achieved in studies involving PET-CT co-registration, as compared to PET alone (which showed higher false positive results).²⁴

Conclusion and Recommendations

In our study, FDG- PET-CT has proved to be a valuable diagnostic tool in patients with CUPS because of its high sensitivity and specificity in detecting the primary tumors, there by assisting in both guided biopsies and selecting appropriate treatment protocols in these patients.

FDG - PET- CT is hence recommended to be included as a part of diagnostic workup towards detecting primary in a case of CUPS. In future

PET- CT is likely to become a screening tool for CUPS ahead of other diagnostic modalities.

Acknowledgements* Department of oncology

Bibliography

1. Varadhachary, G. R. (2007). Carcinoma of Unknown Primary Origin. *Gastrointestinal Cancer Research : GCR*, 1(6), 229–235.
2. Kwee TC, Basu S, Cheng G, Alavi A. FDG PET/CT in carcinoma of unknown primary. *European Journal of Nuclear Medicine and Molecular Imaging*. 2010;37(3):635-644. doi:10.1007/s00259-009-1295-6.
3. George Pentheroudakis, Evangelos Briasoulis, Nicholas Pavlidis. Cancer of Unknown Primary Site: Missing Primary or Missing Biology?. *The Oncologist* 2007; 12:418425; doi:10.1634/theoncologist.12-4-418
4. The Bethesda handbook of clinical oncology third edition, page 388
5. Chevalier TL, Cvitkovic E, Caille P, Harvey J, Contesso G, Spielmann M, Rouesse J. Early Metastatic Cancer of Unknown Primary Origin at Presentation A Clinical Study of 302 Consecutive Autopsied Patients. *Arch Intern Med*. 1988;148(9):2035-2039
6. Regelink, G., Brouwer, J., de Bree, R. et al. *Eur J Nucl Med* (2002) 29: 1024
7. Wahl RL, Buchanan JW, eds. Principles and practice of positron emission tomography. Philadelphia, Pa: Lippincott Williams & Wilkins, 2002
8. Alberini JL, Belhocine T, Hustinx R, et al. Whole body PET using FDG in patients with metastasis of unknown primary tumours (CUPS). *Nucl Med Commun* 2003;24:10 81-1086.
9. Bohuslavizki KH, Klutmann S, Kroger S, et al. FDG- PET detection of unknown primary tumours. *J Nucl Med* 2000;41: 816-822.

10. Kole AC, Neuweg OE, Pruijm J, et al. Detection of unknown occult primary tumours using PET. *Cancer* 1998;82: 1160-1166.
11. Pelosi E, Pennone M, Deandreis D, Douroukas A, Mancini M, Bisi G. Role of whole body positron emission tomography/ computed tomography scan with 18F-fluorodeoxyglucose in patients with biopsy proven tumor metastases from unknown primary site. *Q J Nucl Med Mol Imaging* 2006;50:15–22
12. Hawkins RA, Hoh CK, Dahlbom M, et al. PET cancer evaluation with 2-(18 F)-2-deoxy-D-glucose, *J Nuc Med* 1994; 32:1555-1558.
13. Wartski M, Stanc EL, Gontier E, et al. In search of an unknown tumour presenting with cervical metastases: Performance of hybrid FDG-PET-CT. *Nucl Med Commun* 2007;28:365-371
14. Bohuslavizki KH, Klutmann S, Kroger S, et al. FDG- PET detection of unknown primary tumours. *J Nucl Med* 2000;41: 816-822.
15. Nanni C, Rubello D, Castellucci P, et al. Role of FDG-PET-CT imaging for the detection of an unknown primary tumours preliminary results in 21 patients. *Eur J Nucl Med Mol Imaging* 2005;32 :589-592.
16. Hawkins RA, Hoh CK, Dahlbom M, et al. PET cancer evaluation with 2-(18 F)-2-deoxy-D-glucose, *J Nuc Med* 1994; 32:1555-1558.
17. Paul SAM, Stoeckli SJ, von Schulthess GK, et al. FDG- PET and PET/CT for the detection of the primary tumor in patients with cervical non- squamous cell carcinoma metastasis of an unknown primary.
18. Lassen U, Daugaard G, Eigtved A, et al. 18-F FDG Whole body PET in patients with unknown primary tumours (UPT). *Eur J Cancer* 1999;35(7):1076-1082.
19. Abruzzese JL, Lenzi R, Raber MN, et al. The biology of unknown primary tumours. *Semin Oncol* 1993;20: 238-243.
20. Frost P, Levin B. Clinical implications of metastatic process. *Lancet* 1992;339: 1458-1461.
21. Frost P. Unknown primary tumors: an example of accelerated (type 2) tumor progression. *Basic Life Sci* 1991;57: 233-237.
22. Knobber D, Lobeck H, Steinkamp HJ, Does malignant lateral cyst still exists? *HNO* 1995; 43:104-107.
23. Schoder H, Heung HWD, Gonen M, et al. Head and neck cancer: clinical usefulness and accuracy of PET/CT image fusion. *Radiology* 2004; 231:65-72.
24. Strauss LG. Fluorine -18 deoxyglucose and false positive results: a major problem in the diagnostics of oncological patients. *Eur J Nucl Med* 1996;23: 1409-15.