



## Malignant Peripheral Nerve Sheath Tumor: A Rare Case and Review of Literature

Authors

**Dr Shashirekha C A<sup>1</sup>, Dr Arvind Ramachandran<sup>2</sup>, Dr Ravikiran H R<sup>3</sup>**

<sup>1</sup>Associate Professor, Department of General Surgery, SDUMC, Kolar

<sup>2</sup>Post Graduate, Department of General Surgery, SDUMC, Kolar

<sup>3</sup>Assistant Professor, Department of General Surgery, SDUMC, Kolar

### Introduction

Malignant peripheral nerve sheath tumors are a rare type of cancer that arise from the soft tissue that surrounds nerves. They are a type of sarcoma. Most malignant peripheral nerve sheath tumors arise from the nerve plexuses that distribute nerves into the limbs the brachial and lumbar plexuses or from nerves as they arise from the trunk. MPNSTs comprise approximately 5-10% of all soft tissue sarcomas. They can occur either spontaneously or in association with neurofibromatosis-1.

The etiology is unknown but there is a higher incidence in patients with a history of radiation exposure. Up to 50% of MPNSTs occur in patients with NF1, demonstrating the tendency for this tumor to arise from a preexisting neurofibroma. Cross sectional studies have previously demonstrated a 1-2% prevalence of MPNST among NF1 patients although a recent study showed these patients have a 10% lifetime risk of ultimately developing an MPNST.

The development of plexiform neurofibromas has been linked to the loss of NF1 gene expression in

a mouse model, while the development of MPNST has been related to other genetic insults, such as those involving p53 and p16. While NF1 gene activity does not independently cause MPNSTs, it may in fact predispose these patients to such an event.

MPNSTs generally occur in adulthood, typically between the ages of 20 and 50 years of age. Approximately 10-20% of cases have been reported to occur in the first 2 decade of life, with occasional cases involving infants as young as 11 months of age.

Malignant peripheral nerve sheath tumours (MPNSTs) are aggressive, locally invasive soft tissue sarcomas, typically presenting as a rapidly growing and painful lump. These tumours account for up to 10% of all soft tissue sarcomas and are associated with poor prognosis unless wide excision of the tumour is undertaken before local invasion or distant metastasis can occur. The incidence of sporadic MPNSTs is low, with a lifetime risk of 0.001% but in association with the familial condition neurofibromatosis type 1 (NF1), where these tumours often arise from malignant trans-

formation of a plexiform neurofibroma, the incidence is much higher. Evans et al. estimate the lifetime risk of developing MPNSTs in the population of patients with NF1 to be as high as 13%. A number of studies have compared survival in sporadic and NF1-associated tumours but no consensus has been reached on whether NF1 is an independent poor prognostic factor or not.

### CASE REPORT

A 25yr old female patient presented to department of surgery, Sri Devraj Urs Medical college, kolar, Karnataka, with swelling in the inner aspect of left thigh since 6 month, which was gradually progressive in size and associated with dull aching pain, no h/o radiation of pain, no h/o restriction of movements of lower limb, no h/o radiation exposure, no h/o previous swelling

On examinassions:

General physical examination was normal

Local examination: A globular shaped swelling located in the medial aspect of left thigh, non tender, well defined irregular margin, smooth surface, soft to firm in consistency, measuring about 8x8 cms, mobility restricted on contraction of muscle and the skin over the swelling was normal

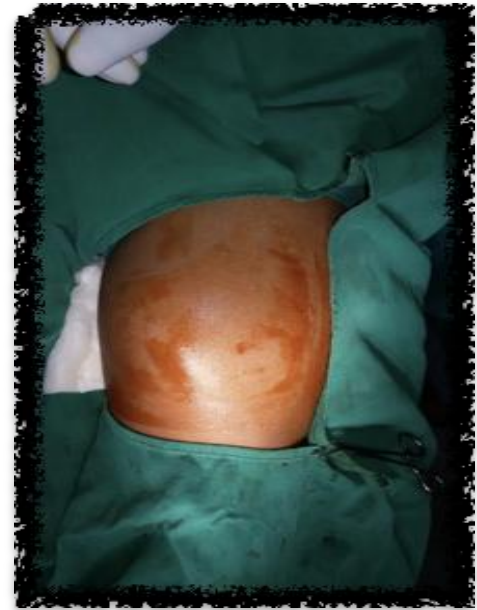### INVESTIGATIONS

Routine - normal

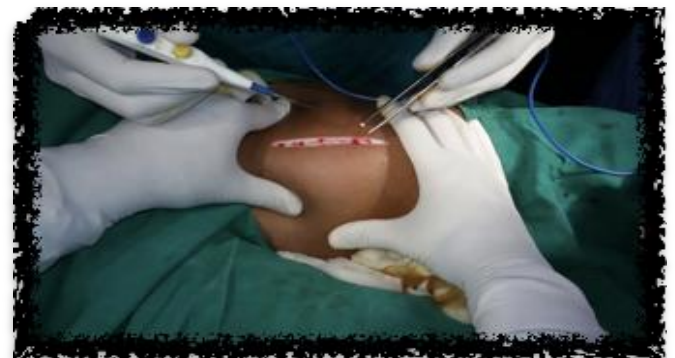Ultrasonography:

- A heterogenous ill defined lesion is seen in antero medial aspect of left thigh measuring 9.7X8x5.6 cm
- The lesion appears to lie deep to subcutaneous plane within the superficial muscle layer
- The lesion shows cystic and solid components within, with increased vascularity in echogenic components. Few septations noted within the cystic portion.
- The cleavage between posterior border of the lesion and rest of the muscle plane is not clearly defined--- ?infiltration

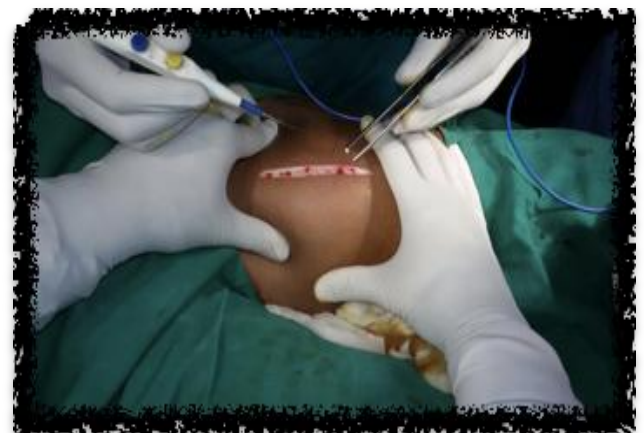### Impression



**Fig.1** Preoperative Image Show The Well Circumscribed Tumor



**Fig.2** Linear incision being taken over the tumor

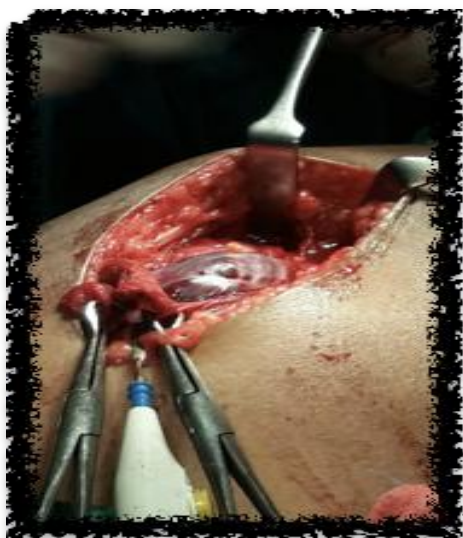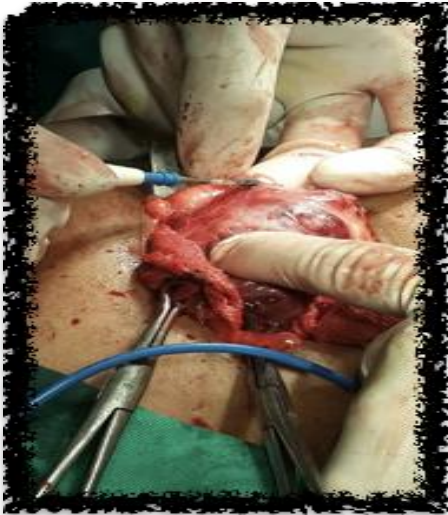


**Fig.3** Image showing the dissection of tumor

Focal heterogenous soft tissue lesion on the antero medial aspect of left thigh - suggestive of the soft tissue neoplasm (? sarcoma)

FNAC

Benign spindle cell lesion probably SCHWANOMA



**Fig.4 & 5** Showing the surface of tumor arising from the nerve sheath

### TREATMENT

Surgical exploration was carried out through the skin crease incision over the swelling in the medial aspect of left thigh. After dissection through skin, subcutaneous tissue

### DISCUSSION

MPNST is a very rare tumor, with an incidence of 1 per 1,00,000 population and which constitutes between 3 to 10% of all soft tissue sarcomas. Hence, this entity is often managed as a sub-category of soft tissue sarcomas. In contrast, in our series, MPNST constituted 12% (24/200) of all soft tissue sarcomas, with MPNST representing the second most common variety of soft tissue sarcoma seen. The most significant contributions in understanding the clinical and pathological features of MPNST were studied by Mayo clinic investigators. A combination of gross and microscopic findings along with immunohistochemical studies is commonly used to diagnose a case of MPNST. In most instances, the tumors display fascicles of spindle cells woven into herringbone pattern with varying degrees of mitosis and necrosis. However, it is not always possible to demonstrate the origin from a nerve, especially when it arises from a small peripheral branch. This point was exemplified in a series by Nambisan *et al.*, in which nerves could not be identified in 61% of cases of MPNST and in the series Bilge *et al.*, in which nerve origin could be identified only in 45–56% cases. Still, there are several other distinct features, such as proliferation of tumor in the sub-endothelial zones of vessels with neoplastic cells herniation into vessel lumen and proliferation of small vessels in the walls of the large vessels, which are very characteristic features of MPNST. A sarcoma is defined as a MPNST when at least one of the following criteria is met:

1. It arises from a peripheral nerve
2. It arises from a preexisting benign nerve sheath tumor (neurofibroma)
3. It demonstrates Schwann cell differentiation on histologic examination

### CONCLUSION

A high index of suspicion is necessary for early diagnosis of MPNST a rare type of cancer that arise from the soft tissue that surrounds nerves. Treatment consists of wide excision followed by radiation.

**REFERENCES**

1. Hruban RH, Shiu MH, Senie RT, Woodruff JM: Malignant peripheral nerve sheath tumors of the buttock and lower extremity. A study of 43 cases. *Cancer* 1990, 66:1253-1265.
2. Angelov L, Guha A: Peripheral Nerve Tumors. In *Neuro-oncology Essentials* 1st edition. Edited by: Berstein M, Berger MS. New York Theme Publishers; 2000:434-444.
3. Wanebo JE, Malik JM, VandenBerg SR, Wanebo JH, Driesen N, Persing JA: Malignant peripheral nerve sheath tumors. A clinico-pathologic study of 28 cases. *Cancer* 1993, 71:1247-1253.
4. Dasgupta TK, Choudhuri PK: Tumors of soft tissue 2nd edition. Connecticut Appleton & Lange; 1998:127-395.
5. Ducatman SB, Bernd WS, David GP, Herbert MR, Duane MI: Malignant peripheral nerve sheath tumors. A clinicopathologic study of 120 cases. *Cancer* 1986, 57:2006-2021.