



Diffuse Ganglioneuromatosis of Colon Presenting as Acute Intestinal Obstruction: A Rare Case Report

Authors

Biparnak Haldar, Saswati Majumdar, Malay Sarkar, Urvee Sarkar

Dept of Pathology, R. G. Kar Medical College and Hospital, 1, Khudiram Bose Sarani, Kolkata – 700004

Corresponding Author

Biparnak Haldar

Address: C-25/A, C Road, Anandapuri, Barrackpore, Kolkata-700122.

Email: biparnakhaldar@yahoo.com, Mobile No: +91 9831492675

Abstract

Ganglioneuromas are slow growing, well differentiated neuroectodermal neoplasms, typically derived from the sympathetic ganglia and adrenal glands and more common in children. Ganglioneuromas most frequently occur in the posterior mediastinum, retroperitoneum and adrenal glands but are rare in the colon. Colonic Ganglioneuromas fall into three subgroups – polypoid ganglioneuromas, ganglioneuromatous polyposis and diffuse ganglioneuromatosis. Diffuse ganglioneuromatosis is either transmural or mucosal. Adults tend to have mucosal lesions while children can have both mucosal or transmural lesions. Here we are reporting a case of diffuse ganglioneuromatosis of colon (transmural type), clinically presenting as acute intestinal obstruction in a 79 year old male patient, which is a rare entity.

Keywords- *Ganglioneuromas, Diffuse ganglioneuromatosis, colonic ganglioneuroma.*

Introduction

Ganglioneuromas are slow growing well differentiated neuroectodermal neoplasm, typically derived from the sympathetic ganglia and adrenal glands and more common in children.¹ Ganglioneuromas can be found in different anatomic sites but are rare in the colon. Colonic ganglioneuromas fall into three subgroups – polypoid ganglioneuromas, ganglioneuromatous polyposis and diffuse ganglioneuromatosis.⁴ Of the subgroups, colonic diffuse ganglioneuromatosis is large, ranging from 1 to 17cm and it can distort the surrounding tissue architecture as well as infiltrate the adjacent bowel wall. However only individual cases of colonic diffuse

ganglioneuromatosis in adults have been reported.^{5,6}

Case Report

A 79 year old male patient presented in 2017 at R.G. Kar Medical College and Hospital with features of Acute Intestinal Obstruction. Emergency Exploratory Laparotomy followed by double barrel ileocolostomy was done under general anaesthesia with endotracheal intubation on the very same day.

Intraoperative Findings

Diffuse Circumferential growth 5-10 cm from ileocaecal junction was noted. Segment of ileum

about 15 cm from ileocaecal junction along with caecum, appendix and ascending colon was resected following which double barrel ileocolostomy was done. Specimen was sent to department of Pathology in 10% formalin for histopathological examination.

Gross Morphology

Specimen of gut measuring 35 cm in length comprising of terminal ileum, appendix, caecum and part of ascending colon. On cut section no definite growth identified. One circumferential area with loss of rugosity was noted in the ascending colon measuring 5cm in length with thickening of the adjacent bowel wall. Appendix measured 7cm in length .

Microscopic Examination

Sections showed histopathological features of large gut with focal erosion of the mucosa and a highly vascular tumour composed of neural elements, myxoid stroma, and mature ganglion cells. The tumour had involved the muscularis propria and serosa mostly. The histopathological features were clearly suggestive of a diffuse mature ganglioneuroma (transmural type).

Immunohistochemistry Result

The colonic lesion was subjected to S100 and synaptophysin immunohistochemistry for confirmation.

S100-immunoreactive, score 4+ in nerve fibres and ganglion cells

Synaptophysin- immunoreactive, score 4+ in nerve fibres and ganglion cells

A score of 4+ indicates that it is immunoreactive in 76 to 100% cells. This further confirmed the diagnosis of diffuse ganglioneuromatosis.

The patient was doing well after surgical resection and was discharged. Unfortunately the patient was lost to follow up and hence further investigation could not be carried out to determine whether the patient had any associated systemic disease.

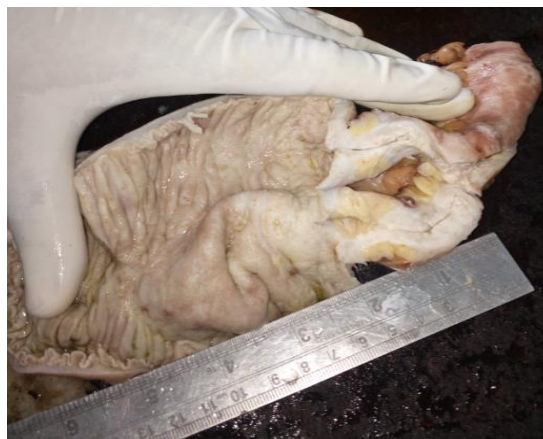

Fig.1. Gross Picture shows part of ascending colon with loss of rugosity and thickened wall

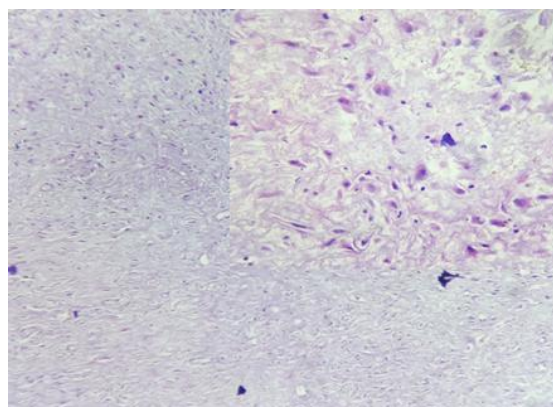


Fig.2. HPE showing colonic ganglioneuroma, low power (10X). Ganglion cells and stromal cells are present in the muscularis propria, high power (40X) (inset)

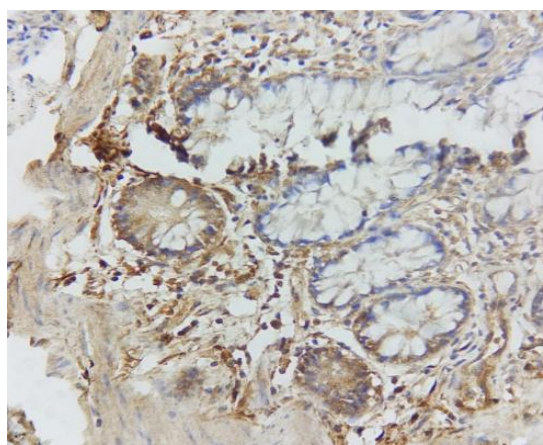


Fig. 3. IHC marker S100 highlighting neural cells and ganglion cells.

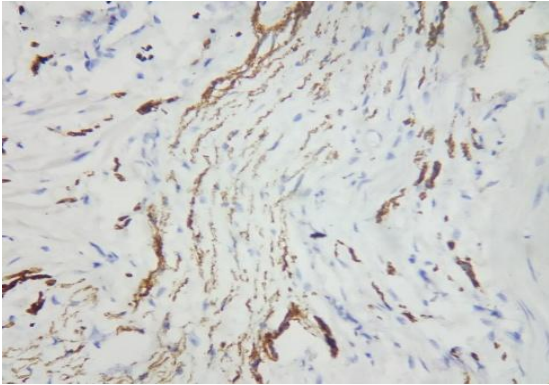


Fig.4. IHC marker Synaptophysin highlighting neural cells and ganglion cells.

Discussion

Intestinal ganglioneuroma is a rare, benign neoplastic condition characterised by a spectrum of pathological findings.³ Among the subtypes of colonic ganglioneuroma, colonic diffuse ganglioneuromatosis is an exceptional finding in adults.¹ Intestinal ganglioneuromas often have no symptoms and are usually found incidentally on routine colonoscopic screening.² Acute intestinal obstruction resulting from intestinal ganglioneuroma in adult is a rare finding which we have presented here.

Colonic ganglioneuromas are benign, hamartomatous neoplasms consisting of ganglion cells, nerve fibres and supporting cells of the enteric nervous system.⁷ These tumours rarely present in the gastrointestinal tract and most frequently occur in head, neck, posterior mediastinum, retroperitoneum or adrenal glands. They are categorised into three different morphological subtypes namely polypoid ganglioneuroma, ganglioneuromatous polyposis and diffuse ganglioneuromatosis.⁸ Polypoid ganglioneuromas are typically small (≤ 2 cm) juvenile polyps that are either adenomatous or hyperplastic. Morphologically they can be sessile or pedunculated and are often solitary or found in small groups. Ganglioneuromatous polyposis usually has many polyps (often 20 or more) that can be sessile or pedunculated and present in the mucosa and/or submucosa, ranging in size from 1mm to 2.2cm. These polyps can be histologically indistinguishable from polypoid ganglioneuroma

or may be filiform projections that contain ganglion cells, absent of other neural tissues. Diffuse ganglioneuromatosis is nodular and diffuse tissue that is either transmural or mucosal and involves the myenteric plexus. These lesions can be much larger ranging up to 17cm. Adults tend to have mucosal lesions while children can have both mucosal or transmural lesions.⁹ But in our case an adult presented with a transmural lesion.

Pathologic examination including immunohistochemistry staining allows a definitive diagnosis. The histologic diagnosis of ganglioneuromas is mainly based on the identification of ganglion cells mixed with proliferation of Schwann cells. Haematoxylin and eosin staining is usually sufficient to make the diagnosis. Stains for S100 protein, neuron specific enolase, Synaptophysin, Vasoactive intestinal peptide and neurofilament are helpful in confirming the neural origin of the lesion.^{4,5}

Colonic ganglioneuromas can be an isolated finding, but they more commonly arise as a component of MEN IIB syndrome, Von-Recklinghausen's disease, Cowden's disease or Ruvalcaba-Myhre-Smith syndrome.¹⁰ Because of the cancer risk associated with these syndromes, patients should be carefully screened for tumours of the thyroid, breast, colon and uterus. Urine Vanillylmandelic acid, Serum calcitonin and serum calcium tests may be helpful in excluding endocrinopathies found in MEN IIB. Genetic testing is recommended to detect an underlying inherited disorder. Our patient was lost during follow up and hence further testing could not be done to rule out systemic disease.

Due to poor response to medical management the standard treatment for colonic ganglioneuromas is surgical resection of the diseased bowel as well as a work up for any associated syndromes. However the treatment methods can differ based on the patient's clinical history as well as ganglioneuroma size and location. However, complications such as bleeding or obstruction should be considered. Endoscopic resection can be

a curative method for polypoid ganglioneuroma due to having benign nature but surgery may be necessary for ganglioneuromatous polyposis, diffuse ganglioneuromatosis or large polypoid lesion.

Conclusion

Adult transmural diffuse ganglioneuromatosis of colon is a rare entity and only few such cases have been reported. Ganglioneuroma is a rare cause of intestinal obstruction in adults and clinicians should keep this in mind as a cause when the initial presentation is with acute intestinal obstruction. Confirmatory diagnosis can only be revealed through histologic examination supported by Immunohistochemistry. Further tests for systemic and familial diseases should be considered in patients of ganglioneuroma.

References

1. Tae-Jun Kim, Hyun Lim, Ho Suk Kang, Sung Hoon Moon, Jong Hyeok Kim, Choong Kee Park, Mi Jung Kwon, and Bong Hwa Lee. Diffuse Ganglioneuromatosis of the Colon Presenting as a Large Subepithelial Tumor in Adults: Report of Two Cases. *Korean J Gastroenterol* 2015; 66:111-115.
2. George Abraham and Sateesh R. Prakash. Solitary Colonic Ganglioneuroma: Case Reports in *Gastrointestinal Medicine*, vol. 2015, Article ID 794985, 3 pages, 2015.
3. Sridhar R. Charagundla, Marc S. Levine, Drew A. Torigian, Mical S. Campbell, Emma E. Furth, John Rombeau. Diffuse Intestinal Ganglioneuromatosis Mimicking Crohn's Disease. *American Journal of Roentgenology* 2004.182:1166-1168.
4. Shekitka KM, Sobin LH. Ganglioneuromas of the gastrointestinal tract. Relation to Von Recklinghausen disease and other multiple tumor syndromes. *Am J Surg Pathol* 1994; 18:250-257.
5. Chambonnière ML, Porcheron J, Scoazec JY, Audigier JC, Mosnier JF. Intestinal ganglioneuromatosis diagnosed in adult patients. *Gastroenterol Clin Biol* 2003;27:219-224.
6. Mateş I, Iosif C, Dinu D, Constantinoiu S. Solitary ganglioneuromatosis of the descending colon, presenting as giant retroperitoneal tumour. *Chirurgia (Bucur)* 2013; 108:584-588.
7. Miettinen M, Fletcher CDM, Kindblom LG, Tsui WMS. Mesenchymal tumors of the colon and rectum. In: Bosman FT, Carneiro F, Hruban RH, Theise ND, eds. *WHO classification of tumours of the digestive system*. 4th ed. Lyon: IARC, 2010:140-141.
8. K. M. Shekitka and L. H. Sobin, "Ganglioneuromas of the gastrointestinal tract: relation to Von Recklinghausen disease and other multiple tumor syndromes," *The American Journal of Surgical Pathology*, vol. 18, no. 3, pp. 250–257, 1994.
9. M.-L. Chambonnière, J. Porcheron, J.-Y. Scoazec, J.-C. Audigier and J.F. Mosnier, "Intestinal ganglioneuromatosis diagnosed in adult patients," *Gastroenterologie Clinique et Biologique*, vol. 27, no. 2, pp. 219–224, 2003.
10. Carney JA, Go VL, Sizemore GW, Hayles AB. Alimentary-tract ganglioneuromatosis. A major component of the syndrome of multiple endocrine neoplasia, type 2b. *N Engl J Med* 1976;295:1287-1291.