



## Comparative Clinical Study of Oral Tranexamic Acid and Topical Tranexamic Acid with Microneedling in the Management of Melasma

Authors

**Thillaikkarasi. A<sup>1</sup>, Prasad P.V.S<sup>2</sup>, Kaviarasan.P.K<sup>3</sup>, Kannambal.K<sup>4</sup>**

<sup>\*1</sup>Post Graduate, Department of Dermatology Venereology and Leprosy, Rajah Muthiah Medical College & Hospital, Annamalai University, Chidambaram, India – 608002.

<sup>2</sup>Professor, Department of Dermatology Venereology and Leprosy, Rajah Muthiah Medical College & Hospital, Annamalai University, Chidambaram, India – 608002.

<sup>3</sup>Head of the Department, Department of Dermatology Venereology and Leprosy, Rajah Muthiah Medical College & Hospital, Annamalai University, Chidambaram, India – 608002.

<sup>4</sup>Reader, Department of Dermatology Venereology and Leprosy, Rajah Muthiah Medical College & Hospital, Annamalai University, Chidambaram, India – 608002.

### Abstract

**Background:** *Melasma is an acquired hyperpigmentary disorder characterised by light to dark-brown macules and patches, particularly affecting the sun-exposed areas. The management of melasma is challenging and requires long term treatment plan. Although various treatment options are available, no mode of treatment guarantees satisfactory results. Recent studies have shown that TXA can prevent UV pigmentation in melasma.*

**Aim:** *To compare the efficacy of oral tranexamic acid and topical tranexamic acid with microneedling in patients with melasma in a tertiary care hospital in south India.*

**Methods:** *It is a prospective, randomized, open-label study conducted among 60 melasma patients. Patients were divided into two groups, 30 patients were given oral tranexamic acid 250 mg tablet twice daily for three months (Group A) and remaining 30 were treated with topical tranexamic acid with microneedling procedure done at monthly interval for 3 times (Group B), and followed up for three consecutive months. Percentage reduction in baseline Melasma Area and Severity Index (MASI) was assessed at 4-week intervals, and response was recorded.*

**Results:** *The mean pre MASI score in group 'A' was  $13.4 \pm 6.92$  which is reduced to  $3.99 \pm 2.05$  compared to group 'B' where it was  $9.96 \pm 2.79$  and got reduced to  $5.21 \pm 1.63$  after 3 months of treatment. The average improvement in MASI score after 12 weeks of treatment for group 'A' was 70.29% which was comparatively higher than group 'B' in which improvement was only 48.02%.*

**Conclusions:** *On the basis of these results, therapeutic response was higher in the oral tranexamic acid group than topical tranexamic acid with microneedling group.*

**Keywords:** *Melasma, microneedling, tranexamic acid.*

### Introduction

Melasma is an acquired pigmentary disorder of the skin characterized by light to dark brown macules and patches symmetrically involving the

sun-exposed areas of the face, neck and occasionally the forearms.<sup>(1)</sup> This disease is commonly observed in women of reproductive

age with Fitzpatrick skin type IV-VI, rarely in postmenopausal females and males.<sup>(2)</sup>

The etiopathogenesis of melasma is complex. Genetic susceptibility, ultraviolet (UV) light exposure, pregnancy, sex hormones, contraceptive pills, thyroid disease, cosmetics, and phototoxic drugs were implicated in the pathogenesis of melasma. Management of melasma remains a therapeutic challenge, especially in dark skin individuals. Numerous treatment options including topical agents, chemical peels and lasers have been used in the treatment of melasma.<sup>(3)</sup>

In recent times, some researchers found that tranexamic acid (TXA), a traditional hemostatic drug, has hypopigmentary effect on melasma lesions and also prevents UV-induced pigmentation. The intracellular release of arachidonic acid (AA), a precursor of prostaglandins, and the level of alpha-melanocyte-stimulating hormone increase as a result of plasmin activity. These two substances can activate melanin synthesis. Therefore, the anti-plasmin activity of TXA is thought to be the main mechanism of hypopigmentary effect of this agent.<sup>(4)</sup>

### Materials and Methods

All melasma patients, who were willing to undergo the study and who signed the consent for clinical photograph and study, were selected on the basis of selection criteria. A total number of 60 patients were randomly selected based on selection criteria. Patients were randomised by systematic random sampling into two groups with every odd number patients allotted into group A and even number patients were allotted into group B. Patients in group A received oral tranexamic acid (TXA), group B patients were treated with topical TXA and micro needling.

### Inclusion criteria

- Patients with melasma in age group between 18 to 50 years
- All treated cases of melasma with relapse or treatment failure cases (treatment free period should be more than 4 weeks)

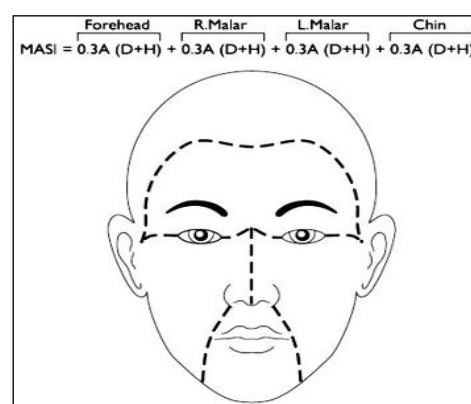
- Patients who are willing to give consent to undergo photography, laboratory investigations, willing to take oral TXA and undergo microneedling procedure.

### Exclusion criteria

- Age less than 18years and more than 50years, unwilling patients
- Patients with unrealistic expectations.
- Pregnancy and lactation.
- Patients with underlying bleeding disorders, cardiovascular diseases, autoimmune disorders, malignancy and long duration of steroid and hormonal therapy.
- Acne and atopic dermatitis patients. History of keloidal tendency and active infections.

Written and informed consent in their own language was obtained from all patients who were selected for the study. A detailed history was taken. Complete heamogram, bleeding and coagulation profile (PT, aPTT, INR), thyroid function test, serum cortisol level, liver and renal function test were carried out in both groups.

Melasma Area Severity Index score (MASI) was assessed for all the patients by two different observers. According to MASI score whole face was divided into four areas (A), (forehead (F) 30%, right malar region (RM) 30%, left malar region (LMR) 30% and chin (C) 10%) darkness (D) and homogeneity (H) graded from 0 to 4. The MASI score was calculated by following the equation:



$$MASI \text{ score} = 0.3 AF (DF + HF) + 0.3 AMR (DMR + HMR) + 0.3 AML (DML + HML) + 0.1 AC (DC + HC)$$

Group A patients (n=30) were treated with oral TXA tablet 250 mg twice daily after food and topical sunscreen with SPF 45 for 3 months duration and group B patients (n=30) were treated with topical TXA with microneedling (1.5 mm) along with topical sunscreen with SPF 45 for 3 months duration.

TXA drug for injection is available as ampoule with 500mg / 5ml. About 4units of TXA diluted with 96 units of normal saline in a 100 units insulin syringe to get a concentration of 4mg / ml of TXA.

After gentle cleansing, topical anaesthetic gel (Eutectic mixture of lignocaine 2.5 % and prilocaine 2.5%) was applied under occlusion over the treatment area for 45 minutes prior to microneedling. After adequate achievement of topical anaesthesia the lesional skin was stretched and microneedling procedure carried out in vertical, horizontal, and diagonal directions for five times. One ml of TXA solution (4 mg/ml) was applied over 2cm<sup>2</sup> of lesional area, and the procedure was repeated five times in the above said directions. Ice packs were used before and after the procedure over the melasma areas to minimize the erythema pain and bleeding. The patients were instructed to follow strict photo protective measures. The procedures were repeated three times at monthly intervals (0 (V<sub>1</sub>), 4 (V<sub>2</sub>), and 8 (V<sub>3</sub>) weeks). After the end of third month both groups were advised to continue the sunscreen and advised to come for regular follow up at monthly intervals for the period of three months. Clinical photographs were taken before initiation of therapy and serially during every visit (V) and documented

The MASI score of all patients in both groups were compared and analysed at each visits using ANOVA. Independent sample 't' test was used to assess MASI score between groups.

## Result

A total of 60 melasma patients were enrolled in this study. Out of 30 cases 28 patients in Group A and 20 patients out of 30 cases in Group B had

successfully completed entire study as well as follow up. Hence they were finally considered for analysis, the dropout cases were excluded. The most common age of the overall study patients were 31- 40 years observed in 22 cases (45.83%). More than 89% of the cases were between 30-50 years of age. The mean age of the study patients was 39.63±6.56yrs, females outnumbered males as females were 85.42% and males were 14.58%. Hence female: male ratio was 5.9: 1.

Majority of patients in the overall study groups had melasma duration between 1 to 2 years (45.83%). The mean duration was 14.52 ± 6.29 months. The most common pattern of involvement in the study group was centrofacial seen in 31cases (64.58%), followed by malar in 17 cases (35.42%). The distribution of clinical types of melasma almost equal in the both groups centrofacial 65% and malar 30-40 % of cases. Prolonged sun exposure was the most common pre disposing factor for the development of melasma. 50% of patients had history of prolonged sun exposure. Five patients had hypothyroidism, 12 patients had positive family history. Out of 41 females 7 cases had irregular menstrual cycle (17.7%). Depression and anxiety were significant psychological impact which was observed in 38 cases (79.3%) of overall study group.

**Table -1:** MASI Score analysis – within group

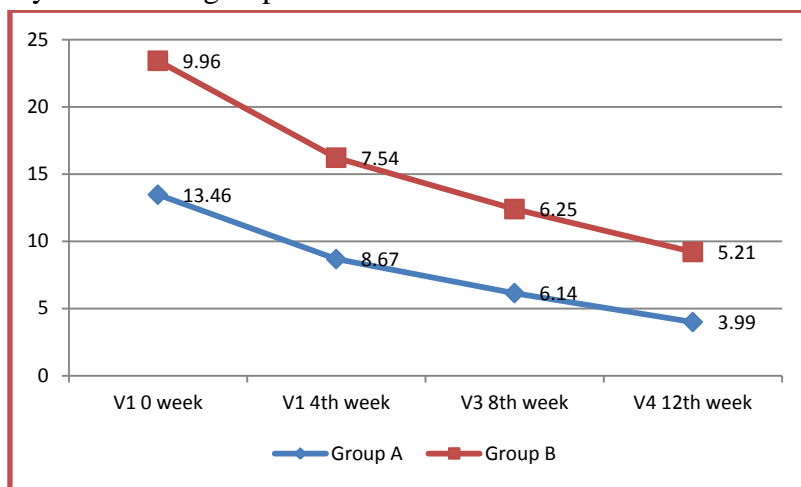
Assessment MASI Score- each visit	Group A	Group B
	Mean	Mean
V <sub>1</sub> 0 week	13.46 ± 6.92	9.96 ± 2.79
V <sub>1</sub> 4 <sup>th</sup> week	8.67 ± 4.49	7.54 ± 2.07
V <sub>3</sub> 8 <sup>th</sup> week	6.14 ± 3.12	6.25 ± 1.67
V <sub>4</sub> 12 <sup>th</sup> week	3.99 ± 2.05	5.21 ± 1.63
ANOVA	'F' value	'P' value
A	22.69	.001
B	19.18	.001

The detailed MASI score analysis was performed compared within group. The mean value of pre MASI score in group 'A' was 13.46 ± 6.92, which further reduced to 3.99 ± 2.05 at the 4<sup>th</sup> visit (12<sup>th</sup> week). Likewise the drop in MASI score was

gradual from visit 1(9.96 ± 2.79) to 4th visit (5.21 ± 1.63) in Group B. The MASI assessment of

both groups compared with baseline values showed significant reduction in every visit.

**Fig -1:** MASI Score analysis – within group



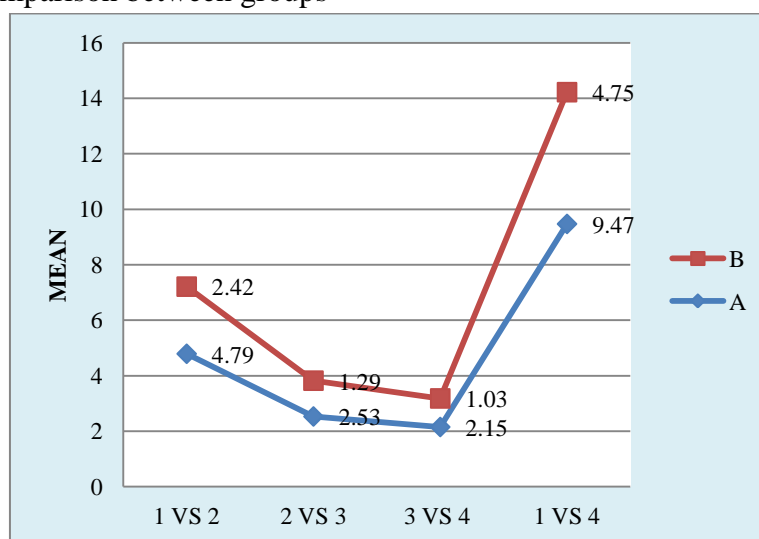
**Table -2:** MASI score comparison between groups

	Mean	Mean	't' value	'P' Value
	A	B		
1 <sup>st</sup> Vs 2 <sup>nd</sup> difference	4.79 ± 2.74	2.42 ± 1.08	3.65	.001
2 <sup>nd</sup> Vs 3 <sup>rd</sup> difference	2.53 ± 1.73	1.29 ± .59	3.07	.004
3 <sup>rd</sup> Vs 4 <sup>th</sup> difference	2.15 ± 1.47	1.03 ± .39	3.32	.002
1 <sup>st</sup> Vs. 4 <sup>th</sup> difference	9.47 ± 5.26	4.75 ± 1.36	3.92	.001

Oral TXA treatment group showed 3 fold reduction in MASI compared to baseline value, whereas topical TXA group showed 2 fold

reduction from the baseline. Oral TXA is very effective and significantly reduced the melasma pigmentation.

**Fig – 2:** MASI score comparison between groups



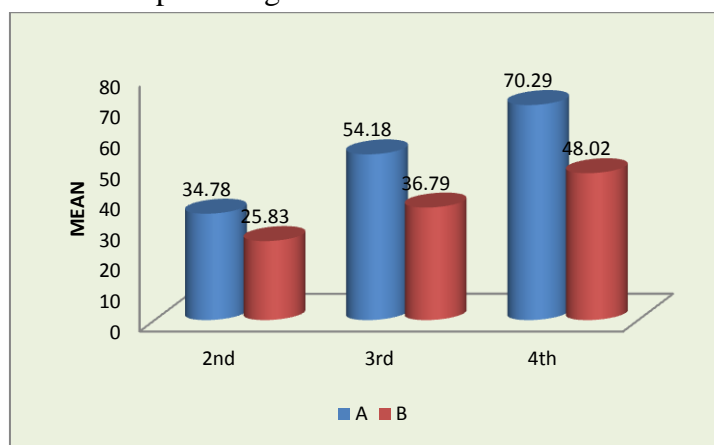
**Table -3:** MASI score improvement in percentages

Improvement score grading	MASI	Group A		Group B	
		Mean	S.D	Mean	S.D
MASI 2 <sup>nd</sup>		34.78	9.40	25.83	11.46
MASI 3 <sup>rd</sup>		54.18	10.15	36.79	7.78
MASI 4 <sup>th</sup>		70.29	7.93	48.02	6.67

The MASI score improvement in terms of percentages is presented in the table 17. The average 4<sup>th</sup> week improvement in group ‘A’ is 34.78 ± 9.40% whereas in group ‘B’ it is 25.83 ± 11.46%. The mean improvement at 8<sup>th</sup> week is

54.18% in group ‘A’ whereas it is 36.79% in group ‘B’. The 12<sup>th</sup> week improvement is again comparatively higher for group ‘A’ (70.29) than group B (48.02%).

**Fig – 3:** MASI score improvement in percentages



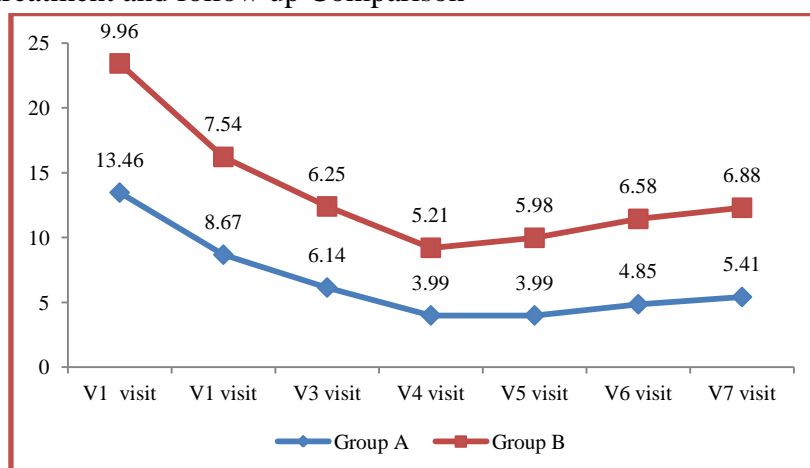
**Table - 4:** MASI Score Follow up Comparison

VISIT	A	B	‘Z’	‘P’
	MEAN	MEAN		
V <sub>5</sub> 16 <sup>th</sup> week	3.99 ± 1.99	5.98 ± 1.49	3.19	.001
V <sub>6</sub> 20 <sup>th</sup> week	4.85 ± 2.02	6.58 ± 2.11	2.78	.005
V <sub>7</sub> 24 <sup>th</sup> week	5.41 ± 2.64	6.88 ± 2.26	2.24	.025

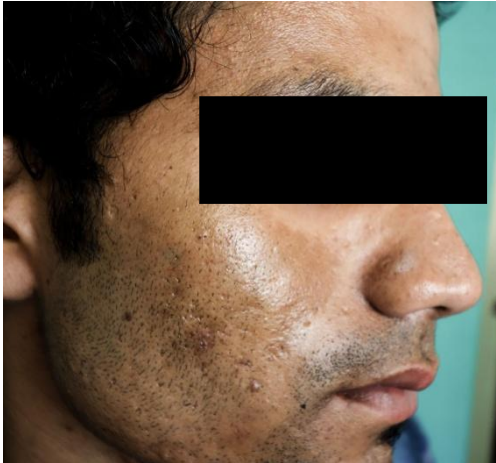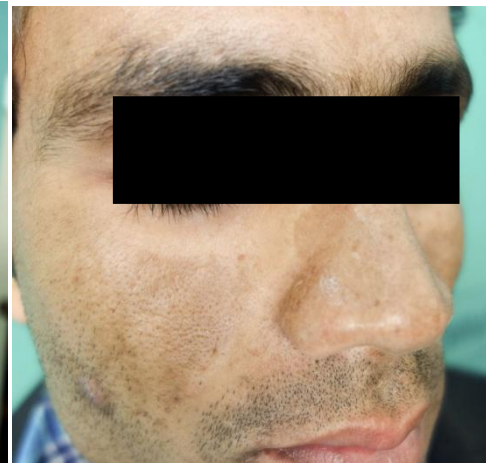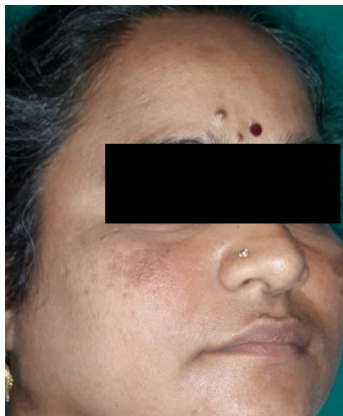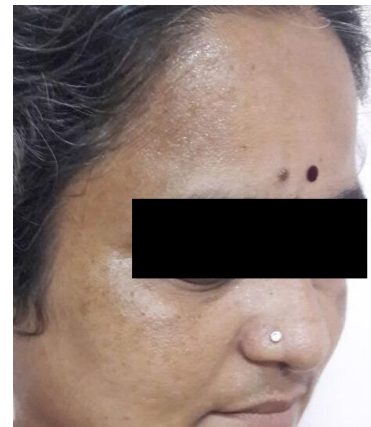The mean follow up MASI score was comparatively less in group A compared to group B at various weeks of follow up, further the difference being statistically significant. The

overall recurrence rate is 56.3%. Recurrence of the disease is observed in 53.6% of group ‘A’ and 60% of group ‘B’ patients.

**Fig – 4:** MASI score treatment and follow up Comparison





**Oral TXA****Before****After****Topical TXA with microneedling****Before****After****Discussion**

Melasma, an acquired pigmentary disorder of skin is characterized by hyperpigmented brown to greyish brown macules on the face. The most common locations are the cheeks, upper lips, chin, and forehead, but other sun-exposed areas may also occasionally be involved. Melasma is much more common in women during their reproductive years. Melasma may affect any races, it is much more common in darker skin types (skin types IV to VI). The disease prevalence among Asians is about 40% in females and about 20% in males.<sup>(5)</sup> The etiopathogenesis of melasma is multifactorial which includes genetic factor, sun exposure, hormonal influence, drugs, cosmetics and stress which play a role in the development of melasma. Therapeutic management of melasma was so far dependent on various combinations of topical,

systemic and physical modalities such as lasers and chemical peels. This study focuses on TXA in the management of melasma.

Tranexamic acid prevents the binding of plasminogen to the keratinocytes and thus inhibits UV-induced plasmin activity in keratinocytes. TXA being a plasmin inhibitor depletes the keratinocyte pool of Arachidonic acid (AA) involved in UV-induced melanogenesis.<sup>(6)</sup>

UVR stimulates the production of angiogenic factors such as VEGF, b-FGF and interleukin-8. VEGF interacts with VEGF receptors present in epidermal keratinocytes which release metabolites of AA and plasminogen from the proliferated vessels, leading to increased melanogenesis. Plasmin plays an important role in the release of VEGF and b-FGF, which are potent melanocyte growth factors, they promote melanocyte

proliferation and increased angiogenesis. TXA reduces VEGF and b-FGF by inhibiting plasmin conversion from plasminogen, hence suppresses neovascularisation and melanogenesis.<sup>(7,8)</sup> In treatment of melasma, TXA can be used orally, topically or intradermally by microneedling or microinjections.

Oral TXA was administered to melasma patients in a dose of 250 mg twice daily for 3 to 6 months. The dermal and mixed variants of melasma are highly resistant to treatment, and in such cases TXA may be administered intradermally. Derma roller used for minimally invasive microneedling treatment increases absorption of the topically applied compounds.

Wu U et al. reported in their study found out significant improvement in the physicians rating scale following oral TXA 250 mg twice daily administration for a period of 6 months for 74 patients, in which 54% had good outcome, 31.1% had fair outcome and 4.1% poor outcome in their study.<sup>(9)</sup>

Neerja puri et al in their study compared oral TXA Vs triple combination regimen for the treatment of melasma, where they found 64% of MASI score improved in oral TXA group, where as only 56% in triple combination therapy.<sup>(10)</sup>

Cristina C et al. evaluated the efficacy of the topical with TXA with micro needling in the treatment of melasma. There was significant reduction in MASI score from baseline. The mean MASI score reduced from 6.35 to 2.87 at 12<sup>th</sup> week of treatment.<sup>(11)</sup>

In a study done by Karn D et al. in treatment of melasma, oral TXA found to be relatively safe. They observed oligomenorrhea (14.7%), belching (9.2%) and abdominal cramps (6.9%) as side effects.<sup>(12)</sup> Hwee Chyen Lee et al. observed that relapse of melasma after stopping TXA 27.2% of those who improved and they suggested another course of TXA or other forms of therapy.<sup>(13)</sup>

Our study results are comparable with the studies which showed beneficial effects in melasma treatment following oral TXA and topical TXA with microneedling procedure were observed. We

observed significant improvement in both modalities of treatment, in which oral TXA shows higher improvement. We observed minimal side effect, but high relapse rate within three months of discontinuation of treatment. This suggests that TXA treatment should be long term, and needs to be maintained for an extended period of time. Further studies are needed to fix optimum duration of treatment for maintenance and prevention of relapse of melasma.

### Conclusion

In conclusion, this present study clearly shows that oral TXA has statistically significant clinical improvement of melasma when compared with topical TXA with micro needling. This study emphasizes that tranexamic acid is safe and promising drug in the treatment of melasma. Further research on the long term administration of tranexamic acid and reduction of recurrence rate also is needed.

### References

1. Poojary S, Minni K (2015) Tranexamic Acid in Melasma: A Review. *Pigmentary Disorders* 2:228. doi: 10.4172/2376-0427.1000228.
2. Sarkar R, Arora P, Garg VK, Sonthalia S, Gokhale N. Melasma update. *Indian Dermatology Online Journal*. 2014; 5(4):426-435. Sarkar R, Chugh S, Garg VK. Newer and upcoming therapies for melasma. *Indian J Dermatol Venereol Leprol* 2012; 78:417-28.
3. Nouveau S, Agrawal D, Kohli M, Bernerd F, Misra N, Nayak CS. Skin hyperpigmentation in Indian population: Insights and best practice. *Indian J Dermatol* 2016;61:487-95.
4. Bandyopadhyay D. Topical Treatment of Melasma. *Indian Journal of Dermatology*. 2009; 54(4): 303-309.
5. Katerina Damevska. New Aspects of Melasma *Serbian Journal of Dermatology and Venereology* 2014; 6 (1): 5-18.

6. Maeda K, Tomita Y. Mechanism of the inhibitory effect of tranexamic acid on melanogenesis in cultured human melanocytes in the presence of keratinocyte-conditioned medium. *J Health Sci* 2007; 53(4):389-96.
7. Kim EH, Kim YC, Lee ES, Kang HY (2007) The vascular characteristics of melasma. *J DermatolSci* 46: 111-116.
8. Kim MS, Bang SH, Kim JH, Shin HJ, Choi JH, Chang SE. Tranexamic acid diminishes laser-induced melanogenesis. *Ann Dermatol* 2015; 27:250-6.
9. Wu S, Shi H, Wu H, Yan S, Guo J, et al. (2012) Treatment of melasma with oral administration of tranexamic acid. *Aesthetic PlastSurg* 36: 964-970.
10. Neerja Puri\* Oral Tranexamic Acid Versus Triple Combination for The Treatment of Melasma, research article; *Jacobs Journal of Experimental Dermatology and Research*, 2015 Cristina C.Co, M.D., Ma. Flodeliz Abad.
11. Casinathan, M.D., FPDS, transepidermal delivery of tranexamic acid vs.placebo using the dermaroller in the treatment of melasma, <http://www.cassiacorrea.com.br>
12. Karn D, K C S, Amatya A et al. Oral tranexamic acid for the treatment of melasma. *Kathmandu Univ Med J.* 2012;10:40-3.
13. Lee, Hwee Chyen, Thng, Tien Guan Steven, Goh, Chee Leok Oral tranexamic acid (TA) in the treatment of melasma: A retrospective analysis *Journal of the American Academy of Dermatology*, ISSN: 1097-6787, Vol: 75, Issue: 2, Page: 385-92 Publication Year:2016.