



Retroperitoneal Mature Cystic Teratoma

Authors

Prof. P.Balaji, Dr Prabu.KT, Dr Gajendraraj

Department of Minimal Access Surgery, Madras Medical College, Chennai – 600003, India

Corresponding Author

Dr Prabu.KT

Department of Minimal Access Surgery, Madras Medical College, Chennai – 600003, India

INTRODUCTION

Teratomas are the germ cell tumors which comprises of tissues from all the three germ cell layers ⁽¹⁾. Primary retroperitoneal teratoma is a relatively rare tumour in adults. The primary retroperitoneal teratoma constitutes 6–11% of the retroperitoneal tumors. Sixty percent of the retroperitoneal teratomas occur in children less than 15 years.

It occurs more commonly in females than males. The order of frequency for teratoma is ovary, testis, mediastinum and the retroperitoneum being the last. Early diagnosis and surgery are the mainstay of treatment. We present a rare case of a retroperitoneal tumor in a 29-year-old patient, which was treated successfully with surgical resection. A review of the current clinical literature on this topic supports our management of this case.

Keywords: Retroperitoneal tumour, Mature cystic teratoma.

CASE REPORT

A 29-year-old male presented with progressively increasing mass and pain in the left side of the abdomen with no constitutional symptoms. On

physical examination there was a large lobular, firm mass occupying the whole of left side of the abdomen, reaching up to the right side of the abdomen. On evaluation, complete blood count, renal function and liver function tests were within normal range. Tumor markers like AFP, Beta HCG, LDH were within normal reference range. Ultrasonography of the abdomen showed a normal right kidney and large cystic tumor on the left side with left side hydro uretero nephrosis. On contrast enhanced CT (CECT) scan of the abdomen, there was a large non-enhancing mass of size 18 cm×15 cm×10 cm occupying the left side of abdomen with left side hydrouretero nephrosis. (Fig. 1). There was calcification on the tumor surface.

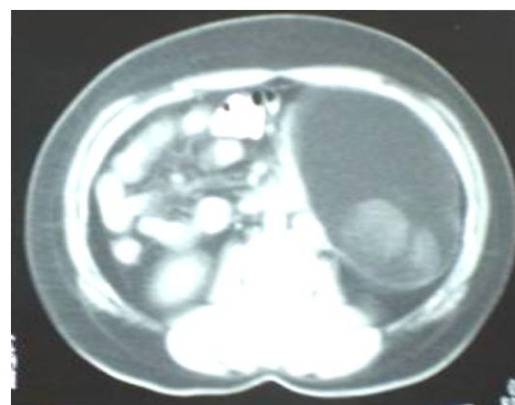


Fig 01

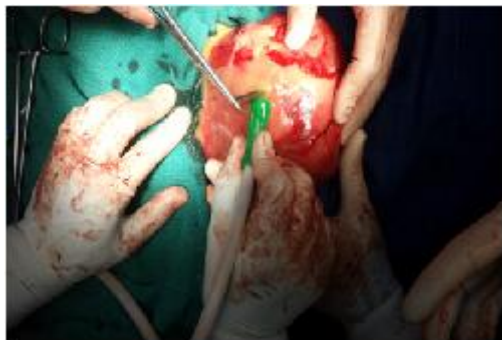

Fig : 2 (i)

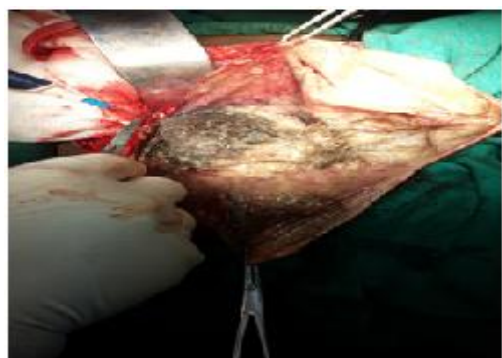


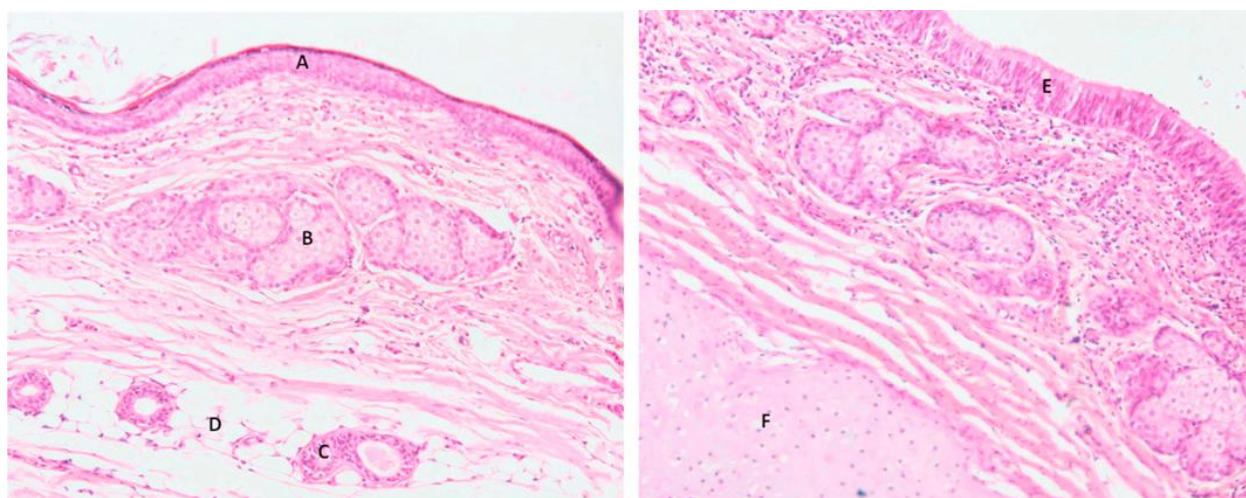
Fig : 2 (ii)

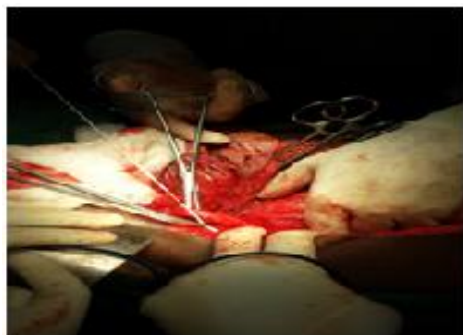

Fig : 2 (iii)

The patient was planned for surgery and Diagnostic laparoscopy was done followed by a formal laparotomy through a midline incision and the tumour was removed in toto. There was dense adhesion of the tumor to the left ureter but the tumour could be separated and the left ureter preserved. The tumor measured about 20 cm×19 cm×17 cm in size (Fig. 2(i),(ii) and (iii)). The cystic portion of the tumor was filled with gray-white greasy sebum, teeth and hair. Post operative period was unevenfull and patient was discharged home.

Microscopic examination of the tumor showed a cystic mass with presence of hair, adipose tissue, squamous epithelium, respiratory epithelium, cartilage and chronic inflammatory cell infiltrate



(Fig. 3)

Fig: 3 Microscopic examination (H&E section) showing the various components of germ cell layers such as (A) squamous epithelium, (B) sebaceous gland, (C) sweat gland, (D) adipose tissue, (E) respiratory tract epithelium and (F) cartilage.

There were no immature components identified microscopically. There was no evidence of malignancy in these components. The tumour was diagnosed as a mature cystic teratoma. Post operatively patient did well and is coming for regular follow-up.

DISCUSSION

Teratomas are the most common type of germ cell tumor in humans, and most of these neoplasms are benign. They are typically classified into three general categories: mature (cystic/ solid, benign), immature (malignant), and mondermal (highly specialized) ^[2]. Each of these histologies may present alone or in combination with others. A mature teratoma consists of an adult-type tumour with well-differentiated elements, while an immature teratoma consists of elements with only partial somatic differentiation, similar to those seen in embryonic or fetal tissue ^[4]. Teratomas often contain dermal elements and can also be classified by the type of epithelium and dermal tissue contained within the

tumour. Epidermoid teratomas contain stratified squamous epithelium; dermoid teratomas may contain any kind of epithelium and dermal elements such as hair and glands, and teratoid teratomas are lined with any respiratory epithelium (usually it is columnar epithelium) and contain sebum ^[1]. It is important to note that teratomas are always considered foreign to the anatomical region in which they are found

despite their tendency to differentiate into somatic-type tissues. It is thought that these cysts may develop by failure of meiosis I or from a premeiotic cell in which meiosis I has failed ^[2]. There is no specific tumor marker for teratomas although some immature (malignant) teratomas have been associated with elevated alpha-fetoprotein (AFP) levels ^[5].

Retroperitoneal teratomas are rare entities, representing only 1%–11% of all primary retroperitoneal tumors. Incidence is bimodal with peaks in the first 6 months of life and in early adulthood. Due to their location, they are usually

identified only after they have grown to huge proportions ^[6]. Additionally, the incidence of retroperitoneal teratomas in females is twice that in males. When retroperitoneal teratomas do occur, they are often located near the upper pole of the kidney, with preponderance on the left side. Although these tumors are mostly asymptomatic, they can cause abdominal distension and pain, as well as nausea and vomiting due to compression of surrounding structures ^[3]. The diagnosis of retroperitoneal teratoma often can be made on the basis of radiologic imaging. Retroperitoneal teratomas can be predominantly cystic or completely solid in appearance. A computed tomography (CT) scan or magnetic resonance imaging (MRI) can identify various components of these tumors, including bone, soft-tissue density structures, adipose tissue, and sebaceous and serous-type fluids. These imaging studies also can display the precise location, morphology, and adjacent structures of the tumor, which provide better preoperative planning and increased likelihood of complete removal of the tumor with less iatrogenic damage ^[4].

Surgical resection remains the mainstay of therapy for mature teratomas and is required for definitive diagnosis ^[6]. Resectability is determined by pathologic category and extent of tumor. Resection can include segments of the GI tract, kidney, bladder, spleen, aorta, and vena cava ^[7]. Torsion is common with these tumors, and if rupture occurs, sebaceous material can spill into the abdominal cavity, causing shock, hemorrhage, or a marked granulomatous reaction that can lead to adhesion formation ^[2]. An imaging study is critical for developing the preoperative strategy and performing a safe surgical excision.

Benign tumors, when resected, yield a 5-year survival rate of 100%. A long-term study showed that complete surgical resection is associated with the best survival rates for primary retroperitoneal tumors ^[7]. Disease-free survival following resection of teratoma is related to completeness of resection;

therefore, there are significant advantages to surgery with low volume disease. Moreover, there is the risk of malignant transformation of teratoma to carcinoma or sarcoma, so unresected teratoma may result in late relapse (defined as recurrence after a relapse-free interval of more than two years after completion of primary treatment). A late relapse often shows a slow growth and usually responds poorly to chemotherapy^[8].

Testicular ultrasound is necessary to rule out a coexisting testicular germ cell tumor in male patients. This is a necessary step since 50% of men with retroperitoneal tumors also have testicular carcinoma in situ, a precursor for testicular germ cell tumors^[5]. Long-term care also involves advising patients for regular follow up with annual CT to detect relapse at an asymptomatic phase^[8].

CONCLUSION

Primary retroperitoneal teratoma is a relatively rare entity in adults. Although usually asymptomatic, large neoplasms can cause abdominal and flank pain. Preoperatively, the diagnosis can be established by its characteristic appearance on computed tomography. The definitive treatment for these neoplasms is surgical resection and regular followup.

REFERENCES

1. R. J. Motzer and B. J. George, "Testicular cancer," in Harrison's Principles of Internal Medicine, 17e, A. S. Fauci, E. Braunwald, D. L. Kasper, et al., Eds., chapter 92, <http://www.accessmedicine.com/content.aspx?aID=2866870>.
2. D. Gershenson, "Ovarian germ cell tumors: pathology, clinical manifestations, and diagnosis," in UpToDate Patient Preview, B. Goff and A. S. Pappo, Eds., UpToDate, Waltham, Mass, USA, 2009.
3. K. Taori, J. Rathod, A. Deshmukh et al., "Primary extragonadal retroperitoneal teratoma in an adult," *The British Journal of Radiology*, vol. 79, no. 946, pp. 120–122, 2006.
4. H. Liu, L. Wanmeng, Y. Wenlong, and Q. Youfei, "Giant retroperitoneal teratoma in an adult," *The American Journal of Surgery*, vol. 193, no. 6, pp. 736–737, 2007.
5. T. Gilligan and P. Kantoff, "Extragonadal germ cell tumors involving the mediastinum and retroperitoneum," in *UpToDate Patient Preview*, W. K. Oh, Ed., UpToDate, Waltham, Mass, USA, 2009.
6. H. G. Gatcombe, V. Assikis, D. Kooby, and P. A. S. Johnstone, "Primary retroperitoneal teratomas: a review of the literature," *Journal of Surgical Oncology*, vol. 86, no. 2, pp. 107–113, 2004.
7. C. W. Pinson, S. G. ReMine, W. S. Fletcher, and J. W. Braasch, "Long-term results with primary retroperitoneal tumors," *Archives of Surgery*, vol. 124, no. 10, pp. 1168–1173, 1989.
8. R. Omranipour and M. Alavion, "Cervical mature teratoma 17 years after initial treatment of testicular teratocarcinoma: report of a late relapse," *World Journal of Surgical Oncology*, vol. 5, no. 1, 2007.