



Typical Electrocardiographic Changes in A Patient with Acute Oleander Poisoning - A Case Report

Authors

**Prof. Dr M.Senthivelan¹, Dr D.Kanagaraj², Dr H.Resveen³, Dr Jayaram Kosalram⁴,
Dr S.Senthilkumar⁵, Dr P.Suganya⁶, Dr G.Sivachandran⁷, Dr G.Arulvenkatesh⁸**

¹Senior Professor, Rajah Muthiah Medical College

²Postgraduate, Rajah Muthiah Medical College

³Assistant Professor, Rajah Muthiah Medical College

^{4,5,6,7,8}Postgraduates, Rajah Muthiah Medical College

Abstract

The yellow oleander (Thevetia peruviana) of Apocyanaceae family is common throughout the tropics and subtropics¹. Its seeds contain highly toxic cardiac glycosides like thevetins A and B and neriifolin. Ingestion of the seeds produces a clinical picture very similar to that of digoxin poisoning: gastrointestinal, central effects, and cardiac dysrhythmias like bradycardia, sinus and AV node block².

We report a case of Acute Oleander Poisoning in a 38 year old female patient who presented with ECG showing S-T segment depression with a "scooped" or "hockey stick" pattern that is fairly characteristic for digoxin toxicity. Yellow oleander poisoning resembles digoxin poisoning.

Introduction

The yellow oleander (*Thevetia peruviana*) of the Apocyanaceae family is commonly found throughout the tropics and subtropics³. All parts of the plant contain cardiac glycosides. These glycosides may include oleandrin, oleandroside, nerioside, digitoxigenin, thevetin, and thevetoxin⁴. Cardiac glycosides are toxic to cardiac muscle and the autonomic nervous system. Ingestion of the plant parts results in a clinical picture like that of digoxin poisoning^{5,6}. All parts of the plants are poisonous can cause multiple arrhythmias such as A-V blocks, bradycardia, ventricular excitability. It may also results in gastrointestinal symptoms as diarrhea, vomiting, gastric or intestinal hemorrhages⁷. Patients with moderate poisoning may present with PR interval prolongation and may progress to AV dissociation

which must be treated with temporary cardiac pacing².

Accidental poisoning are more common in the tropics, particularly in children. Adults have died after consuming oleander leaves as herbal treatment. However, deliberate ingestion of yellow oleander seeds has recently become a popular method of self harm. There are thousands of cases each year, with case fatality rate of about 10%^{8,9}. Most of which are due to accidental ingestion, but in some instances it may be due to suicidal or homicidal purposes¹⁰.

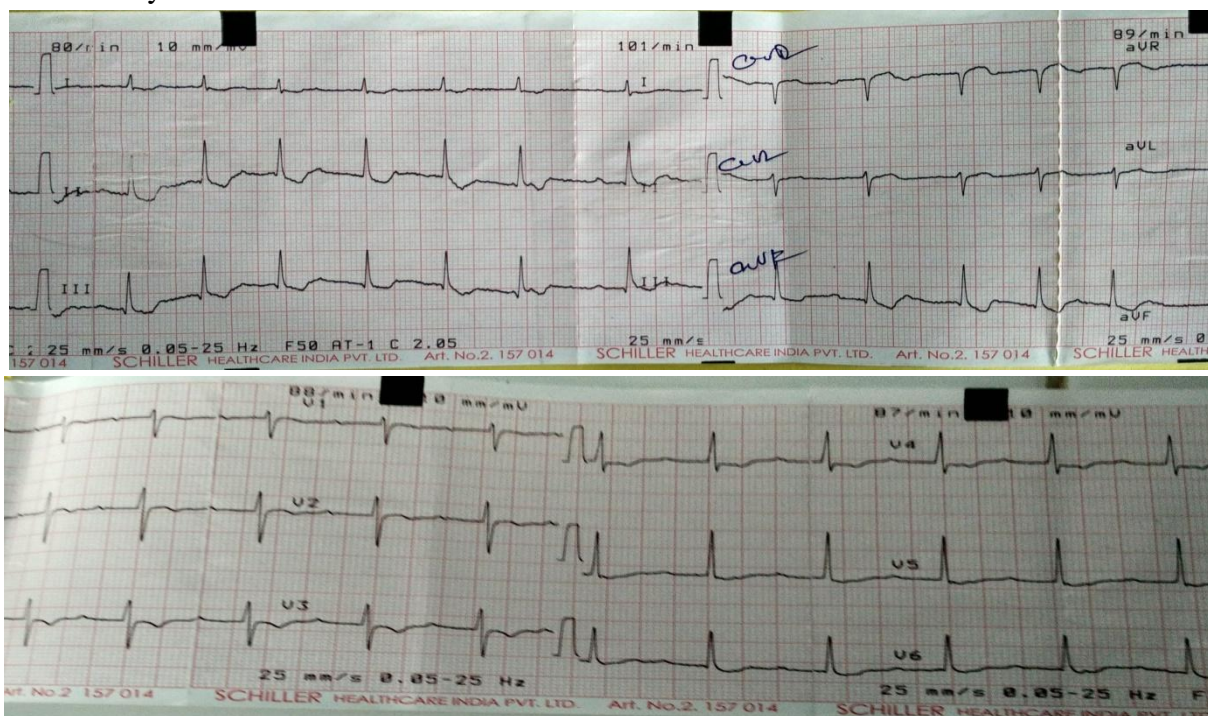
Case Report

A 38 year-old female was brought with alleged history of consumption of about 100 ml of fluid in which she boiled 4 oleander leaves and 2 flowers. She confessed that she had taken it

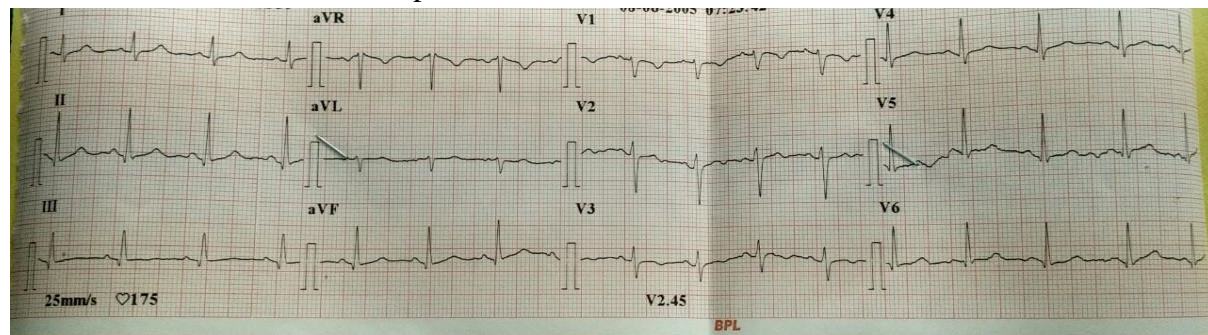
thinking it as medication for urinary tract infection and constipation. She had no previous history of cardiovascular disorders and was not on any medication for any of the disorders. Her heart rate was 82 bpm and blood pressure was 110/70 mmHg, temperature 37.1°C; respiration rate 18 breaths/min. General examination was normal. Examination of her head, eyes, ears, nose, and throat was normal. Bilateral pupils were equal and reactive to light and accommodation. On examination of respiratory system chest and lungs were normal. Cardiovascular examination revealed no abnormality. On abdominal examination it was soft, bowel sounds were active, non tender, no mass or no organomegaly. Initial laboratory studies revealed a serum sodium level of 140

mmol per liter (mEq per liter), a potassium of 5.4 mmol per liter (mEq per liter). ECG revealed S-T segment depression with a “tick sign” or “scooped” or “hockey stick” pattern, that is fairly characteristic for digoxin toxicity. She was admitted in CCU with constant ECG monitoring and supportive care. 2D Echo was found to be normal. After 6 days, she was discharged with a normal ECG. The present case is a poisoning report with oleander decoction in a subject who subsequently recovered following supportive care including NG washing, hydration. This report of non-fatal oleander poisoning underlines the importance of toxicological screenings and treatment depends on the patient’s neurological, cardiac and circulatory stability.

Day 1 ECG: S-T segment depression with a “tick sign” or “scooped” or “hockey stick” pattern characteristic for digoxin toxicity



Day 6 ECG: Normal ECG of the same patient with conservative treatment



Discussion

The yellow oleander tree (*Thevetia peruviana*) of the family Apocynaceae has a characteristic funnel shaped yellow flowers and green fruits with a single seed⁸. Parts of the plants contain highly toxic cardiac glycosides like oleandrin, oleandroside, nerioside, digitoxigenin, thevetin, and thevetoxin^{6,8}. They are ingested accidentally or intentionally for suicidal attempts leading to oleander poisoning¹¹. Poisoning most commonly occurs due to consumption of its seeds. The severity of poisoning may be related to the number of seeds consumed. It has been shown from some studies that consumption of more than 5 crushed seed resulted in significant manifestation, the fatal dose being 8 to 10 seeds¹². Other studies have shown that the lethal dose was between 4 to 7 seeds².

The cardiac glycosides in oleander produce gastrointestinal symptoms (nausea, vomiting, abdominal pain, diarrhea), cardiovascular symptoms [sinus bradycardia, atrioventricular (AV) block and fibrillation]¹³ and central nervous system manifestations (Confusion, dizziness, drowsiness, weakness, visual disturbances, and mydriasis^{5,6,8}). Symptoms may occur 2 to 3 hours after ingestion which includes vomiting (50-90%), restlessness (50-75%), bradycardia (56-63%), other arrhythmias (35-60%), hypotension (23-77%), abnormalities of the nervous system (5-10%), diarrhoea (5-10%), and abdominal cramps (8%)¹⁴.

The cardiac glycosides of oleander produce more gastrointestinal effects than that of digoxin¹. Gastrointestinal effects may be secondary to local effects. Cardiotoxicity of oleandrine is due to inhibition the activity of of Na⁺ -K⁺-ATPases which results in an increase of intracellular Ca⁺⁺, responsible of inotropic effect¹⁵. The most serious toxicity of oleander poisoning is cardiotoxicity which may manifest as bradycardia, tachyarrhythmias, various ventricular dysrhythmias and heart block^{2,16}. The most common arrhythmias are conduction defects like sinus bradycardia, sinus arrest or exit block and second or third degree heart block¹. The electrocardio-

graphic abnormalities like sinus bradycardia, ST segment depression, inversion of T waves, a decreased QRS-T interval, PR prolongation, AV dissociation, may occur and in large doses may result in ventricular tachycardia and ventricular fibrillation¹⁶.

Rhythms characteristic of Mobitz type II AV conduction block that were rare in isolated digoxin poisoning can occur in the oleander poisoning. Atrial fibrillation and flutter, Ventricular ectopic beats were uncommon in a study on oleander poisoning¹.

Cardiotoxicity could manifest itself by hyperkalaemia, hyponatremia, and hypomagnesaemia. Hyperkalaemia exacerbates glycoside induced cardiac arrhythmias and hence a marker of a poor outcome in cardiac glycoside poisoning¹. Hyperkalemia in the initial stage of intoxication may worsen the prognosis because deaths occur due to dysrhythmias¹⁷. Serum magnesium concentrations are not altered by oleander poisoning but it does not preclude the possibility that hyper or hypo magnesemia before the poisoning might affect the outcome¹. Hypokalemia may occur in digoxin poisoning in patients taking therapeutic digoxin and diuretics¹⁸. But this is an uncommon in both oleander poisoning and suicidal digoxin overdose¹.

DETERMINATION OF SEVERITY

The determination of severity of toxicity is by clinical grading of toxicity¹⁵. Patients with acute oleander poisoning must be closely monitored for changes in severity of cardiotoxicity. Death usually occurs 6-24hr post-exposure.

Asymptomatic - no abnormalities on physical or laboratory examination

Mild - predominantly gastrointestinal symptoms with flattening or inversion of the T wave and depression of the ST segment

Moderate - First degree heart block, sinus bradycardia, sick sinus syndrome (sinus arrest or sinus block)

Severe - Second or third degree heart block, ventricular fibrillation and death¹⁵.

The diagnosis can be confirmed with the clinical features of glycoside toxicity and by doing digoxin radioimmunoassays by using an antibody with a broad specificity for glycosides. The cross-reactivity between digoxin radioimmunoassays and the glycosides of oleander can identify the presence of a cardioactive glycoside in cases of unknown poisoning. Digoxin radioimmunoassay is not specific for all the glycosides of oleander. The use of it in oleander toxicity will only indicate the presence of glycoside but may not indicate the degree of toxicity².

Cardiac monitoring for 72 hours is necessary in patients with oleander poisoning. Activated charcoal should be given within 1 hour of ingestion. Antiemetics may be administered. Hypotension if occurs should be treated with intravenous fluids^{2,11}. Electrolyte imbalances should be corrected. Temporary cardiac pacing may be advocated for treatment of severe cardiotoxicity despite administration of antidotes¹⁹. Atropine (0.6mg bolus) may be useful for reversing bradycardia. Atropine bolus is followed by an infusion to maintain the pulse rate above 80 beats/min. Larger doses of atropine 2-3mg are only used for bradycardia less than 40 beats/min accompanied by hypotension².

Anti-digoxin Fab antitoxin, is the first line treatment for reversal of cardiotoxicity of glycoside poisoning. The indications for Fab may be when there occurs 2nd or 3rd degree AV block, sinus bradycardia < 40 beats/min, sinus arrest or exit block, atrial tachyarrhythmias, hypotension (SBP < 80 mmHg) and bradycardia or ventricular tachycardia associated with shock. An empiric intravenous dose of 1200mg of Fab is recommended. It is important that some patients may redevelop dysrhythmias after treatment with anti digoxin Fab antitoxin hence monitoring for 24-48hr post-administration of the Fab antitoxin is therefore recommended²⁰.

Conclusion

The yellow oleander contains highly toxic cardiac glycosides which are toxic to cardiac muscle and the autonomic nervous system. The most serious

cardiotoxicity which may manifest as bradycardia, tachyarrhythmias and heart block. The early diagnosis could be confirmed by the clinical features of glycoside toxicity and characteristic ECG changes and doing digoxin radioimmunoassays could reduce the morbidity and mortality due to oleander poisoning.

References

1. Eddleston M, Ariaratnam CA, Sjostrom L, Jayalath S, Rajakanthan K, Rajapakse S. 2000. Acute yellow oleander (*Thevetia peruviana*) poisoning: cardiac arrhythmias, electrolyte disturbances and serum cardiac glycoside concentrations on presentation to hospital. *Heart*, 83:301-306.
2. Eddleston M, Ariaratnam CA, Meyer PW. 1999. Epidemic of self-poisoning with seeds of the yellow oleander tree (*Thevetia peruviana*) in northern Sri Lanka. *Trop Med Int Health*, 4:266 - 273.
3. Pearn J. Oleander poisoning. In: Covacevich J, Davine P, Pearn J, eds. *Toxic plants and animals: a guide for Australia*, 2nd ed. Brisbane: William Brooks, 1989:37-50.
4. Osterloh J, Herold S, Pond S: Oleander interference in the digoxin radioimmunoassay in a fatal ingestion. *JAMA* 1982; 247:1596-1597
5. Sreeharan N, Putharasingam S, Ranjadayalan K, et al. Yellow oleander poisoning—clinical manifestations and prognostic criteria. *Javna Med J* 1985; 20:100-1.
6. Saravanapavanathan N, Ganeshamoorthy J. Yellow oleander poisoning—a study of 170 cases. *Forensic Sci Int* 1988; 3 6:247-50.
7. oRVAn A., mAHAM m., ReZAKHAnI A., mALcKI m., morphological studies on experimental oleander poisoning in cattle, *Zentralbl. Veterinarmed.*, 1996, Dec. 43(10); 625-34.
8. Langford SD, Boor PJ. Oleander toxicity: an examination of the human and animal

- toxic exposures. *Toxicology* 1996; 109:1-13
9. Brewster D. Herbal poisoning: a case report of a fatal yellow oleander poisoning from the Solomon islands. *Ann Trop Paediatr* 1986; 6:289-91.
 10. L. Papi, A. B. Luciani, lethal poisoning from oleander. *Imprensa da Universidade de Coimbra; International Academy of Legal Medicine* 2015;307-309.
 11. P Peymani*, N Zamiri A Case of Non-Fatal Oleander Poisoning Iran *Red Crescent Med J* 2011; 13(3):219-220
 12. Lokesh S, Arunkumar R, A clinical study of 30 cases of yellow oleander poisoning (*Thevetia nerifolia*). *Journal of current trends in clinical medicine & laboratory biochemistry*; 1; 2; 2013.:28-31.
 13. Pietsch J, Oertel R, Trautmann S, Schulz K, Kopp B, Dressler J. A non-fatal oleander poisoning. *Int J Legal Med* 2005;119:236-40. [15906057] [doi:10.1007/s00414-005-0548-6]
 14. Dev, V. and Wasir, H. S.: Digitalis poisoning by an indigenous plant cardiac glycoside, *Ind. Heart J.*, 37: 321-322, 1985.
 15. Jorjans, HeL RA, VALDES R Jr, Inhibition of Na⁺, K⁺-ATPase by oleandrin and oleandrigenin and their detection by digoxin immunoassays.
 16. Dev, V. and Wasir, H. S.: Digitalis poisoning by an indigenous plant cardiac glycoside, *Ind. Heart J.*, 37: 321-322, 1985.
 17. IPCS International Programme on Chemical Safety. Nerium oleander L. Available from: <http://www.inchem.org/documents/pims/plant/pim366.htm>.
 18. Smith TW, Antman EM, Friedman PL, et al. Digitalis glycosides: mechanisms and manifestations of toxicity (parts I-III). *Prog Cardiovasc Dis* 1984; 26:413-58, 495-540; 27:21-56.
 19. Kelly RA, Smith TW :Recognition and management of digitalis toxicity. *Am.J.Cardiol.* 1992;69(18):108G-18G.
 20. Eddleston M, Rajapakse S, Jayalath S, Sjoström L, Santharaj W et al : Ant - digoxin Fab fragments in cardiotoxicity induced by ingestion of yellow oleander: a randomized controlled trial. *Lancet* 2000;355(9208):967-72.