



## Role of 3D /4D Ultrasound and Fetal Magnetic Resonance Imaging in the evaluation of various fetal anomalies in First and second trimester

Authors

Dr Deepthi. K<sup>1</sup>, Dr Shanthi Sree .V<sup>2</sup>, Dr Hanumath Prasad .V<sup>3</sup>, Dr Shivani Gogi<sup>4</sup>,  
Dr Veena<sup>5</sup>, Dr Anil Kumar<sup>6</sup>

<sup>1</sup>Postgraduate Student, <sup>2,3</sup>Associate Professor, <sup>4,5,6</sup>Assistant Professors

Department of Radio-Diagnosis, Gandhi Medical College, Hyderabad, Telangana State, India

Corresponding Author

Dr Shanthi Sree .V

Email: [drshanthisree@yahoo.com](mailto:drshanthisree@yahoo.com)

### Abstract

**Aims & Objectives:** 1) To evaluate Fetal anomalies by 3D/4D Sonography 2) To compare the imaging findings as seen on 2D ultrasonography with 3D /4D Sonography.3) To Compare the 3D /4 D Sonographic findings with Magnetic Resonance Imaging findings.

**Summary:** In the present study, the sensitivity and specificity of 3D/4D Ultrasound is 94.4% & 88.8% respectively and that of MRI is 98.1% and 90% respectively.

**Conclusions:** 3D ultrasound is highly sensitive in detecting foetal anomalies and MRI can be used for confirmation in selected cases. The advent of 3D Ultrasound enables Ultrasound to compete with CT and MR imaging for efficiency and rapidity.

**Keywords:** Fetal anomalies , 3D/4D Sonography, Fetal Magnetic Resonance Imaging

### Introduction

Standard two-dimensional (2D) ultrasonography has been the cornerstone of prenatal diagnosis of fetal malformations since its inception in the early 1970s. This has remained true despite conflicting literature regarding its accuracy in detecting major congenital anomalies. Three dimensional ultrasonography is a new diagnostic technique undergoing rapid advances in the recent few years. It provides completely new modalities of sonographic imaging including coronal section imaging, 3Dimensional spatial reconstruction and volumetric calculations<sup>1</sup>. It may be a useful adjunct to standard two-dimensional (2D) imaging

of the neonatal brain<sup>2</sup>. Development of 3D/4D ultrasound of the fetus has received much attention for its social benefits<sup>3</sup>. It permits acquisition of a volume of sonographic data to be displayed in many different ways, including surface rendering of an interface and multislice reconstruction of any scanned plane. This advance has permitted sonography to participate in cross-sectional imaging, much the way contemporary MRI and CT, This technology allows examiners to move from a 3D mental reconstruction of two-dimensional (2D) images to actual 3D visualization of anatomical structures<sup>5</sup> The major advantage of 3D, or “volume,” US, however, is its

potential to change the practice of US<sup>7,8</sup>. This change could render US far less operator-dependent, markedly decrease scanning times, and standardize the entire process of performing an examination. The advent of 3D US enables US to compete with CT and MR imaging for efficiency and rapidity<sup>8</sup>. Fetal magnetic resonance imaging (MRI) was first described in the 1990s, but image degradation by fetal motion and the relatively long acquisition time discouraged the use of MRI for the examination of fetal anatomy<sup>15</sup>. The use of MRI was successively re-evaluated with the introduction of ultrafast techniques, which minimized fetal movement artifacts and improved visualization of fetal images<sup>11</sup>. Factors leading to its popularity include its rapidity and increasing awareness of its use, applications, and safety. Fetal MRI is particularly valuable in resolving incongruent or uncertain sonographic findings, fetal assessment prior to in-utero surgery, and clarification of specific anomalies, particularly those involving the fetal brain.

### Materials and Methods

All patients admitted in the Department of Obstetrics & Gynecology, Gandhi Hospital are referred for evaluation of foetal anomalies initially by 2D ultrasonography. Positive cases are further evaluated by 3D /4D evaluation on MY LAB CLASS C COLOR DOPPLER SYSTEM of

ESOATE LTD with the convex volume probe . Patients presenting with foetal anomalies are further evaluated with MR imaging by 1.5 Tesla (AVANTO) systems (SIEMENS LTD). The study extended for a period of nineteen months from February 2014 to August 2015.

**Sample Volume:** 63 cases positive cases.

**Inclusion Criteria:** All antenatal patients with previous diagnosis of foetal anomalies in the 1<sup>st</sup> and 2<sup>nd</sup> trimester were taken for the study.

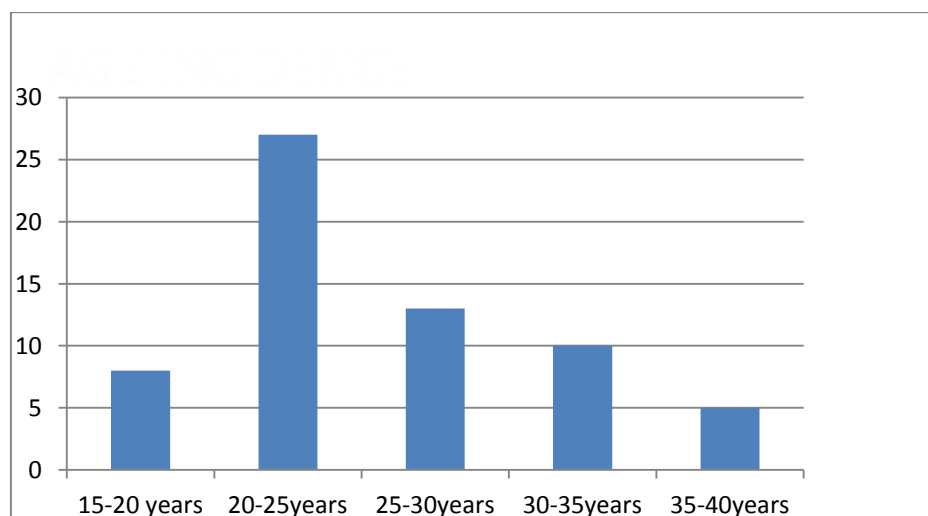
**Exclusion Criteria:** All the antenatal patients with GA > 32wks, patients in labour, patients with APH were excluded from the criteria. Most commonly used MRI sequences in the present study for fetal imaging are Axial, coronal, sagittal T2 Weighted True FISP, Axial, coronal, sagittal T2 Weighted HASTE and T2 Weighted HASTE thin / thick slabs.

### Observations& results

It is a prospective study of 3D/4D Ultrasonography and fetal MR imaging with previous diagnosis of evidence of anomalies on 2D ultrasonography. The study extended for a period of nineteen months from February 2014 to August 2015 on a sample volume of 63 positive cases

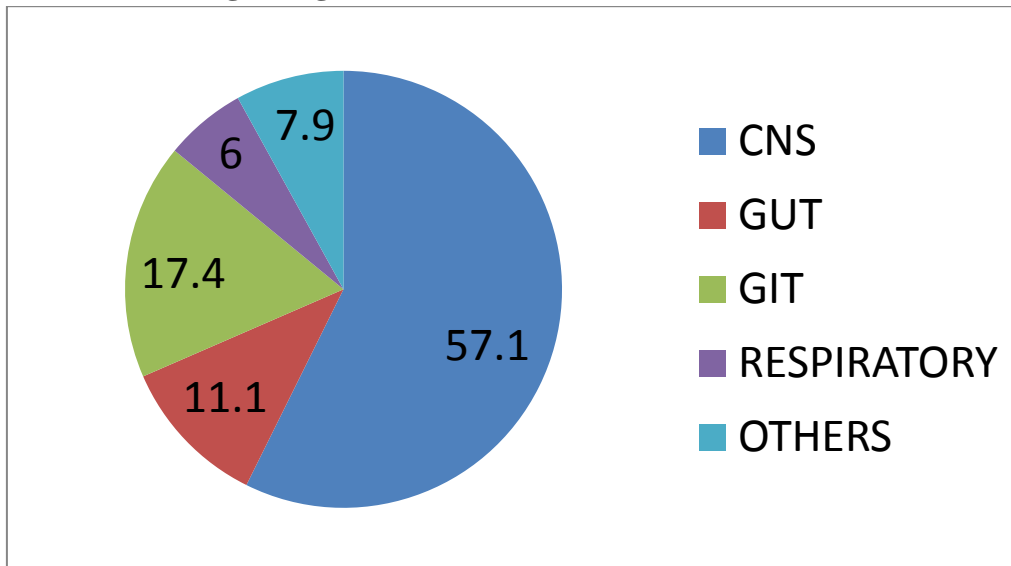
### Age Distribution

The majority of the cases in our study are in younger age group between 20 to 30 yrs.



**Pic 1:** In the present study, the maximum incidence of cases is seen in younger age group between 20 -25 yrs ( 27 % ) followed by (13 % ) in 25 -30yrs.

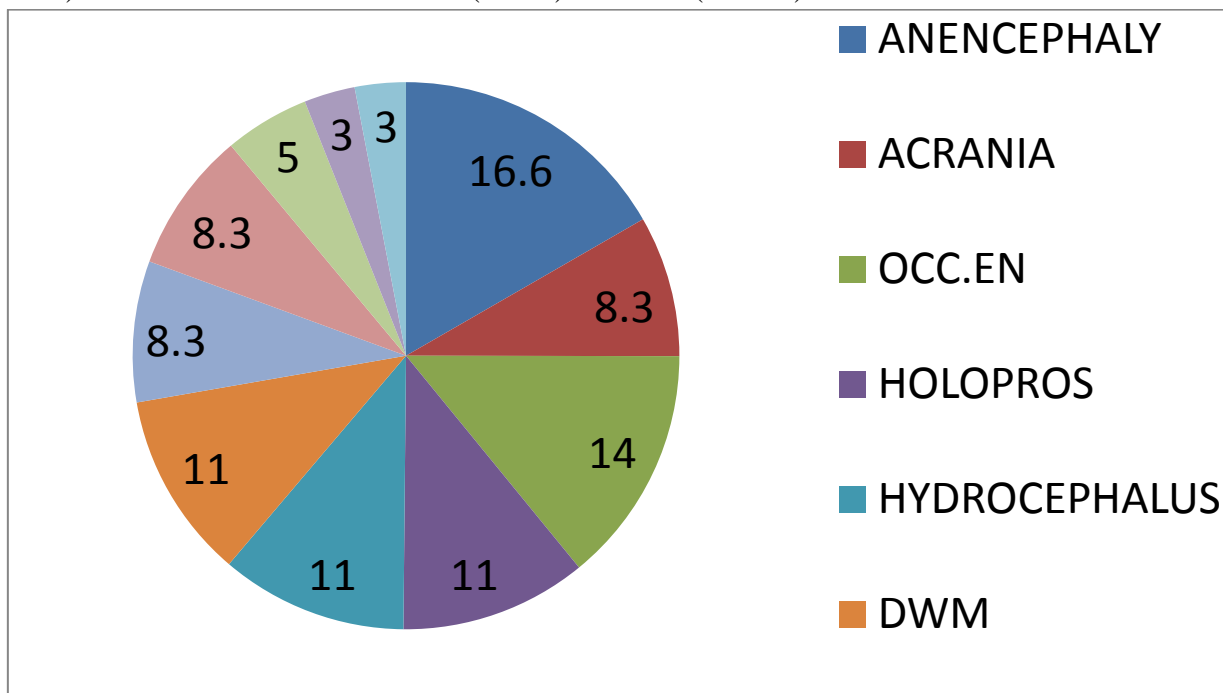
**Distribution of cases according to organ of involvement**



**Pic 2:** In the present study, the commonest anomalies were in central nervous system (57.1 %) followed by Gastrointestinal anomalies at 17.4 % genitourinary anomalies at 11.1%, respiratory anomalies at 6 % & others included 7.9 % of cases

**CNS involvement**

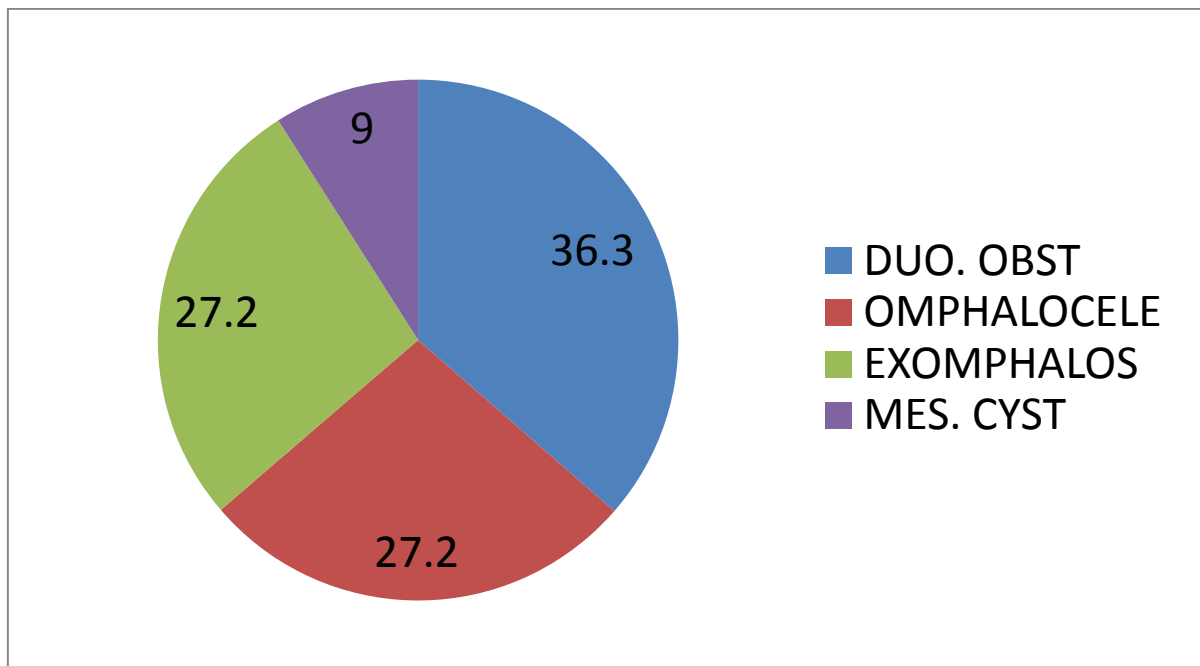
36 out of 63 cases (57.1%) showed central nervous system involvement of which the commonest were Anencephaly (16.6 %) followed by Encephalocele (7.9%) Holoprosencephaly & Dandy Walker syndrome (6.3% each) Arnold –Chiari malformation (4.7 %) & others (15. 3%)



**Pic 3:** Distribution of percentage of cases involving the central nervous system in the present study

**Gastrointestinal system**

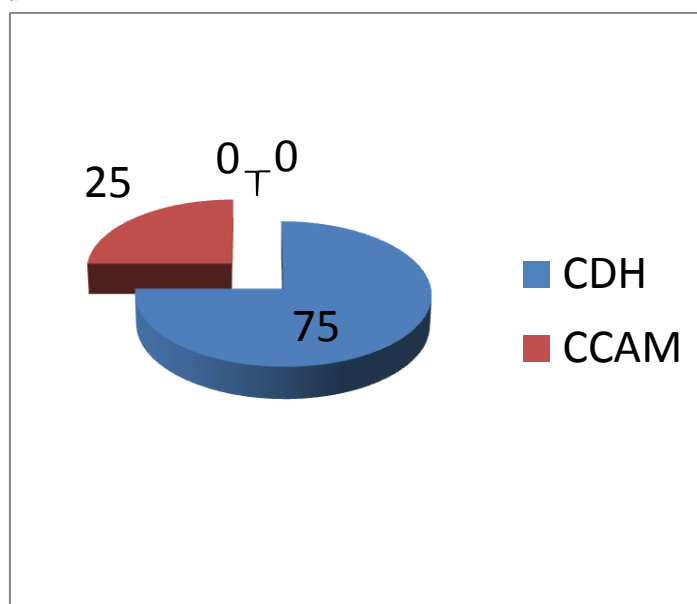
In the present study group, 3 out of 63 cases were found to be omphalocele, 4 cases were of duodenal obstruction, 3 cases were of exampholos & 1 cases was of mesenteric cyst



**Pic 4:** Distribution of percentage of cases involving the gastrointestinal system in our study group. The commonest anomaly was duodenal obstruction (36.3%) followed by Omphalocele & exampholos (27.2% each) & mesenteric cysts (9 %)

**Respiratory System**

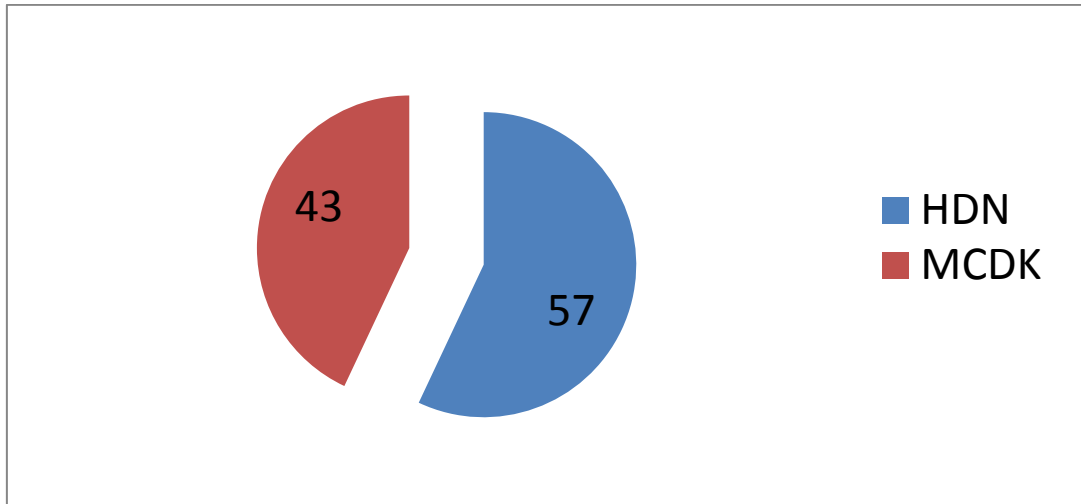
In the present study, 3 cases of congenital diaphragmatic hernia & 1 case of congenital cystic adenomatoid malformation were detected



**Pic 5:** Distribution Of percentage of cases involving the respiratory system

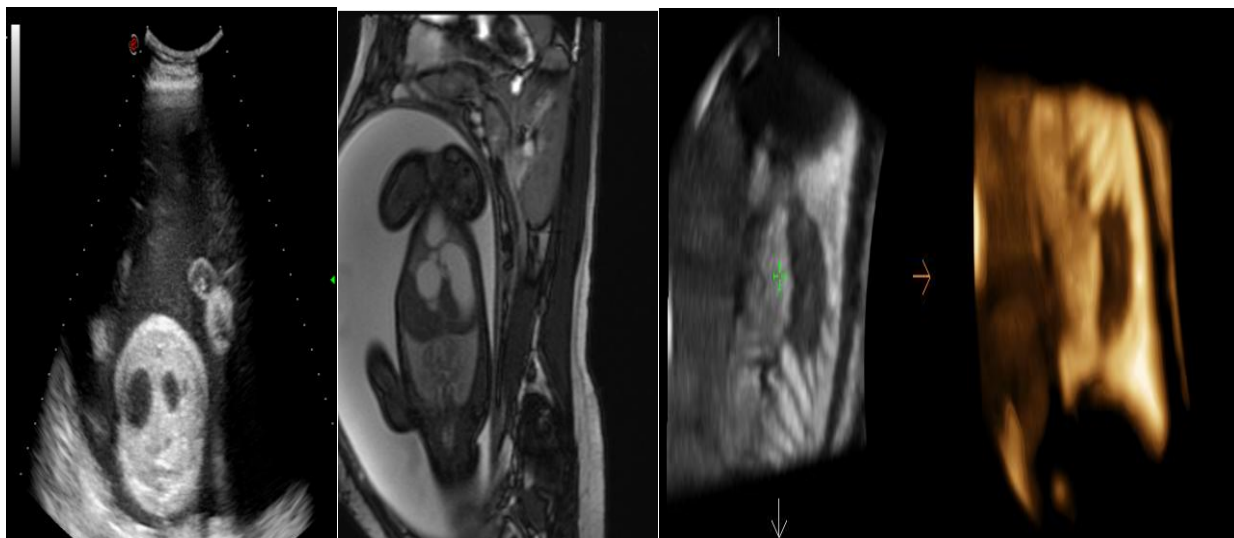
**Genitourinary System**

In the present study, 3 cases out of 63 (4.7%) were diagnosed as Multicystic Dysplastic Kidneys & 4 cases were of hydronephrosis (6.3 %)



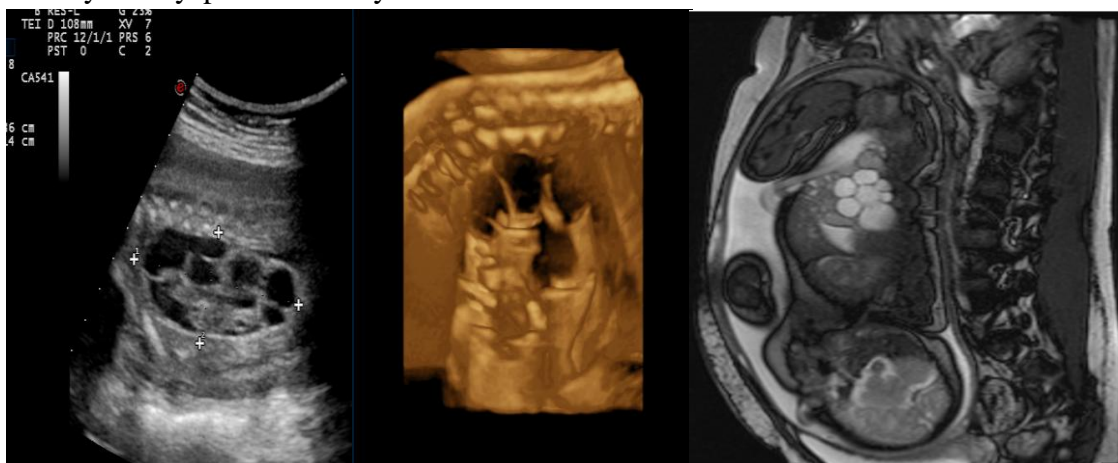
**Pic 6:** depicts the percentage of cases of multicystic dysplastic kidney (57 %) and hydronephrosis (43 %) in the present study

**CASE 1 - Duodenal Obstruction**



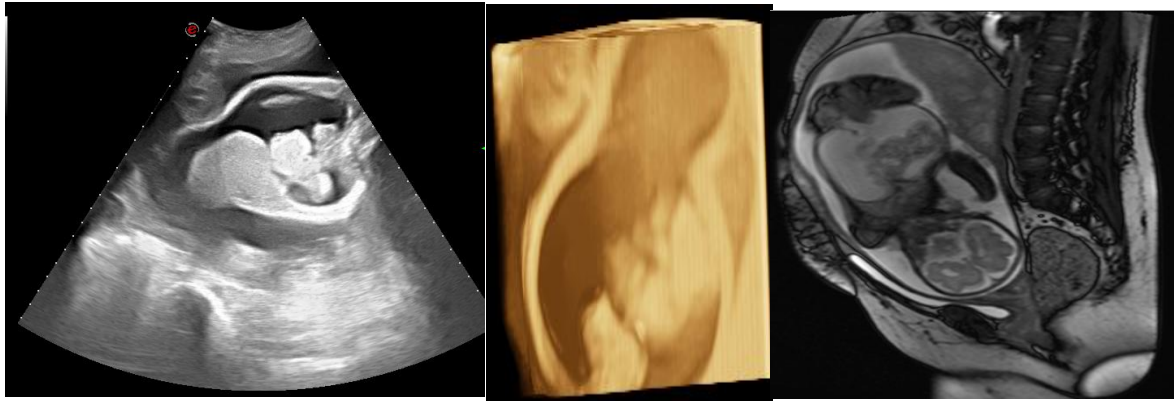
2D and 3D Ultrasound in a 28year old primi of 29 weeks gestational age with non consanguineous marital history showed the presence of Double bubble appearance characteristic of Duodenal Obstruction.

**CASE 2- Multicystic Dysplastic Kidney**

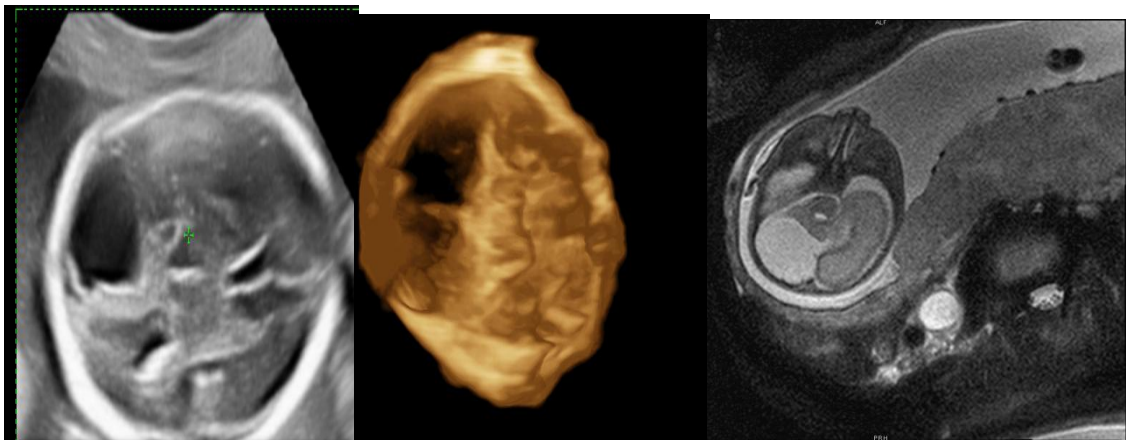


2D, 3D and MR imaging in a 31 year old primi of 28weeks GA with consanguineous marital history showed presence of multiple cystic areas in the left kidney – suggestive of unilateral multicystic dysplastic kidney.



**CASE 3- Exomphalos**

A 21 year old primigravida with 32 weeks of gestational age showed the presence of herniation of abdominal contents into a membrane covered defect suggestive of exomphalos.

**CASE 4 - Posterior Fossa Arachnoid Cyst**

A 24 year old primigravida with 30 weeks of gestational age showed the presence a cystic lesion in the posterior fossa with slight mass effect on the adjacent parenchyma suggestive of Arachnoid cyst.

**Discussion**

Three dimensional ultrasonography provides completely new modalities of sonographic scanning including coronal section imaging, 3dimensional spatial reconstruction and volumetric calculations. Three-dimensional (3D) ultrasound technology contains every conceivable plane within the region of interest. Fetal MRI is particularly valuable in resolving incongruent or uncertain sonographic findings, fetal assessment prior to in-utero surgery, and clarification of specific anomalies, particularly those involving the fetal brain. A diagnosis by fetal MRI should include management and prognostic considerations, which require knowledge about genetics, the disease course, and potential antenatal and postnatal therapies<sup>12</sup>.

**Anencephaly**

In the present study 6 out of 63 cases were found to be anencephaly. It also accounts for 16.6% of the central nervous system anomalies. 5 out of 6 cases were detected and confirmed by 3D/4D ultrasound and foetal MRI. The sensitivity & specificity of 3D/4D ultrasound and foetal MRI were found to be equal in our study (3D/4D = MRI).

**Holoprosencephaly**

In the present study 4 out of 63 cases (6.3%) were found to be holoprosencephaly of which two are semilobar holoprosencephaly and two are alobar holoprosencephaly. Partial division of cerebral hemispheres in semilobar holoprosencephaly is better appreciated in 3D/4D (3D/4D > MRI) where as presence of monoventricle and fused thalami in

case of alobar holoprosencephaly is well demon

### **Dandy-Walker Malformation**

In the present study 4 out of 63 cases (6.3%) were found to be Dandy-Walker Malformation. Communication of posterior fossa cystic lesion with the fourth ventricle is better demonstrated on foetal MRI compared to 3D/4D ultrasound (3D/4D <MRI). As per the study done by Catherine Limperopoulos et al.(12) on MRI of the fetal anomalies 15 cases of Dandy-Walker Malformation were detected out of 90 cases of suspected posterior fossa anomalies constituting about 25 % cases, In our study, 6.3 % cases were of Dandy-Walker Malformation. We agree with the conclusion of above mentioned study that current fetal MRI has limitations & support the need for post natal follow up in cases with suspected posterior fossa anomalies MRI has a high sensitivity for cortical malformations such as lissencephaly, polymicrogyria, and schizencephaly. Early detection of cerebral insults can be particularly helpful in cases of acquired cerebral injury.

### **Arnold –Chiari Malformations**

In the present study 3 out of 63 cases (4.7%) were found to be Arnold-Chiari Malformation of which 2 out of 3 are type II and 1 out of 3 cases is type I. 2 out of 2 cases (100%) were equally appreciated on 3D/4D and foetal MRI (3D/4D = MRI). 1 out of 3 cases (33.3%) is better appreciated on MRI compared to 3D/4D ultrasound (3D/4D < MRI). Manal Hamisaa, Naglaa Dabeesa, Walid M. Ataallah, Dina H. Ziadac (2013),(13) in their study on Magnetic resonance imaging versus Ultrasound examination in detection of prenatal fetal brain anomalies MRI and ultrasound showed concordant findings in six cases. MRI changed the diagnosis in 14 cases and provided additional information in two cases. Ultrasound was superior to magnetic resonance imaging in one case at second trimester due to fetal motion. Our results showed that fetal MR imaging is useful in detection of fetal central nervous system anomalies as well as a complementary modality to

2D/4D Ultrasound in diagnosis of fetal central nervous system anomalies.

### **Occipital Encephalocele**

In the present study 5 out of 63 cases (7.9%) were found to be Occipital Encephalocele. Defect in the occipital bone is well noted with 3D/4D ultrasound compared to foetal MRI (3D/4D >MRI)

### **G.I.T Abnormalities**

For complete 3-dimensional Fetal MRI evaluation of the gastrointestinal system, both the volume-interpolated and SSFP sequences should be acquired. Using a combination of thin-slab MIP and VR techniques, 3-dimensional VI is applied exclusively to assess the meconium filled colon. Three dimensional SSFP is used for all other applications, including fetal biometry, with MPR, MIP and/or VR techniques. In the present study 3 out of 63 cases (4.7%) were found to be Omphalocele. It accounts for 27.2% of gastrointestinal tract anomalies. Abdominal wall defect with protrusion of bowel loops and covering sac were well noted on 3D/4D ultrasound compared to fetal MRI (3D/4D > MRI). Sensitivity & Specificity of 3D sonography was found to be 100 % whereas that of fetal MRI was 66 %. In the present study 4 out of 63 cases (6.3%) were found to be Duodenal obstruction. It accounts for 36.3% of gastrointestinal tract anomalies. Double bubble appearance was equally appreciated on 3D/4D ultrasound and foetal MRI (3D/4D = MRI). Sensitivity & Specificity of 3D sonography was found to be 100 % whereas that of fetal MRI was also 100 % . A retrospective study over a period of 5 years done by Milan Stanojevic et al, in 2014 (14) concluded that 3D Ultrasound provides equivalent information to 2DUS in 45%, additional information in 51% of fetal anomalies and disadvantageous in 4%. Cohen overbeek, in his study on 91 cases showed 28(30.7%) cases of duodenal obstruction were detected prenatally<sup>(10)</sup>.

### **Cystic Hygroma**

In the present study 4 out of 63 cases (6.3%) were found to be Cystic hygroma. Presence of septations in the case of cystic hygroma are better

appreciated on 3D/4D compared to foetal MRI (3D/4D = MRI). Sensitivity & Specificity of 3D sonography was found to be 100 % whereas that of fetal MRI was also 100 %. Kang L, Chang CH, Yu CH, Cheng YC, Chang FM in their study on Prenatal depiction of cystic hygroma using three-dimensional ultrasound <sup>(9)</sup> found that the diagnostic rates by 2-D US and 3-D US were both 100% (23 of 23), notably, 3-D US can provide additional vivid illustrations in 3-D after various modes of reconstruction, but 2-D US cannot. In conclusion, 3-D US may add novel visual depiction of the lesion in 3-D after reconstruction and, thus, assists substantially in prenatal consultation.

### **Multicystic Dysplastic Kidney**

In the present study 3 out of 63 cases (4.7%) were found to be Multicystic Dysplastic Kidney. It accounts for 37.5% of genitourinary tract anomalies. Presence of multiple cystic areas within the kidney are equally appreciated on 3D/4D and foetal MRI (3D/4D = MRI). Sensitivity & Specificity of 3D sonography was found to be 100 % whereas that of fetal MRI was also 100 %. Nabeel S. Bondagji, <sup>(6)</sup> in 2014 in his study on 141 cases of urinary tract anomalies, postnatal diagnosis was confirmed in 128 cases (90.1%). The most common abnormalities detected in the study were hydronephrosis, polycystic kidney disease, multicystic dysplastic kidney, and renal agenesis, in descending order of frequency. The study concluded urinary tract anomalies can be accurately diagnosed and classified in the antenatal period using ultrasonography imaging. Antenatal diagnosis is a helpful tool in planning immediate postnatal care and deciding the place for delivery. This might prevent or slow renal function deterioration and help in early identification of patients who need early surgical intervention.

### **Congenital Cystic Adenomatous Malformation**

In the present study 1 case of Congenital Cystic Adenomatous Malformation was noted which accounts for 1.5%. It contributed to 25% of Respiratory anomalies. Presence of multiple cystic

areas within the lung are better appreciated on fetal MRI compared to 3D/4D (3D/4D < MRI). Sensitivity & Specificity of 3D sonography was found to be very poor whereas that of fetal MRI was 100 %.Quinn TM, Hubbard AM, Adzick NS <sup>(4)</sup> studied 31 pregnant women with an ultrasound diagnosis of a fetal anomaly. the primary diagnosis by US had been congenital cystic adenomatoid malformation (CCAM). With lung masses, MRI accurately distinguished between CCAM and bronchopulmonary sequestration (BPS). Prenatal MRI enhances fetal anatomic evaluation and facilitates perinatal management and family counseling. Ultrafast imaging sequence MRI is helpful to corroborate and refine US diagnoses. Fetal MRI is a valuable adjunct to US for prenatal diagnosis before fetal surgical intervention for selected life-threatening birth defect.

### **Summary**

During the period of nineteen months of the study, 63 cases were evaluated with 2D ultrasound, 3D/4D ultrasound and MRI. Maximum incidence of anomalies was seen in the age group of 20-25years. In the present study 36 out of 63 (57%) cases were anomalies of central nervous system. Anencephaly is found to be the most common anomaly of central nervous system. 9 out of 9 cases (100%) were detected and confirmed by 3D/4D ultrasound and foetal MRI. Next most common anomalies of central nervous system were Holoprosencephaly and Dandy-Walker Malformation. 4 out of 63 cases (6.3%) were found to be holoprosencephaly of which two are semilobar holoprosencephaly and two are alobar holoprosencephaly. In the present study 3 out of 63 cases (4.7%) were found to be Multicystic Dysplastic Kidney. It accounts for 37.5% of genitourinary tract anomalies. In the present study 1 case of Congenital Cystic Adenomatous Malformation was noted which accounts for 1.5%. It contributed to 25% of Respiratory anomalies.



### Conclusions

3D is highly sensitive in detecting foetal anomalies and MRI can be used for confirmation in selected cases.

### References

1. Donald School Textbook of ultrasound in obstetrics and gynaecology; first edi; 2004.
2. Carol M Rumack, Diagnostic Ultrasound; volume 2; 4<sup>th</sup> edition, 2011.
3. Grainger & Allison's Diagnostic Radiology; A textbook of medical imaging; volume 2; 5<sup>th</sup> edition; pg 1212.
4. Quinn TM, HubbardAM, Adzick NS prenatal magnetic resonance imaging enhances fetal diagnosis JpediatrSurg 1998: april : 33 (4); 553-8
5. Bega G, Lev-Toaff A, Kuhlman K, Kurtz A, Goldberg B Wapner R. Three-dimensional ultrasonographic imaging in obstetrics: present and future applications. J Ultrasound Med 2001; 20:391–408
6. Nabeel S. Bondagji, Antenatal diagnosis, prevalence and outcome of congenital anomalies of the kidney and urinary tract in Saudi Arabia,Urol Ann. 2014 Jan;6 (1): 36-40.
7. Timor-Tritsch IE, Monteagudo A, Tsymbal T, Strok I. Three-dimensional inversion rendering: a new sonographic technique. J Ultrasound Med 2005; 24:681–688
8. Lee W, Goncalves LF, Espinoza J, Romero R. Inversion mode: a new volume tool for 3-dimensional sonography. J Ultrasound Med 2005; 24:201–207
9. Kang L, Chang CH, Yu CH, Cheng YC, Chang FM Prenatal depiction of cystic hygroma using three dimensional ultrasound. Ultrasound Med Biol. 2002 Jun;28(6):719-23.
10. Cohen-Overbeek TE, Grijseels E W, Niemeijer ND, Hop WC, Wladimiroff JW, Tibboel D. Isolated or non-isolated duodenal obstruction: perinatal outcome following prenatal or postnatal diagnosis. Ultrasound Obstet Gynecol. 2008 Nov;32(6):784-92.
11. Levine D, Barnes PD, Sher S, Semelka RC, Li W, McArdle CR, Worawattanakul S, Edelman RR. Fetal fast MR imaging: reproducibility, technical quality, and conspicuity of anatomy. Radiology 1998; 206: 549–554.
12. Catherine Limperopoulos, Richard L. Robertson, Jr.,Omar S. Khwaja, Caroline D. Robson, Judy A. Estroff, Carole Barnewolt, Deborah Levine, Donna Morash, Luanne Nemes, Linda Zaccagnini, and Adré J. du Plessis How Accurately Does Current Fetal Imaging Identify Posterior Fossa Anomalies? AJR -June 2008, Volume 190, Number 6
13. Manal Hamisaa, Naglaa Dabeesa, Walid M. Ataallab, Dina H. Ziadac (2013),(22) in their study on Magnetic resonance imaging versus Ultrasound examination in detection of prenatal fetal brain anomalies The Egyptian Journal of Radiology and Nuclear Medicine Volume 44, Issue 3, September 2013, Pages 665–672
14. Milan Stanojevic et al, Role of 2D and 3Dultrasound in evaluation of fetal gastrointestinal anomalies Donald School Journal of ultrasound in Obstetrics and Gynecology, Juty-September 2014; g(3): 316-320 317
15. Yuh WT, Nguyen HD, Fisher DJ, Tali ET, Gao F, Simonson TM, Kao SC, Weiner CP. MR of fetal central nervous system abnormalities. AJNR Am J Neuroradiol 1994; 15: 459–464.