



Clear Cell Carcinoma Detected During Caesarian Section Case Report

Authors

Dr Arati Nayak¹, Dr Arata Kumar Swain², Dr Rabinarayan Mallick³

¹Senior Specialist O&G, Infertility Specialist & Endoscopic Surgeon, Bhubaneswar

²Assistant Professor, Department of Anaesthesiology & Critical Care, VIMSAR, Burla

³Senior Consultant Pathologist, Immunohistopathology & Oncopathologist, Cuttack

Abstract

An elderly primi 35 weeks gestation leaking > 24 hours planned for caesarean section, with two previous normal ultrasound reports. Right salpingo-oophorectomy considered during caesarean section as right ovary was enlarged, vascular and friable and there was haemorrhagic ascites and growths over peritoneum and left ovary. Histopathology report was clear cell carcinoma (CCC) of ovary. Post operatively she received three courses of chemotherapy carboplatin and paclitaxol at 21 days interval. After chemo she had undergone TAH, LSO, infracolicomentectomy, pelvic lymphadenectomy. After that she received three courses chemotherapy. The patient 18 months after last chemotherapy is doing well.

Keywords: clear cell carcinoma (CCC), TAH (Total Abdominal Hysterectomy), LSO (Left Salpingo-oophorectomy).

Introduction

Ovarian neoplasms incidence in pregnancy is approximately 1 in 1000 to 1300 deliveries^(1,2) fortunately, only 2% to 5% of these cysts are malignant⁽³⁾. The advent of ultrasound use in early pregnancy for assessing fetal viability has resulted in increased detection of ovarian masses, which previously would not have been clinically apparent. The prenatal courses were usually uneventful, causing the occasional delayed diagnosis and the difficulty of early detection was emphasized^(4,5)

In the absence of large prospective randomized trials and cohort studies, recommended guidelines for management by an international consensus

meeting were based on available literature data and personal experience, thus representing a low level of evidence^(6,7)

Discussion

Ovarian cancer in pregnancy is extremely rare. Without ultra sonography or improper ultrasound ovarian cancer are usually detected during caesarean section or at an advanced stage during postpartum period.

These patients always present with non specific symptoms including abdominal or back pain, constipation, abdominal swelling and urinary symptoms which are normally presented by a pregnant lady⁽⁸⁾. There are currently no definitive

guidelines in the literature regarding the management of maternal ovarian cancer, with the exception of summaries of international consensus meeting⁽⁹⁾. Since the age of child bearing among women increases the incidence of cancer is also likely to rise in pregnancy. The age shift of child bearing women could cause the changing the histological distribution pattern.

The standard management of ovarian cancer involves staging laparotomy, debulking surgery and adjuvant chemotherapy. If ascites, solid growth present & other features of malignancy detected, ipsilateralsalpingo-oophorectomy should be considered. A frozen section biopsy taken if facilities available. If frozen section Confirms, malignancy, full surgical staging should be performed during caesarean section.

If distant metastasis present, adequate surgical staging is less important because chemotherapy is essential after surgery to control it. Caesarean hysterectomy is not essential for maximal cytoreductive surgery at the time of caesarean section. A second operation for cytoreductive surgery can be performed after chemotherapy. Prognosis of advanced stage ovarian cancer is poor even after chemotherapy and complete cytoreductive surgery.

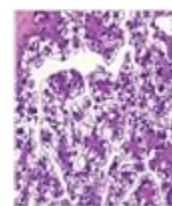
Case Report

An elderly primigravida, 38 years, admitted to labour room with leaking >24 hours at 35 weeks of gestation. She was planned for Caesarean section for non progress of labour and leaking. She had all routine investigation reports with two ultrasound reports, one at 18 weeks of gestation and another at 34 weeks of gestation, which were normal.

During caesarean section, there was two liters of haemorrhagic ascitic fluid present inside peritoneal cavity. Right ovary was enlarged 6x5cm, friable bleeds on touch, which was adherent to posterior wall of uterus, omentum & intestine. Left ovary was normal in size but friable. There was multiple growths over peritoneum, uterus. After consulting with her family members, right salpingo-oophorectomy

with biopsy from leftovary, peritoneum and, uterus taken after caesarean section.

The histology report showed clear cell carcinoma of ovary and biopsies from peritoneum & uterus was positive. Her baby was completely alright. On 7th post operative day she had MDCT scan of abdomen & pelvis. The report was multiple peritoneal deposits with peritoneal thickening with a cystic lesion of size 3x3 cm present in left ovary, rest all organs were normal. Her CA 125 value was 910.9 u/ml and CEA, CA19-9 were within normal range.



Histopathology of the tumor, Clear Cell Carcinoma(CCC) Histopathology.

Chemotherapy carboplatin & paclitaxol started on 10th post operative day. three courses of chemotherapy given at an interval of 3 weeks. Then she had undergone TAH, LSO with infracolicomentectomy with pelvic lymphadenectomy. Post operatively again chemotherapy was started after 21 days for three courses. Currently the mother 18 months after last chemotherapy & her baby are doing well.

Conclusion

Clear cell carcinoma of ovary (CCCO) during pregnancy is extremely rare and having poor prognosis as it is more chemo resistant & the mechanism of tumor development, progression and drug resistance remain largely unknown. Ultrasound screening can detect an abnormal adnexal mass during pregnancy (but unfortunately in this case the two ultrasound reports were normal) Thus early diagnosis and management of ovarian cancer can prevent complications of ovarian cancer in advanced stages.

Reference

1. Tawa K : ovarian tumors in pregnancies
Am j obstetGynecol 64:511, 1964
2. Hess LW, Peaceman A, O Bried WF et al :
Adnexal mass occurring with intrauterine
pregnancy : Am JobstetGynecol 158:1029-
1034, 1988.
3. Jubbed : Primary Ovarian Carcimoma in
pregnancy Am J obstetGynecol 85:345,
1963.
4. Jubbed : primary carcinoma in pregnancy.
Am J obstetGynecol 1963; 85: 345-354
5. Dougherty CM, Lund CJ Solid ovarian
tumors complicating pregnancy ; a clinical
pathological studes. Am J obstetgynecol
1950 ; 60:261-272 (Pubmed)
6. Marrent H LhommeC Lecuru F et al
Guidelines for the management of ovarian
cancer drugs pregnancy (Pubmed)
7. Amount F, Van calsteren K, Halaska MJ,
etal Gynecologic Cancers in pregnancy :
Guidelines at an international consensus
meetings Int J Gynecol Cancer 2009;19
(Suppl 1) S1 – S2 (PUB med)
8. GoffBA Mandel LS, Drescher CW, Urban
N GoughsSuchurman Km et al. 2007 Jan
15, 109 (2)
9. Marret H Lhomme C, Lecuru F, ut al 221-
7 Guidelines for the management of
ovarian cancer during pregnancy EUR
jobstet Gynecol Reprod Biol. 2010 ; 149
:18-21 (Pub Med)