



Case of Brugada Syndrome

Authors

**Dr Rajat Shankarrao Dalal¹, Dr Anil Modak², Dr Tanuja Manohar³,
Dr Nalini Humaney⁴**

¹Medicine Resident, ^{2,3}Associate Professor, ⁴Profesor and HOD

Abstract

In 1992 Brugada et al. described clinical entity associated with ST segment elevation in precordial leads (V1 to V3) with incomplete or complete Right Bundle Branch Block and susceptibility to ventricular tachyarrhythmia and sudden cardiac death has been described. The disease is now know as “Brugada syndrome” (BrS). The prevalence of Brugada syndrome is unknown as mostly is goes undiagnosed. Common presentation of Brugada syndrome is syncope typically occuring at rest or during sleep (mostly seen in third or fourth decade of life). Brugada syndrome can be life threatening in some cases as tachycardia does not terminate and it may degenerate into ventricular fibrillation and leads to sudden cardiac death. Brugada syndrome is an autosomal dominant pattern of inheritance. In approximately 20% of the cases BrS is caused by mutations in the SCN5A gene on chromosome 3p21-23, encoding the cardiac sodium channel. SCN5A is a protein involved in the control of myocardial excitability. Sodium channels are heat sensitive so fever can also unmask Brugada syndrome. The use of the implantable cardioverter defibrillator (ICD) is the only therapeutic option of proven efficacy for primary and secondary prophylaxis of cardiac arrest.

39 yrs old male came with complaint of Fever with chills since last 4 days increased since day of admission associated with generalised weakness and bodyache, nausea and headache.

No complaint of vomiting, loose stools, pain in abdomen

No complaint chest pain, breathlessness

ON EXAMINATION

He was Febrile (100⁰ Celsius), Pulse – 86/min

REG, Respiratory Rate – 16/min, BP- 120/80 mm

of Hg, No cynosis, no clubbing, no lymphadenopathy.

SYSTEMIC EXAMINATION

CVS – S1 S2 Normal, No murmur

P/A – Soft, Nontender, No organomegaly

RS – Clear, air entry present bilaterally upto bases

CNS – Conscious, Oriented, No Focal Neurological Deficit

Past History

No significant past history.
 No history of sudden cardiac death in family

LAB REPORTS

CBC - Hb - 12.5, TLC -5200, Platelet count - 1.09
 KFT - Urea - 30.4 Creat - 1.1 Na+ - 139 K + - 3.7
 LFT - Total Sr. Bilirubin - 0.9 SGOT - 29 SGPT - 27 Alkaline Phosphatase - 135 Sr. albumin - 4.7
 Urine Routine and Microscopy - Nil
 RBS - 135 mg/dl
 CXR PA - Normal
 Dengue - IgM - Positive
 HRP II - Negative

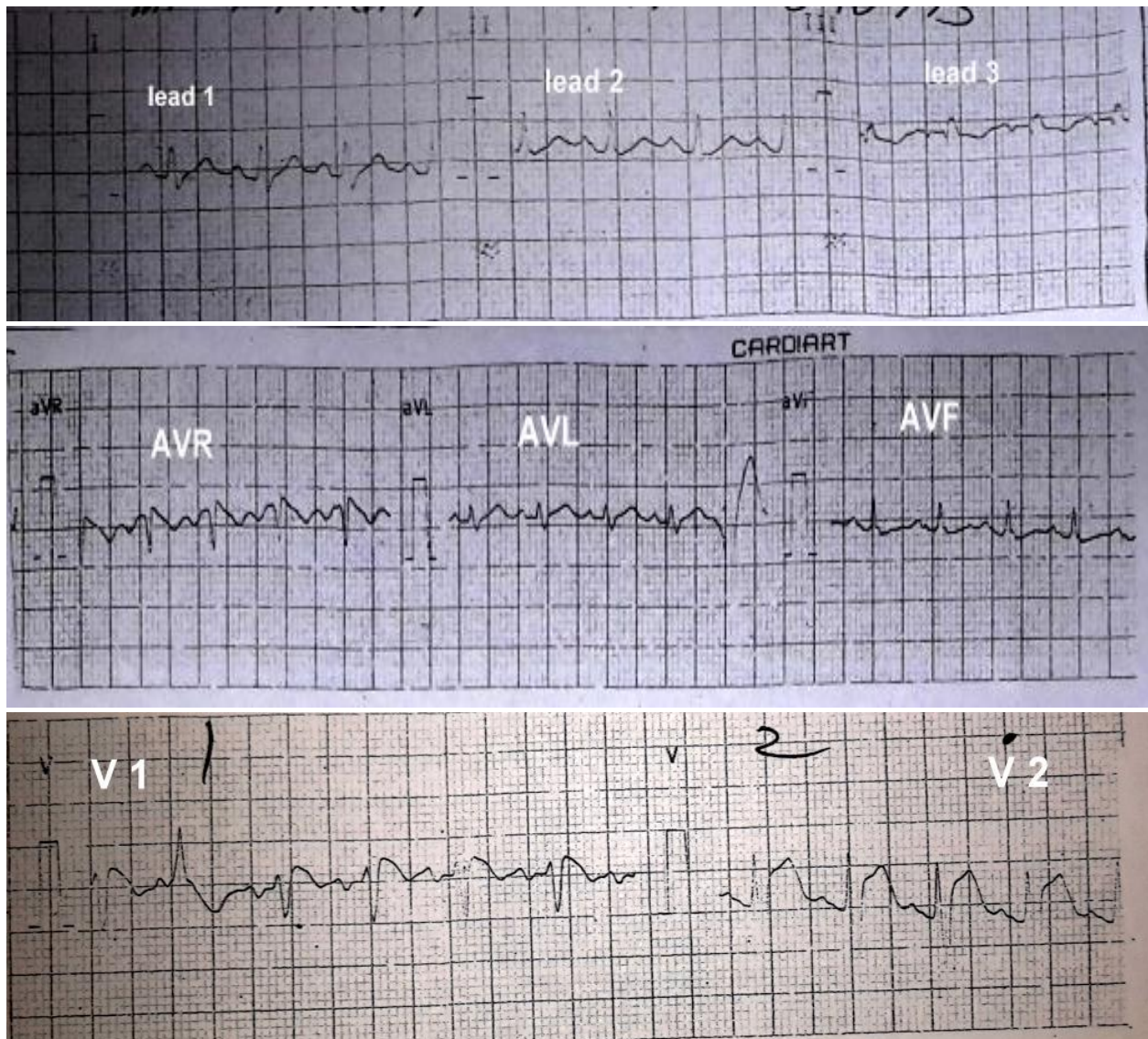
Widal - Negative

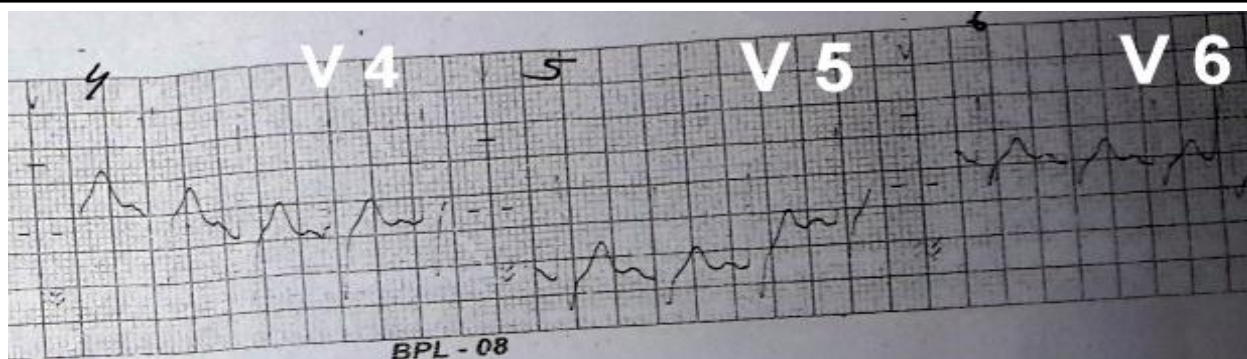
USG Abdomen - Suggestive of Hepatosplenomegaly

ECG was done at the time of hospitalization, when he was febrile was suggestive of type I Brugada pattern, i.e. Incomplete RBBB with J point elevation in precordial leads. ECG also revealed ventricular ectopics.

As ECG was showing ST-T changes so CKMB was done which was 19.8.

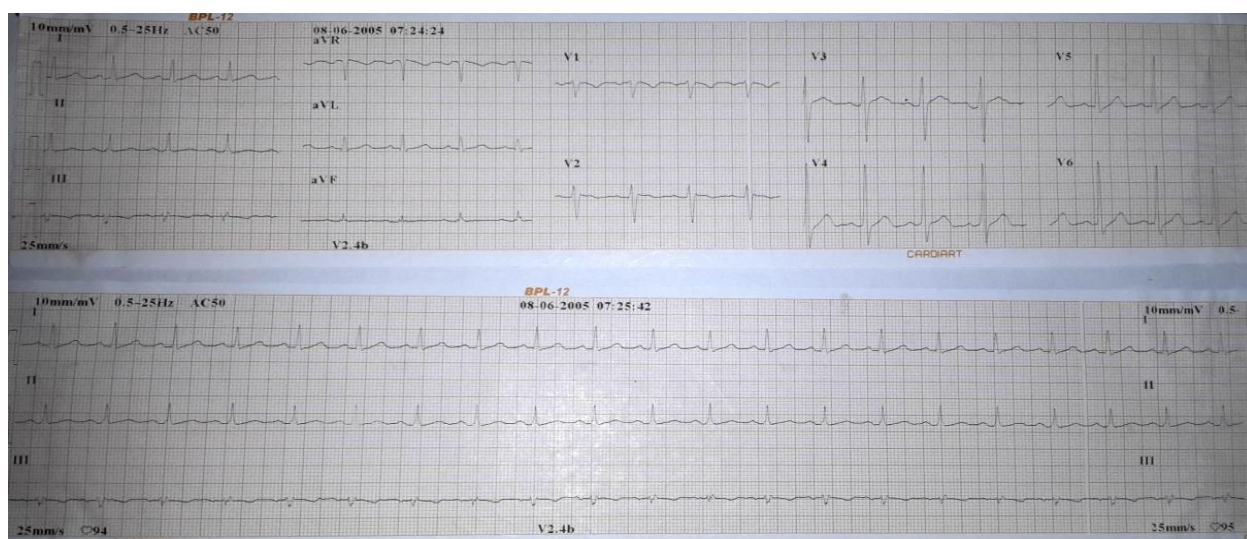
So 2D Echo was done suggestive of RV apex and small segment of free wall of RV, near apex was dilated and dyskinetic. 2D Echo was suggestive of left persistent left SVC communicating with coronary sinus.





Patients multiple ecgs were taken when he was afebrile, in those ecgs Brugada syndrome was not seen. His subsequent Echo was also normal.

So in this case, fever has unmasked BrS; as it is channelopathy and Sodium channels are heat sensitive.



Treatment given

Symptomatic treatment given to the patient with adequate hydration.

Patient was asymptomatic for Brugada syndrome so no specific treatment was advised.

Review of Literature

In 1992 Brugada et al. described clinical entity associated with ST segment elevation in precordial leads (V1 to V3) with incomplete or complete Right Bundle Branch Block and susceptibility to ventricular tachyarrhythmia and sudden cardiac death has been described.

The disease is now known as “Brugada syndrome” (BrS) or “Idiopathic ventricular fibrillation”.^[1]

In 1998 Brugada *et al.* presented data on 63 patients in whom, after a mean follow up of 32 ± 34 months, 34% of previously symptomatic

(syncope and/or cardiac arrest) patients had recurrence, while a first cardiac event occurred in 27% of the asymptomatic individuals. It led to implantation of implantable cardioverter defibrillator (ICD) in several young asymptomatic individual.

However, a different picture is emerging from more recent epidemiological surveys. In 2000, Priori *et al.* showed an incidence of 16% for the recurrence of a cardiac arrest in symptomatic patients, while none of the asymptomatic individuals at enrolment had a cardiac event after three years of follow up and were left untreated.^[2]

Genetic bases and Pathophysiology

Brugada syndrome is arrhythmogenic state which is inherited. It is a type of channelopathy.

In 1998 CHEN identified that mutation in cardiac sodium channel gene, SCN5A, on chromosome

3p21-23 is associated with Brugada syndrome.^[4]
BrS is not the only phenotype linked to mutations in this gene.

Other Known allelic disorders are Sick sinus syndrome & LQT3 variant of Long QT syndrome, the progressive cardiac conduction defect. In vitro expression of mutant SCN5A proteins showed that BrS is characterized by a loss of sodium channel function, whereas in LQT3 there is an excess of sodium inward current.^[5,6,7]

Overlapping syndromes have been also described in association with some specific SCN5A mutations that may cause the coexistence of LQT3 and BrS in the same individuals.^[8,9,10]

Unfortunately, SCN5A mutations account for approximately 20% of BrS cases.

Clinical manifestations

Patients generally presents with syncope or sudden cardiac arrest

Most of the patients are asymptomatic and are diagnosed on routine examination.

Diagnosis of Brugada Syndrome

Diagnosis of Brugada syndrome is based on ECG findings.

There are 3 types of BrS^[3]

Type 1 – Coved ST segment elevation >2mm in V1 – V3 followed by negative T wave.

Type 2 – ST segment elevation >2mm with saddle back shape

Type 3 – Either morphology of Type 1 or 2 with <2 mm ST segment elevation.

Management and Risk stratification

Brugada syndrome patients are at life – long risk of sudden cardiac death but for very long intervals (years) complete well-being is there between two cardiac events.

Therefore implanting ICD in asymptomatic patients is not advised as it is associated with remarkably impaired quality of life. But identification of subgroup of individuals is must in whom this aggressive therapeutic approach is mandatory.

Most BrS patients are either asymptomatic or are referred with one or few syncopal spells in their clinical history, risk stratification with careful evaluation of the clinical presentation is mandatory in these cases.

Patients with a history of syncope plus a spontaneously abnormal ECG (*i.e.* independent of the provocative test with intravenous sodium channel blockers) have an approximately 6-fold higher risk of cardiac events

History of syncope alone was not an independent predictor of outcome.

These patients, as well as the silent gene carriers, belong to a low risk group.

Pharmacological therapies like use of quinidine are of doubtful use hence not advised

Patients who have already experienced a cardiac arrest should receive an ICD according to treatment guidelines for Brugada syndrome.^[11]

Differential Diagnosis –

Arrhythmogenic Right Ventricular Dysplasia / Cardiomyopathy,

Prinzmetal's Variant Angina,

Acute Pericarditis / Myocarditis,

Hypocalcaemia/Vitamin D Intoxication,

Acute Pulmonary Thromboembolism,

Transthoracic Cardioversion

Before diagnosing the patient as a case of Brs drug related causes must be excluded

Tricyclic antidepressants

Opioid analgesics: propoxyphene

Lithium

First-generation antihistamines: dimenhydrinate

Propofol

Beta-blockers propranolol

Potassium channel activators: pinacidil

Parasympathetic agonists: acetylcholine

Ergot alkaloids: ergonovine

Local anesthetics (non antiarrhythmic): bupivacaine

Cocaine

Alpha adrenergic agonists: methoxamine, noradrenaline

Conclusion

Brugada syndrome is an inherited arrhythmia syndrome associated with sudden cardiac death. Manifestations mostly occur around the age of 40, sudden cardiac nocturnal deaths are common.

Fever can unmask Brugada syndrome. Asymptomatic patients are not to be treated but patient once experienced cardiac arrest must be treated with Implantable Cardiac Defibrillator (ICD).

References

1. Priori SG: Foretelling the future in Brugada syndrome: do we have the crystal ball? *J Cardiovasc Electrophysiol* 2001, 12:1008–1009
2. Priori SG, Napolitano C, Gasparini M, Pappone C, Della BP, Brignole M, Giordano U, Giovannini T, Menozzi C, Bloise R, Crotti L, Terreni L, Schwartz PJ: Clinical and genetic heterogeneity of right bundle branch block and ST-segment elevation syndrome: A prospective evaluation of 52 families. *Circulation* 2000, 102:2509–2515
3. Antzelevitch C, Brugada P, Borggreffe M, Brugada J, Brugada R, Corrado D, Gussak I, LeMarec H, Nademanee K, Perez Riera AR, Shimizu W, Schulze-Bahr E, Tan H, Wilde A: Brugada syndrome: report of the second consensus conference. *Circulation* 2005, 111:659–670.
4. Chen Q, Kirsch GE, Zhang D, Brugada R, Brugada J, Brugada P, Potenza D, Moya A, Borggreffe M, Breithardt G, Ortiz-Lopez R, Wang Z, Antzelevitch C, O'Brien RE, Schulze-Bahr E, Keating MT, Towbin JA, Wang Q: Genetic basis and molecular mechanism for idiopathic ventricular fibrillation. *Nature* 1998, 392: 293–296.
5. Wang Q, Shen J, Splawski I, Atkinson D, Li Z, Robinson JL, Moss AJ, Towbin JA, Keating MT: SCN5A mutations associated with an inherited cardiac arrhythmia, long QT syndrome. *Cell* 1995, 80:805–811.
6. Kyndt F, Probst V, Potet F, Demolombe S, Chevallier JC, Baro I, Moisan JP, Boisseau P, Schott JJ, Escande D, Le Marec H: Novel SCN5A mutation leading either to isolated cardiac conduction defect or Brugada syndrome in a large French family. *Circulation* 2001, 104:3081–3086
7. Schott JJ, Alshinawi C, Kyndt F, Probst V, Hoorntje TM, Hulsbeek M, Wilde AA, Escande D, Mannens MM, Le Marec H: Cardiac conduction defects associate with mutations in SCN5A. *Nat Genet* 1999, 23:20–21.
8. Rivolta I, Abriel H, Tateyama M, Liu H, Memmi M, Vardas P, Napolitano C, Priori SG, Kass RS: Inherited brugada and LQT-3 syndrome mutations of a single residue of the cardiac sodium channel confer distinct channel and clinical phenotypes. *J Biol Chem* 2001, 276:30623–30630.
9. Priori SG, Napolitano C, Schwartz PJ, Bloise R, Crotti L, Ronchetti E: The elusive link between LQT3 and brugada syndrome: the role of flecainide challenge. *Circulation* 2000, 102:945–947.
10. Bezzina C, Veldkamp MW, van Den Berg MP, Postma AV, Rook MB, Viersma JW, van Langen IM, Tan-Sindhunata G, Bink-Boelkens MT, Der Hout AH, Mannens MM, Wilde AA: A single Na(+) channel mutation causing both long-QT and Brugada syndromes. *Circ Res* 1999, 85: 1206–1213.
11. Priori SG, Aliot E, Blomstrom-Lundqvist C, Bossaert L, Breithardt G, Brugada P, Camm JA, Cappato R, Cobbe SM, Di Mario C, Maron BJ, McKenna WJ, Pedersen AK, Ravens U, Schwartz PJ, Trusz-Gluza M, Vardas P, Wellens HJ, Zipes DP: Update of the guidelines on sudden cardiac death of the European Society of Cardiology. *Eur Heart J* 2003, 24:13–15