

Original Article

MRCP and Its Role in the Evaluation of Pancreaticobiliary Tract in Gall Stone Disease at a Tertiary Care Centre in North India

Authors

S N Singh¹, Abhishek Dwivedi², P K Dhagat³, Sumeet Arora⁴, Rajat Sharma⁵,
Shalini Singh⁶, Megha Jain⁷, Abhishek Purkayastha⁸

^{1,2,3,4,5,6,7}Department of Radiodiagnosis, Base Hospital Delhi Cantt, New Delhi, India

⁸Department of Radiation Oncology, Army Hospital (Research and Referral), New Delhi, India

Corresponding Author

Dr Abhishek Dwivedi, MD (Radiodiagnosis)

Department of Radiodiagnosis

Base Hospital and Army College of Medical Sciences, Delhi Cantt-110010, Delhi, India

Mobile: 8826384442, Email: abhishek232464@yahoo.com

Abstract

MRCP (Magnetic Resonance Cholangio Pancreatography) is a widely used investigation and is now firmly established in the evaluation of the biliary and pancreatic ducts. It helps in the assessment of causes of biliary abnormalities and can be useful in the evaluation of the pancreatic duct without the invasiveness of an endoscopic procedure.

In view of limitation of US and CT and invasiveness of PTC and ERCP there is continuous need for a non invasive high resolution modality.

Aim: The aim of this study was to assess the accuracy of MRCP with its ultrasound correlation.

Methods: This study included 50 patients who had undergone MRCP prior to cholecystectomy for symptomatic gallstones. There were 23 males and 27 female patients

Result: The majority of patient presented with epigastric pain & vomiting. The percentage rate of detection of gall stones and CBD stones were 89.75% and 76.19% on USG respectively. The same for MRCP was 87.18% and 95.24% respectively. MRCP showed high positive predictive value in diagnosing choledocholithiasis and diagnosing hepatobiliary lesions.

Conclusion: MRCP now readily, easily and accurately permits the study and evaluation of anatomy and pathology of the pancreaticobiliary tree. It is non invasive and non ionizing imaging method. Our results states that preoperative MRCP had a concrete safeguarding effect on laparoscopic cholecystectomy and deserves promotion.

Keywords: biliary obstruction, Ultrasound, intraductal calculi.

Introduction

Evaluation of suspected biliary obstruction has traditionally involved a variety of imaging modalities including ultrasonography (US),

computed tomography (CT) and invasive cholangiography. These techniques have limitations because of poor visualization of intraductal calculi on ultrasound and CT studies

alongwith the need for invasive procedures like ERCP and PTC. MRCP is a non-invasive imaging modality that provides good visualization of the biliary system ^[1,2]

Ultrasound followed by CT scan are the screening tool that is useful in evaluating patients presenting with pancreatic biliary diseases. ^[3]

Ultrasonography has limitations especially in the evaluation of the distal CBD where bowel gas, debris, fluid in the duodenum and obesity can degrade the image quality. CT scan has its share of limitations, especially in demonstrating two important pathologies, biliary stones and biliary strictures. For detecting biliary stones CT has a sensitivity of about 90% ^[3,4].

Calculi which have high cholesterol & mixed stones may be difficult to detect on CT. Biliary strictures are not directly visualized on CT. The length and extent of the stricture is difficult to determine on CT. It is very important from a management point of view to be able to visualize the length and extent of strictures. For these reasons cholangiographic modalities, intravenous cholangiography (IVC), percutaneous transhepatic cholangiography (PTC) and ERCP are required. IV cholangiography has limitations, in 30-40% of cases there is incomplete opacification of the biliary system ^[5,6].

PTC and ERCP has the same diagnostic and therapeutic role as ERCP but PTC is more invasive and risky with incidence of sepsis as high as 4 % ^[7].

In view of limitation of US and CT and invasiveness of PTC, IVC and ERCP there is need for an imaging modality which is non invasive and provides high resolution projection images of the biliary and pancreatic duct ^[7,8].

With the development of higher magnetic field strength and newer pulse sequences, MRCP with its inherent high contrast resolution, rapidity, multiplanar capability and virtually artifact free display of anatomy and pathology in this region is proving to be examination of choice in patients with pancreatico biliary diseases ^[8].

This imaging technique is able to create projectile type images similar in detail an appearance to direct cholangiography. It avoids the use of IV contrast and ionizing radiation and is relatively operator independent. Several recent studies have demonstrated that MRCP is able to accurately identify common bile duct stones with sensitivity of 81-100 %. Biliary strictures can also be visualized with sufficient anatomic detail to determine the level of obstruction and in some instances, differentiate benign from malignant causes ^[7]. In addition, MRCP lacks the major complication rate of approximately 3% associated with ERCP such as sepsis, bleeding, bile leak and death. MRCP demonstrates more than just the biliary and pancreatic ducts. Its disadvantages include lack of visualization of the peripheral intrahepatic ducts and inability to provide endobiliary therapy ^[7,8].

Material and Methods

This was a prospective study conducted at a tertiary care hospital over a period of three years in 2013-16. This study included 50 patients who had undergone MRCP prior to surgery for symptomatic gallstones. Patients were selected on the basis of clinical history & laboratory criteria suggestive of having cholelithiasis or choledocholithiasis and evidence of cholelithiasis or choledocholithiasis on ultrasound.

Exclusion criteria; Excluded patients who were not willing for surgery/other interventional procedures like ERCP and patient who refused consent for post surgical follow up.

Patient Preparation: Patient was instructed to be on a fat free diet for 24 hrs with overnight fasting. Negative oral contrast were used in the study.

Technique:

Sonography was performed a GE-Logic P5 USG machine. Original sonographic reports regarding the presence of gall stones/dilatation of the CBD (>8 mm in diameter) were used to calculate the accuracy of the sonographic examination.

The patients were orally administered 1ml of gadolinium mixed in 250 ml of pine apple juice. This worked as a negative contrast for stomach and duodenum. MRCP was performed in all patients after one hour with a 1.5-T system (Horizon; GE Medical Systems) by using a phased-array multicoil. Initially, localizer images were obtained in the coronal and transverse planes by using a spoiled gradient-recalled sequence. Subsequently, thin-section T2-weighted images were obtained by using a single-shot half-Fourier rapid-acquisition and relaxation sequence (RARE-single-shot fast spin-echo) with a 260–340-mm field of view. In addition, HASTE^[9] & PACE sequences were studied. All of the above sequences are included among the routine sequences of MR cholangiographic examination at our institution.

Results

In the study, the number of patients with symptoms of gall stones were predominantly female. The predominant population adults ranging from 30 to 50 yrs of age. Majority of patient presented with epigastric pain & vomiting. In my study, 39 cases had intraluminal gall bladder calculi & 21 cases had choledocholithiasis.. Out of these 21 cases, 16 cases had associated gall bladder stone. Most common lesion was cholelithiasis (n=39) followed by choledocholithiasis (n=21). A representative case of Cholelithiasis with Choledocholithiasis (Fig 01).

Transabdominal sonography is currently advocated for the initial evaluation of patients with symptoms consistent with choledocholithiasis. Currently Computed Tomography (CT) scanning is not the investigation of choice in evaluation of pancreaticobiliary tract and is recommended only for the evaluation of abdominal pain, if the diagnosis is uncertain. With these modalities the sensitivity for CBD stone diagnosis does is low whereas specificity is higher than 90 %^[10,11].

Direct cholangiography is generally still considered to be the ideal method for CBD stone diagnosis. This has an added advantage of concurrent endoscopic sphincterotomy especially in a dilated CBD although ERCP may miss small stones. In one study with 28 consecutive cases of suspected CBD stones, the diagnosis was corroborated after surgical exploration in all cases. The study showed that 8.5% of the patients were false positive & underwent surgical exploration unnecessarily^[12,13]. Thus the risk of surgical exploration related complications in patients with suspected CBD stones who ultimately are found to have no stones indicates the need for careful patient selection. A representative case of distal CBD stricture as sequelae of multiple ERCP is shown as case 02. With the development of newer fast spin echo sequences without breath holding, significant improvement in image quality has been achieved. These imaging sequences provide excellent high T2 contrast with sharper delineation of the pancreaticobiliary tree anatomy^[14,15].

To improve the diagnostic accuracy for choledocholithiasis and stenosis (71 to 100), two dimensional maximum intensity projection image respiratory triggered TSE sequence technique (2D PACE) was performed in our study to avoid respiratory artifacts.

^[15]. In our study, MRCP delineated normal and dilated CBDs in 27 patients (96%) [Table 1].

With the development of higher magnetic field strength and newer pulse sequences, MRCP with its inherent high contrast resolution, rapidity, multiplanar capability and virtually artifact free display of anatomy and pathology in this region is proving to be examination of choice in patients with pancreatico biliary diseases [Fig 1]. Few reports have specifically addressed the use of MRCP for diagnosing gallstone disease in children^[16].

In this study of 50 patients with suspicion of gall stones & CBD stones, 28 (70%) actually had biliary stone disease, and 20 of these were diagnosed by MRCP. The study showed a 100% specificity but a much lower sensitivity for

choledocholithiasis (56%). This may be because patients with small CBD stones were missed by MRCP (≤ 6 mm). Patients in the study were fasting before MRCP but did not receive any antiperistaltic agent, thus motion artifacts may have occurred during the acquisition time (almost two minutes); furthermore, small stones may be slowly stirred up in the CBD during the acquisition period. In addition, limitations of detection of small stones in maximum intensity projection images (MIP) are discussed subsequently in discussion.

In 21 cases of choledocholithiasis, diagnostic accuracy of ultrasound was 76%. The distal CBD was difficult to visualize on ultrasound. MRI

detected 26 cases of with a diagnostic accuracy of 95.5% (Fig 2 & 4).

Sensitivity and specificity of ultrasound and MRI were 73% and 89% and 97% and 98 % (Fig 3). These data are comparable with that of Varghese et al 91% sensitivity, specificity 98% and diagnostic accuracy of 97% (MRCP) [17]. In a similar study by Ke ZW et al (2003), evaluation the predictive value of MRCP in 267 patients before laparoscopic cholecystectomy (LC). In this study, MRCP had a sensitivity of 100%, a specificity of 96.3%, a positive predictive value of 91.8%, and a negative predictive value of 100% for the detection of common bile duct stones [18].

Fig 1. A 33 years old male presented with features of obstructive jaundice since three months.

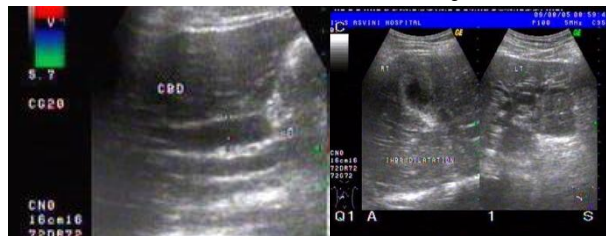

Fig 1(a)

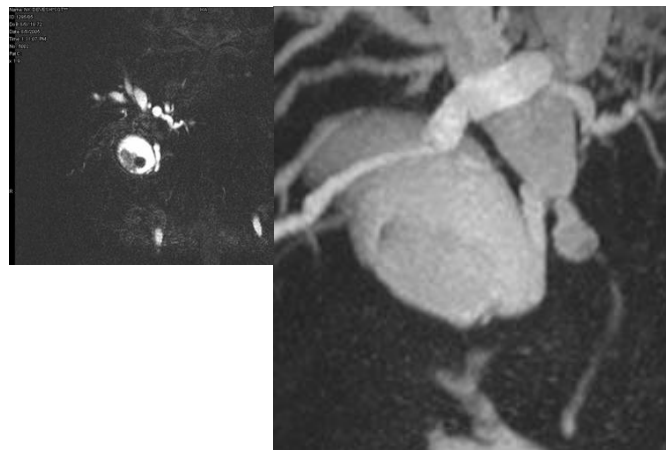


Fig 1(b)

Fig 1(a)-UGS showed gross distention of gall bladder & cystic duct with edematous & thickened wall with a 11 mm calculus within (not shown). Moderate IHBR dilatation & dilated both hepatic duct & CBD (10 mm). Distal third of CBD was not well visualized. No calculi or mass lesion within CBD was demonstrated.

Fig 1(b)-MRI confirmed findings of USG. Moderate IHBR dilatation & dilated both hepatic duct & CBD (10 mm). Abrupt narrowing of CBD seen in the mid third. A 13 mm calculus was seen in the CBD distal to the narrowed segment. The strictured segment was Cholangiocarcinoma on HPA. Final Diagnosis – Cholangiocarcinoma with distal choledocholithiasis.

Fig 2. A 60 yrs male was referred with features of gastric outlet obstruction & obstructive jaundice. The patient underwent repeated ERCP (three times) in the past for the treatment of stricture.

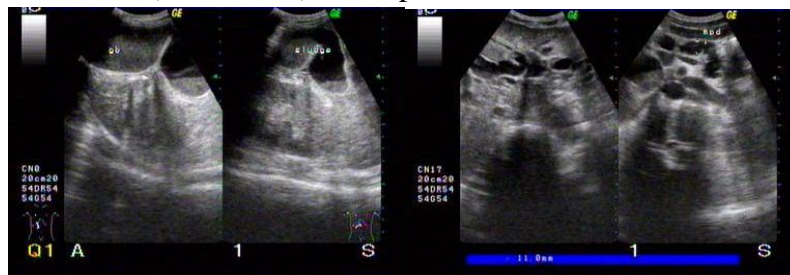

Fig 2 (a)

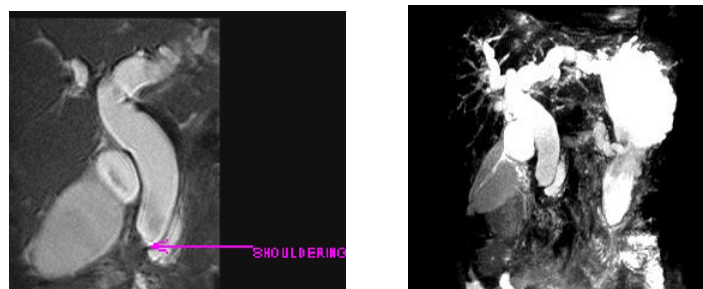


Fig 2(b)

Fig 2(a) - USG shows gross distention of the gall bladder & cystic duct (With intraluminal sludge), moderate to severe IHBR dilatation & abrupt termination of distal CBD (24 mm) with shouldering at the level of the ampulla.

Fig 2(b) - MRCP confirmed the findings of USG. The abrupt termination of distal CBD is caused by

complete narrowing in the ampullary region causing proximal obstructive effects in the form of dilated CBD, EHBR & IHBR. Duodenum is compressed by the distended gall bladder & dilated CBD causing gastric outlet obstruction. MPD is dilated. Final Diagnosis: Distal CBD stricture following repeated ERCP.

Table 1- Comparison of dilated CBD (n=28) diagnosis by Magnetic Resonance Cholangiopancreatography (MRCP) and reference methods.

	USG	MRCP
<i>Stones detected</i>	16(76%)	20(95.5%)
<i>No stones</i>	5(24%)	1(4.5%)
Total	21	21

Table 2- Choledocholithiasis diagnosis in relation to stone size

	No of cases observed by reference method.	No of cases observed by MRCP.
≤6 mm	5(31%)	7(35%)
>6 and ≤10 mm	7(43%)	9(45%)
>10 mm	4(25%)	4(20%)
Total	16	20

Table 3- Choledocholithiasis diagnosis at MRCP correlated with common bile duct (CBD) caliber

	Dilated CBD (reference method)	Undilated CBD (reference method)	Total
Total	28	22	50
No stones (reference method)/no stones (MRC)-stones missed	5/1	2/1	2/5

	USG	MRCP	TOTAL CASES	Diagnostic Accuracy on USG	Diagnostic Accuracy on MRCP
Cholelithiasis	35	34	39	86	84
Choledocholithiasis	16	20	21	76	95
<u>OTHER LESIONS</u>					
Cholangiocarcinoma	2	3	3*	66	100
Pancreatitis	4	6	8	50	75
Periampullary Carcinoma	0	1	1*	-	100
Carcinoma Pancreas	2	3	4*	50	75
Post operative Stricture	-	2	2*	-	100
Choledochal Cyst		1	1*	-	100
Postoperative fistula	-	1	1*	-	100
Gall bladder mass	1	1	1	100	100

* -Statistically Not Significant

Table 1 - The clinical role of MRCP in detection of dilated CBDs is higher as compared to the reference method (USG).

Table 2 & 3 - MRCP has better diagnostic accuracy in detecting biliary calculi in cases of dilated and normal undilated CBD.

Discussion

Abdominal USG is the technique of choice for initial examination of the bile ducts, particularly in patients with jaundice.

MRCP is a noninvasive and non-operator-dependent technique that has a cost effective and important role in the evaluation of pancreaticobiliary diseases [19,20]. MRCP has higher diagnostic accuracy in demonstration of bile duct obstructions (Table 1 & 2), choledocholithiasis, strictures and malignant obstructions (Table 2 & 3). In our study, the Half-Fourier RARE MRCP produces high-quality images for delineation of the biliary and pancreatic ducts. The application of multiple echo trains and half-Fourier imaging reconstruction algorithms, half-Fourier RARE MRCP generates "fluid-sensitive" images with negligible motion and susceptibility artifacts.

For the evaluation of postoperative complications, MRCP had high sensitivity for the depiction of strictures of anastomotic sites. Source images were better for evaluation of the morphology and length of the strictures. In our study, an anastomotic stricture was depicted with dilatation

of the distal bile ducts and sudden abrupt termination at the anastomotic site.

Stones are easily recognized on MRCP images as low-signal-intensity structures surrounded by high-signal-intensity bile. The smallest stone detected was 4 mm in diameter. In our experience, small stones may have been obscured in maximum intensity projection images (MIP) as stones were likely obscured by the high signal intensity of the surrounding bile. The evaluation of basic source images was required to confirm the presence of calculi. In conclusion, half-Fourier RARE MRCP exhibited excellent test performance and resulted in excellent inter-observer agreement for the evaluation of changes in patients' anatomy after pancreaticobiliary ductal system surgery. This imaging method is fast, safe, and noninvasive and can be used to follow up patients, screen symptomatic patients for treatment, and help guide further therapeutic procedures [21].

The use of respiratory-triggered T2-weighted 2D PACE FSE MRCP sequence with parallel imaging, allowed high spatial resolution and relatively short acquisition times. This study has

excellent sensitivity and specificity for possible biliary disease, specifically strictures, dilatation, and stones larger than 3 mm, but is limited for stones 3 mm or smaller.

Conclusion

The study shows that at tertiary hospital with standard equipment MRCP has more diagnostic accuracy in detecting biliary calculi in cases of dilated and normal undiluted CBD. The clinical role of MRCP in detection of dilated CBDs was also high as compared to the ultrasound. We strongly recommend that MRCP be incorporated as a standard investigation in patient with intrabiliary gall stones for intervention and surgical planning.

Source(s) of support: Nil

Presentation at a meeting: Nil

Conflicting Interest: Nil

References

- Magnuson TH, Bender JS, Duncan MD. Utility of MR Cholangiopancreatography in the evaluation of biliary obstruction. *J Am Coll Surg* 1999; 189: 63-72.
- Reinhold C, Taorel P, Bret P et al. Choledocholithiasis: Evaluation of MR Cholangiopancreatography for diagnosis. *Radiology* 1998; 209:435-442.
- Baron RL. Common Bile Duct Stones: Reassessment criteria for CT Diagnosis. *Radiology* 1987; 162:419-424.
- Baron RL. Computed Tomography of the biliary tree. *RCNA* 1991; 29(6): 1235-1250.
- Dawson P, Adam A, Benjamin IS. Intravenous Cholangiography revisited. *Clinical Radiology* 1993; 47:223-225.
- Patel JC, Mc Cinnis, Bagely GS et al. The role of Intravenous cholangiography in pre operative assessment for laproscopic cholecystectomy. *Br J Radiology* 1993; 66:1125-1127.
- Wallener BK, Schumacher KA, Weidenmaier W, et al. Dilated Biliary tract: Evaluation with MR Cholangiography with a T2 weighted contrast enhanced fast sequence. *Radiology* 1991; 181:805-808.
- David et al: Pitfalls in the interpretation of MR Cholangiopancreatography. *AJR* 1998; 170:1055-59.
- Miyazaki T, Yamashita Y, Tsuchigame T, et al. MR cholangiopancreatography using HASTE (half-fourier acquisition single-shot turbo spin-echo) sequences. *AJR Am J Roentgenol* 1996;166:1297-1303.
- Laubenberger et al. Breathhold projection MRCP: A new method for examination of the bile and pancreatic ducts. *Magn Reson Med* 1995; 33:1823.
- David et al: Pitfalls in the interpretation of MR Cholangiopancreatography. *AJR* 1998; 170:1055-59.
- Prat F, Bou Jaoude J, Ink O, et al. Endoscopic sphincterotomy for suspected choledocholithiasis in patients with and without stones. *Am J Gastroenterol* 1995;90:727-731.
- Lightdale CJ. Indications, contraindications and complications of endoscopic ultrasonography. *Gastrointest Endosc* 1996;43:S15-S18.
- Outwater E, Miller L, Gordon S, et al. Non invasive 3-d cholangiography with MR imaging. [Abstract] *Gastroenterology* 1994;106:A374 .
- Guibaud L, Bret PM, Reinhold C, et al. Bile duct obstruction and choledocholithiasis: diagnosis with MR cholangiography. *Radiology* 1995;197: 109-115.
- Fitoz S1, Erden A, Boruban S. Magnetic resonance cholangiopancreatography of biliary system abnormalities in children. *Clin Imaging.* 2007 Mar-Apr;31(2):93-101.
- Varghese JC, Liddell RP, Farrell MA, Murray FE, Osborne DH, Lee MJ. Diagnostic accuracy of magnetic resonance cholangiopancreatography and

- ultrasound compared with direct cholangiography in the detection of choledocholithiasis. *Clin Radiol*. 2000 Jan;55(1):25-35. Erratum in: *Clin Radiol* 2000 Aug;55(8):657.
18. Ke ZW1, Zheng CZ, Li JH, Yin K, Hua JD. Prospective evaluation of magnetic resonance cholangiography in patients with suspected common bile duct stones before laparoscopic cholecystectomy. *Hepatobiliary Pancreat Dis Int*. 2003 Nov;2(4):576-80.
19. Zhang C, Yin M, Liu Q. The Guidance Impact of Preoperative Magnetic Resonance Cholangiopancreatography on Laparoscopic Cholecystectomy. *J Laparoendosc Adv Surg Tech A*. 2015 Aug 11. [Epub ahead of print]...
20. Ward WH1, Fluke LM, Hoagland BD, Zarow GJ, Held JM, Ricca RL. The Role of Magnetic Resonance Cholangiopancreatography in the Diagnosis of Choledocholithiasis: Do Benefits Outweigh the Costs?. *Am Surg*. 2015 Jul;81(7):720-5.
21. Lin C1, Collins JN, Britt RC, Britt LD. Initial Cholecystectomy with Cholangiography Decreases Length of Stay Compared to Preoperative MRCP or ERCP in the Management of Choledocholithiasis. *Am Surg*. 2015 Jul;81(7):726-31.