



Osteometric Implications of Incus

Authors

Dr Sandhya Mehra¹, Dr Shweta Asthana², Dr Kalpana Makhija³, Dr Aarushi Jain⁴

¹Senior Demonstrator, Dept. of Anatomy, GMC Kota, Rajasthan, India

Email: Drmehra83@gmail.com

²Senior Demonstrator, Dept. of Anatomy, GMC Kota, Rajasthan, India

Email: Dr.shweta.asthana@gmail.com

³Asst. Professor, Dept. of Anatomy, GMC Kota, Rajasthan, India

⁴Asst. Professor, Dept. of Anatomy, GMC Kota, Rajasthan, India

Email: Aarushi.jn81@gmail.com

Corresponding Author

Dr Kalpana Makhija

Asst. Professor, Dept. of Anatomy, GMC Kota, Rajasthan, India

Email: anatomygmckota@gmail.com

ABSTRACT

Dimension dynamics of incus plays a important role to achieve the best postoperative results in reconstruction of the ossicular chain but still their length adjustment may pose a problem clinically. Hence the present study is an attempt to identify all possible measurements of incus both parametric and non parametric so as to provide a vivid description for prosthesis manufacture. Clavaria of 30 cadavers were removed and the incuses were extracted of both the sides and their dimensions were measured from digital vernier calliper and weights were measured by digital analytical balance. All the datas were analyzed by medcalc software. The present datas were compared with the previous studies and a positive correlation was deduced between its various dimensions and its weight and angle and distance between the two processes. This study will give a new horizon for prosthesis designer and teaching the medical students about the basic structure of the middle ear as well as its related significance in Clinical Medicine and ENT.

Keywords: *Incus, Dimensions, middle ear and Ossiculoplasty.*

Introduction

Incus replacement length during ossiculoplasty should be precise and perfect as it plays a major role in imparting optimal tension between tympanic membrane and malleus and stapes head. In excessive outward movement of tympanic membrane incus glides at the incudomalleolar joint instead of following the full malleolar movement thereby preventing the dislocation of base of stapes. Thus dimension dynamics of incus plays a important role to achieve the best

postoperative results in reconstruction of the ossicular chain. Though a variety of Partial ossicular replacement prosthesis (PORPS) and Total ossicular replacement prosthesis (TORPS) are available commercially but their length adjustment may pose a problem clinically. Hence the present study is an attempt to identify all possible measurements of incus both parametric and non parametric so as to provide a vivid description for prosthesis manufacture.

Material and Methods

Present study was performed in 30 human cadavers. The clavaria of skull was incised and brain was removed carefully according to Cunningham’s manual of practical anatomy. The tegmen tympani was chipped off by using micro motor, chisel and hammer and the incus was removed and the dimensions were taken by digital vernier calliper with resolution of 0.01mm. Weight was taken by digital analytical balance with the sensitivity of 0.01mg. All the results which were obtained were analyzed using medcalc software i.e.

students t test was used for comparing the parametric data(table no. 1) and chi square test (table no. 2) was used for non parametric datas. Regression equation was also calculated between the weight and different parameters and angle and distance between the two processes (table no. 3) The angle of incus was measured using sketch up pro 2014 software.

Incus:

df= short process, de= long process,, ef= width between the two process, D1- diameter of incus, L= lenticular process

index = short process(df)/ long process(ef) X100

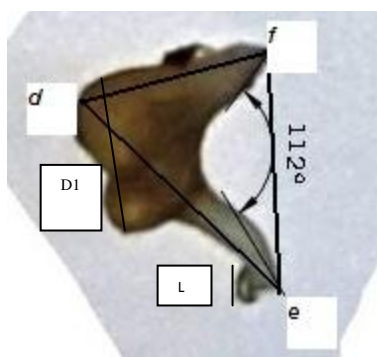


Fig 1

Incus with all dimensions and pedicled lenticular process (L)

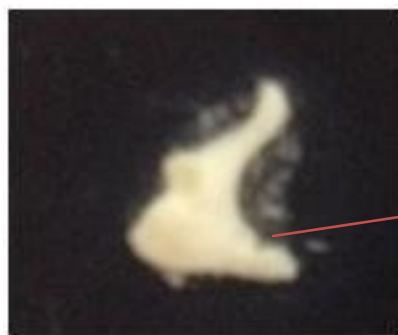


Fig 2

Short process with notch

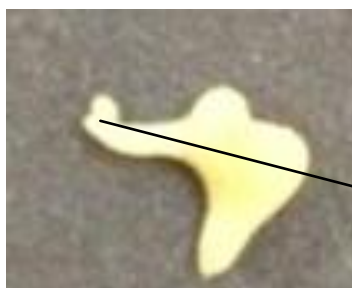

Fig 3

long process with pedicled lenticular process and short process without a notch



Difference in angles and pedicled lenticular processes in Fig 4A

Fig 4

Table1: Comparison of parametric data between right and left incus by t test

Variables	right incus		left incus		t-test	p-value
	mean	±sd	mean	±sd		
Angle	106.1	3.72	106.73	3.8	0.65	0.91
Long_process_de(mm)	6.58	0.45	6.54	0.44	0.37	0.86
Diameter_of_body_D1(mm)	2.77	0.31	2.61	0.33	2	0.78
Incus_lenticular_process(L)(mm)	0.79	0.14	0.78	0.13	0.17	0.79
Weight(mg)	26.66	1.46	26.91	1.27	-0.72	0.47
Index	92.78	10.63	92.24	9.4	0.21	0.53
Incus_short_process_df_(mm)	5.04	0.34	4.97	0.35	0.76	0.85
Incus_width_ef(mm)	6.07	0.48	6	0.4	0.62	0.35

Table no. 2- Comparison of non parametric datas of right and left incus

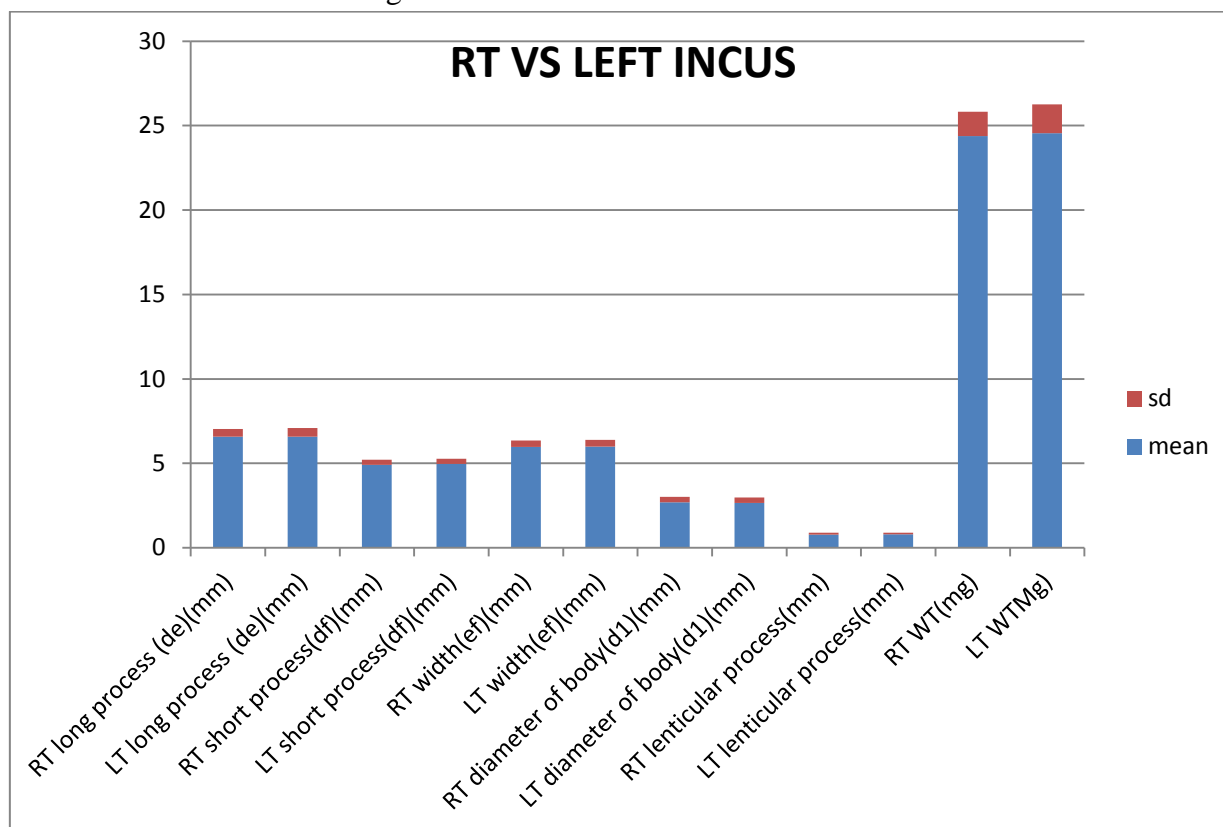
Parameters	Rt INCUS		Lt INCUS		Chi square	P value	Contingency coefficient
	Present	Absent	Present	Absent			
SHORT PROCESS WITH NOTCH	6.7%	93.3%	3.3%	96.7%	14	0.0002	0.564
PEDICLED LENTICULAR PROCESS	86.7%	13.3%	86.7%	13.3%	29	0.0001	0.701

Table no. 4 (Regression equation between various dimension of incus and their respective weights)

Variable		Coeff. Of Determination (R ²)	P value	Regression equation
Dependent(y)	Independent(x)			
Rt incus Weight	Rt incus long process	0.6314	<0.0001	y = 9.8531 + 2.5523 x
Lt incus Weight	Lt incus long process	0.7757	<0.001	y = 11.0353 + 2.4370 x
Rt incus Weight	Rt incus short process	0.1032	<0.0001	y = 19.8064 + 1.3844 x
Lt incus Weight	Lt incus short process	0.01	<0.0001	y = 25.0598 + 0.3832 x
Rt incus wt	Rt incus diameter of body	0.06471	<0.0001	y = 23.3469 + 1.1946 x
Lt incus wt	Lt incus diameter of body	0.0001165	<0.0001	y = 27.0758 + -0.03956 x
Rt incus angle	Rt incus width	0.4397	<0.0001	y = 65.3014 + 6.8421 x
Lt incus angle	Lt incus width	0.86	<0.0001	y = 57.862 + 8.14x

(Rt -right, Lt -left , Coeff-coefficient)

Graph no. 1- Difference between right and left incus



Rt – right ,Lt- left

Discussion

This study exemplifies an effort by the authors to provide a extensive revelation of measurement of the various parameters of the incus. The literature

available so far is devoid of wide observations even on the gross anatomy of the ossicles. Table no. 4 [1-13] and 5 [2,14] depicts the comparison of the parameters with that of previous studies.

Table no 4: Comparison of metric values of incus

Authors	De(mm)	Ef(mm)	Df(mm)	L(mm)	D1(mm)	Angle(o)	Wt(mg)	Index
Padmini et al 2014	5.13	4.5	3.47					
Kamal et al 2010	6.674	6.01	5.043			74.342	26.3	
Natekar & De Souza 2006	6.52	5.86	5.06				20.74	
Erdognan et al. 2002	6.5	6.1	4.9					
Aycan et al. 1990	6.7	6.1	5.1					
Arensberg Et al, 1981	6.8		5.1					
Harneja & Chaturvedi 1973	-						25.06	
Angel (1972)	6.8		4.9					
Harada(1972								
Arensberg &nathan,1971	6.4		5.1					
Bouchet & Giraut 1969	6.5		5.1					
Masali 1968	6.4		4.8					
Heron (1923)			5.2			76		
Present study	6.545	5.97	5.465	0.79	2.69	106.335	26.79	92.51

df= short process, de= long process., ef= width between the two process, D1- diameter of incus, L= lenticular process

Table no 5: Comparison of non metric values with previous studies

Parameters	Present study		Arsenberg et al 971	Whers et al 1999
	Short process with notch	Present	5.00%	Noticed
absent		95.00%		
Pedicled lenticular process	present	86.70%		Noticed absence of long process
	absent	13.30%		

Conclusion

The osteometric analysis of incus can prove to be a promising base to the otolaryngologist surgeons for implications in ossiculoplasty so as to regain the original mechanics. This study will also give a new horizon for teaching the medical students about the basic and detailed structure of the middle ear as well as its related significance in Clinical Medicine and ENT.

Consent –Not applicable

Ethical approval – Not applicable as study is on cadavers in department of anatomy, GMC kota.

Acknowledgement – We would like to thank PHOD Anatomy, GMC Kota and PHOD Pathology GMC kota and the authors.

Interest of conflict- none

Source of Funding- none

References

1. Angel JL (1972) A Middle Palaeolithic temporal bone from Darra-I-Kur, Afghanistan. *Translations of the American Philosophical Society* 62: 54-56
2. Arensburg B, Nathan H. Observations on a notch in the short (Superior or Posterior) process of the incus. *Acta Anat.* 1971;78: 84-90.
3. Arensburg B, Harell M, Nathan H (1981) The Human Middle Ear Ossicles: Morphometry and taxonomic implications. *J Hum Evol* 10:199-205.
4. Aycan K, Unur E, Bozkir MG (1990) Anatomical study of malleus. *J Health Sci* 1: 152-158.
5. Bouchet A, Giraud M (1968) Contribution a l'etude orphologique et radiologique des osselets de l'ouie. *Compte rendu de l'Association des Anatomists 53 Congres* 141: 588-600.
6. Dass Ramji, Grewal BS, Thapar SP (1966) Human stapes and its variations. I. General Features. *J Laryngol* 80: 11-25.
7. Harneja NK, Chaturvedi RP (1973) A Study of the Human Ear Ossicles. *Indian J Otol* 25: 154-160.
8. Kamal Singh*, Aarti Rohilla and Jyoti Rohila: Incus Morphometry: A Possible Tool in Sex Determination*, *J Forensic Res* 2016, 7:2
9. Heron IC (1923) Measurements and observations upon the human auditory ossicles. *Am J of Phys Anthropol* 6: 11-26
10. Masali M (1968) The Ear Bones and the Vertebral Column as Indications of Taxonomic and Postural Distinctions among Old World Primates with Reference to the Origin of Man. Torino: Rosenberg and Sellier.
11. Natekar PE, De Souza FM (2006) A morphometric study of malleus and incus and its clinical implications. *Indian J Otol* 12: 6-9.
12. Pramila Padmini and B. Narasinga Rao: Morphometry of Human Fetal Ear Ossicles: A Human Cadaveric Study: M.:British Journal of Medicine & Medical Research 4(9): 1873-1882, 2014
13. Unur E, Ulger H, Ekinci N (2002) Morphometrical and morphological variations of middle ear ossicles in the newborn. *Erciyes Tip Dergisi (Erciyes Medical Journal)* 24: 57-63.
14. Wehrs RE¹: Congenital absence of the long process of the incus. *Laryngoscope.* 1999 Feb;109(2 Pt 1):192-7.