



## Clinico Morphological Study of Anal Lesions

Authors

**Ponneyinchelvi.A.S<sup>1\*</sup>, U.Manohar<sup>2</sup>, P.Viswanathan<sup>3</sup>, Valluvan<sup>4</sup>**

<sup>1\*</sup>Post Graduate, Department of Pathology, RMMCH, Chidambaram-608002, Tamilnadu, India

<sup>2</sup>Professor, Department of Pathology, RMMCH, Chidambaram-608002, Tamilnadu, India

<sup>3</sup>Professor and Head, Department of Pathology, RMMCH, Chidambaram-608002, Tamilnadu, India

<sup>4</sup>Lecturer, Department of Pathology, RMMCH, Chidambaram-608002, Tamilnadu, India

### ABSTRACT

*Among the anal lesions, since the incidence of human papilloma virus infection is on the rise, lesions classified as anal squamous lesions are increasing in incidence. This group comprises both benign and malignant lesions.eg: benign squamous papilloma, squamous intra epithelial lesion, invasive squamous cell carcinoma. The chief HPV involved are HPV 16 and HPV 18. Study of these lesions in patients presenting to RMMCH, ANNAMALAI UNIVERSITY in respect to age, gender distribution, clinical presentation and histopathological confirmation may yield valuable informations regarding the epidemiology of anorectal lesions in the urban rural based area.*

**Keywords:** Anal lesions, Anal malignancies.

### INTRODUCTION

Among the anal lesions, since the incidence of human papilloma virus infection is on the rise, lesions classified as anal squamous lesions are increasing in incidence. This group comprises both benign and malignant lesions.eg: benign squamous papilloma, squamous intra epithelial lesion, invasive squamous cell carcinoma. The chief HPV involved are HPV 16 and HPV 18.<sup>1,2</sup> Study of these lesions in patients presenting to RMMCH, ANNAMALAI UNIVERSITY in respect to age, gender distribution, clinical presentation and histopathological confirmation may yield valuable informations regarding the epidemiology of anal lesions in the urban rural based area.

### METHODOLOGY

This is a prospective and retrospective study of the various Anal lesions reported in the Department of Pathology, RMMCH, Annamalai University from August 2006 to August 2016. The histomorphological pattern of the various Anal lesions are studied as per the standard characteristics. Correlation with clinical Presentations was done. The specimens were received in 10% formalin. Gross appearances of the specimens such as size, location, and appearance on cut section were recorded. The sections of 3-5 micron were prepared and stained with Haematoxylin and Eosin stain. All lymph nodes isolated were subjected for histopathological examination. The slides were examined by the pathologist of the department and reports were dispatched. Biopsy of adequate size and from

represented sites was included in the study. Inadequate biopsies were excluded.

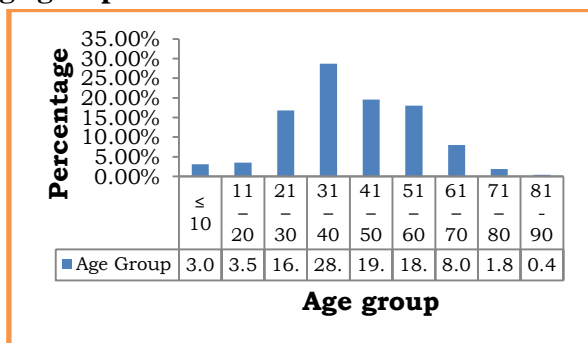
**OBSERVATIONS AND RESULTS**

The total number of Anal specimens received in the department of pathology, RMMCH during the period of study [August 2006 – August 2016] were 473. Study was done on these 473 cases based on Age, gender distribution, clinical presentation and histopathological examination.

**AGE GROUP DISTRIBUTION**

All cases studied were distributed according to their age of presentation at an interval of 10 years. It was found out that the maximum incidence occurred in the 4th decade which constituted 28.66% followed by 5<sup>th</sup> decade with 19.57%. Next group affected was 6<sup>th</sup> decade with 18.03%.

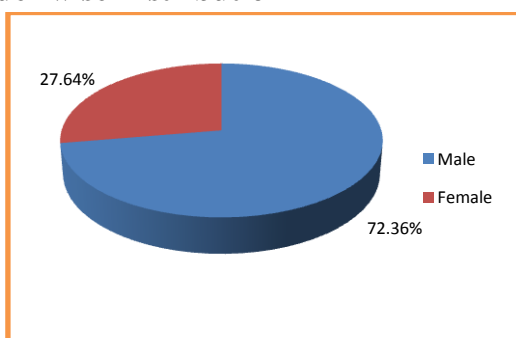
**Age group Distribution**



**GENDER WISE DISTRIBUTION**

Among the anal lesions studied, the total numbers of female patients were 170, which constituted 27.64% of the cases and the male patients were 445, which constituted 72.36% of the cases. Hence the male patients outnumbered female patients.

**Gender wise Distribution**



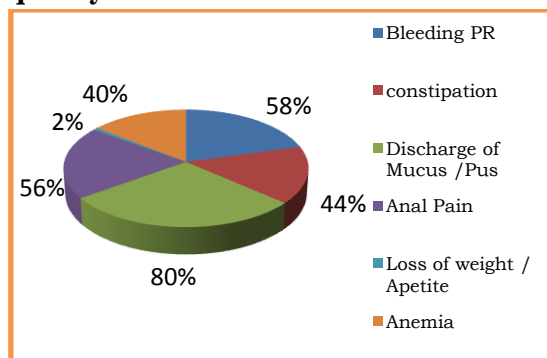
**FREQUENCY OF CLINICAL PRESENTATION**

The frequency of clinical presentation was studied and was found that majority of the cases presented with Discharge of mucus/ pus with 80% of patients having the complaint.

This was followed by bleeding per rectum with 58% of patients.

Next common presentation was Anal pain with 56% of the patients presenting with the complaint.

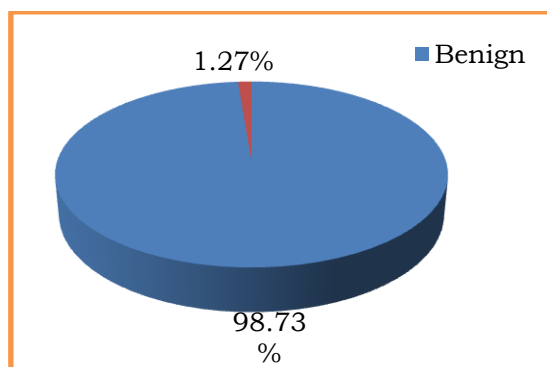
**Frequency of Clinical Presentation**



**BEHAVIOUR OF ANAL LESIONS**

Out of 473 anal lesions, 467 cases (98.73%) were benign, 6 cases (1.27%) were malignant. Benign lesions outnumbered malignant lesions.

**Behavior of Anal lesions**



**FREQUENCY OF ANAL LESIONS**

The frequency of each Anal lesion in the present study was compared with a standard study done by sarkar.H et al (2008). In Sarkar.H et al (2008) study, the most common lesion was haemorrhoids contributing to 62.18% of cases. In the present study Anal fistula was the most common lesion observed contributing to 56.69% of cases.

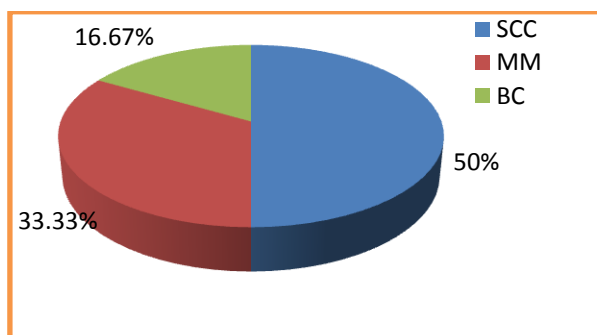
**Table –1:** Frequency of Ano-rectal lesions

LESIONS	Present study (2016)
Haemorrhoids	35.69 %
Anal fissure	2.11 %
Fistula in ano	56.69 %
Peri anal abscess	0.33 %
Pilonidal sinus	2.28 %
Anal malignancies	1.27%
Achrochordan	0.49 %
Condyloma Acuminatum	0.16 %
Benign squamous papilloma	0.33 %
Granuloma	0.33 %
Epidermal cyst	0.16 %
Capillary hemangioma	0.16 %

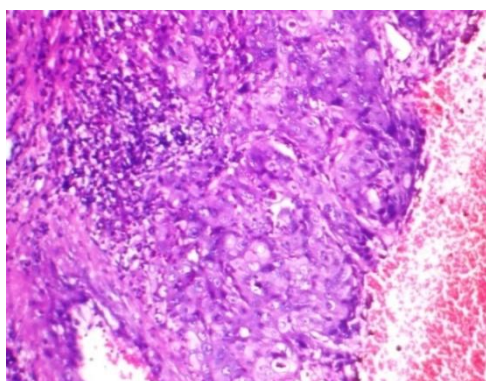
**HISTOPATHOLOGICAL TYPES OF MALIGNANT ANAL LESIONS**

Out of the 6 malignant Anal lesions 3 cases (50%) were squamous cell carcinoma, 2 cases (33.33%) were malignant melanoma 1 case (16.67%) was Basaloid carcinoma. Hence Squamous cell carcinoma was the most common malignant Anal lesion in the present study.

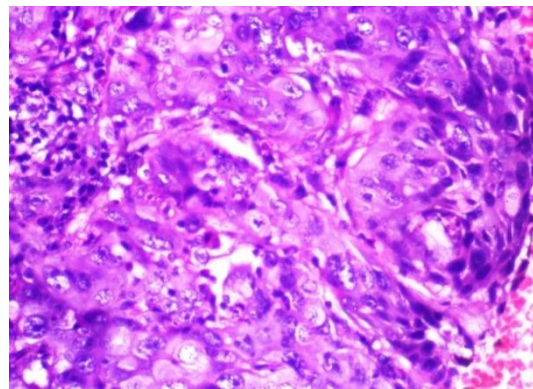
**Histopathological types of Malignant Anal lesions**



**BASALOID CARCINOMA**

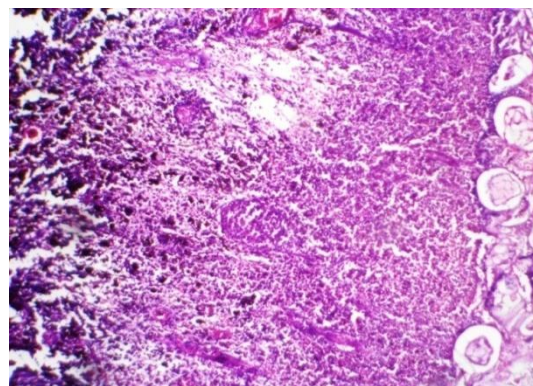


Nests of tumor cells comprising squamous cells, basaloid cells and other epithelial cells. (H&E: 4X, 10X)

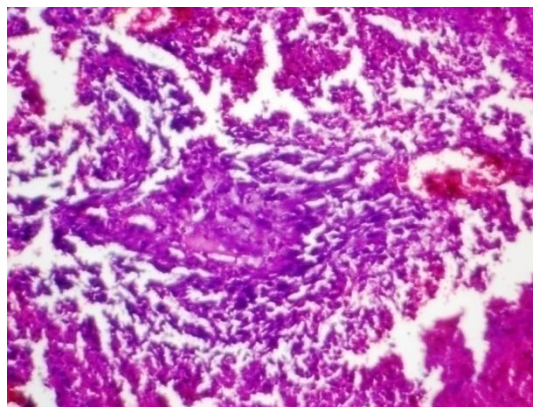


Markedly anaplastic and pleomorphic tumor cells. (H&E: 40X)

**MALIGNANT MELANOMA**



Extensive areas of necrosis, tumor cells with black melanin pigmentation. (H&E: 4X)



Epithelial cell nest surrounded by tumor cells with moderate amount of cytoplasm and hyperchromatic nuclei. (H&E: 10X)

**DISCUSSION**

The total number of Anal specimens received in the department of pathology, RMMCH during the period of study [August 2006 – August 2016] were 473. Out of 473 anal lesions, 467 cases

(98.73%) were benign, 6 cases (1.27%) were malignant. This shows that the benign lesions are more common in the Anal region than the malignant lesions. However some lesions which were diagnosed as benign lesions clinically has turned out to be malignant lesions when examined histopathologically. Hence complete and unbiased examinations of all cases is necessary. The most common age group of presentation is 4th decade. The incidence among male patients were far more common than the incidence among female patients. The less percentage of female patients may be due to social and religious bindings and shy to attend the clinic.. Moreover our female patients are neglected. Anal fistula was the most common lesion observed among Anal lesions, closely followed by haemorrhoids.

Discharge of mucus and pus was the most common presenting complaint. This correlates with the fact that fistula in Ano has the maximum incidence and it commonly presents with discharge of pus or mucus.<sup>3</sup> Squamous cell carcinoma was the most common histopathological type of malignancy observed and this finding correlates with literature and other standard study done by Sarkar et al (2008)<sup>4</sup>.

## CONCLUSION

The total number of Anal specimens received in the department of pathology, RMMCH during the period of study [August 2006 – August 2016] were 473. Among Anal lesions, benign lesions outnumbered malignant lesions. Majority of the patient are in their 4th decade of life. Male patients outnumbered female patients by a very large margin.

Discharge of pus and mucus was the most common clinical presentation. The most common benign lesion observed was Anal fistula. The most common malignant lesion observed was Squamous cell carcinoma. Also a small percentage of cases which were diagnosed clinically as benign lesions turned out be malignant lesions histopathologically. Hence a careful unbiased clinical as well histopathological examination of all cases presenting to our hospital is necessary.

## REFERENCES

1. Juan Rosai and Ackerman's Surgical Pathology. 10th ed. Mosby Elsevier; 2011
2. Vinay Kumar, Abdul K Abbas, Jon C Aster, eds: Robbins and Cotran Pathologic Basis of Disease. 9<sup>th</sup> ed. Elsevier; 2014
3. Basil C. Morson et al: Morson and Dawson's Gastrointestinal Pathology. 3rd ed. Blackwell Scientific Publications; 1990
4. H Sarkar, M Hassan, R N Laila Pattern of Anorectal Disorders in Surgical Practice in Rajshahi TAJ June 2008; Volume 21 Number 1 ISSN 1019-8555