



Clinical study of Nd Yag Laser in the treatment of Posterior Capsular Opacification after Cataract Surgery

Authors

Selvi K¹, Mishra P², Manavalan S³, Sridevi V⁴, Ramya M⁵, Ramakrishnan G⁶

Department of Ophthalmology, Rajah Muthiah Medical College and Hospital, Annamalai University,
Annamalai Nagar-608002

Abstract

Background: *The Nd YAG laser is a solid-state laser with a wavelength of 1064 nm that can disrupt ocular tissues by achieving optical breakdown with a short, high-power pulse. It is a technique for closed-eye, which is being used in the treatment of PCO. Posterior capsular opacification is caused by proliferation of lens epithelial cells which causes fibrotic changes and wrinkling of the posterior capsule and results in decreased vision, glare. Objective: To study the efficacy and complications of Nd YAG laser in treatment of postoperative posterior capsular opacification.*

Material and Methods: *This study was conducted in the Department of Ophthalmology Rajah Muthiah Medical College Chidambaram, from Oct 2015 to Sep 2016 on 50 patients with significant PCO, using Zeiss VISULAS YAG II. These patients were assessed for post-laser visual acuity and possible complications just after 4hrs, 1day, 2 weeks, 3 months, and 6 months.*

Result: *Out of 50 patients 27 (64 %) were males and 23 (46 %) were females. During and following Nd YAG laser capsulotomy out of 50 patients 4 patients (8%) developed intraocular lens (IOL) pitting, two patients (4%) developed rise in intraocular pressure (IOP), three patients showed iritis (6%), one patient (2%) developed cystoid macular edema (CME). The best corrected visual acuity (VA) of 6/9 – 6/6 was achieved in 36 eyes (72%).*

Conclusion: *The Nd YAG laser capsulotomy is a safe, effective outpatient procedure to create an opening in opaque posterior capsule for the improvement in vision.*

Key words: *Nd YAG laser capsulotomy, posterior capsular opacification, visual acuity.*

Introduction

Cataract is defined as any opacity in the lens or its capsule whether developmental or acquired, stationary or progressive causing visual impairment, and is the leading cause of curable blindness in India and cataract Extraction is the most frequently performed operation in patients over 85 years of age.

The most recent estimates from WHO reveal that 47.8% of global blindness is due to cataract and in

South Asia region which includes India, 51% of blindness is due to Cataract¹. In India Incidence of cataract in 2001 was estimated as 7.75 million individuals whose blindness could be attributed to cataract and this would increase to 8.25 million by 2020¹

Cataract is a normal consequence of aging and is reported to develop in 18% of people between ages of 65 and 75 years and in 46% between 75 and 85 years². With time the cataract surgery has

been changed since couching in ancient times to ICCE, ECCE, MSICS and Phacoemulsification.

In ECCE, MSICS and Phacoemulsification, with preservation of posterior capsule of lens allows placement of PCIOL and prevents prolapse of vitreous into anterior chamber. It also reduces the risk of several complications, including vitreous loss and subsequent vitreous detachment, retinal detachment and cystoid macular edema.

Sometimes, the left out posterior capsule opacifies by forming the dark cloud in front of visual field once more. In fact this is the most commonly occurring complication of ECCE and Phacoemulsification, occurring in about 25% of cases within 5 years of surgery³.

Opacification of posterior capsule can lead to clinically significant reduction in visual acuity, impaired contrast sensitivity, glare disability and monocular diplopia.

Nd YAG laser is pulsed instrument which can be used to photo disrupt this opacified posterior capsule. Nd YAG laser posterior capsulotomy is a rapid safe and relatively less invasive and painless procedure, than surgical dissection which may be associated with higher rate of complications and dreaded complications like endophthalmitis.

Pathogenesis of Posterior Capsular Opacification

The term Posterior Capsule Opacification is a misnomer⁴. It is not the capsule which opacifies, rather an opaque membrane develops as retained cells proliferate and migrate onto posterior surface.

It can take months to years for its development. Most secondary cataracts are caused by proliferation of the equatorial lens epithelial cells, forming the "pearl" form of PCO.

In the rural developing world, where there is often a long wait for cataract surgery, the abnormal cataractous posterior lens epithelial cells may undergo pseudo fibrous metaplasia creating a posterior fibrous plaque⁵.

Pathogenesis of PCO is multivariated⁶. In normal crystalline lens, the lens epithelial cells are confined to anterior surface at equatorial region

and equatorial lens bow. This single row of cuboidal cells can be divided into 2 different biological zones.

1. Anterior central zone (A-cells) It consists of monolayer of flat cuboidal anterior epithelial cells proliferate and undergo pseudo fibrous metaplasia which has been termed by Forst and Brownstein⁷
2. The second zone is important in the pathogenesis of pearl formation. This layer is continuation of anterior lens epithelial cells around the equator forming the equatorial lens bow (E-cells).

In pathologic states, they tend to migrate posteriorly to form such lesions as posterior sub capsular cataract as well as postoperative PCO following ECCE.

Clinically optical degradation of initially clear PC takes several forms⁴.

1. Fibrosis - connotes a grey white band or plaque like opacity.
2. Heavy fibrosis occurs frequently at the edge of PC IOL placed in bag with apposition of anterior and posterior capsule.

Factors Contributing to Fibrosis

- a. Contact with Poly Methyl Metha Acrylate (PMMA) enhances the myofibroblastic differentiation of epithelial cells in some eyes.
- b. Opacification sometimes follows the configuration of wrinkling seen in early postoperative period.
- c. Fibrosis is more common in convex posterior type of lenses.
- d. Fibrosis is enhanced by chronic inflammatory syndromes.

Capsular pearls-Second major form of opacity, occurs months to years after surgery.

It consists of clusters of swollen opacified epithelial pearls or cluster of posteriorly migrated equatorial epithelial cells (bladder or wedl cells)⁸. The individual subcapsular epithelial cells enlarge and swell to such a degree that they have the appearance of soap bubbles. This response

represents aberrant attempts of epithelium to form new lens fibres. They are usually referred to as “Elschnig’s pearls”. These pearls resemble fish eggs on posterior capsule. A single epithelial cell may swell up to considerable size and reach a diameter of 2 mm⁹.

In addition the epithelium may be responsible for formation of free lentoid bodies¹⁰.

During surgery, variable amount of lens cortex may remain in eye. They usually undergo lysis by aqueous but may persist sometimes. When they persist, they become enmassed in the periphery, incorporated in a ring- like structure¹¹. (First described by Sommerring in 1828).

Capsular wrinkling – can have 2 manifestations.

- a. Broad undulations of clear capsule are common during early postoperative period. PC lens haptics may induce these broad wrinkles along the axis of haptic orientation, Fibrotic contractions can also induce wrinkles. Broad undulating wrinkles of clear capsule rarely are visually disturbing to the patient.

1. Fine wrinkles or folds in capsule caused by myoblastic differentiation which acquire contractile properties resulting in Maddox rod effect.⁷

2. Pigment deposition

Factors influencing the Posterior Capsular Opacification:

Surgical techniques

During surgery, manipulation should be least possible to minimize inflammation which may stimulate cellular proliferation¹².

Use of Heparin in irrigating solution are surface of the IOL to decrease the incidence of PCO.

Lens cortical lamellae should be removed thoroughly.

Age of the patient:

In children, PCO occurs almost in 100% within 2 years of surgery. This is because of greater proliferative potential of lens epithelial cells in younger age group.

Posterior capsulorrhexis with optic capture in paediatric cataract and IOL surgery prevents PCO.

Uveitis

In eyes with active uveitis, there are increased chances of inflammation and hence PCO.

IOL Material and designs

PCO occurs more frequently if no IOL implantation accompanies ECCE.

All PMMA IOLs are found to be better compared with IOLs with polypropylene loop haptics because PMMA haptics have better memory and hence stretch the capsular bag more effectively.

Posterior convexity of the optic and posterior angulation of IOL haptics are other factors which help in reducing the incidence of PCO.

Pharmacological inhibition of Posterior Capsular Opacification

Mitotic inhibitors instilled into the anterior chamber after extra capsular cataract extraction have been shown to reduce capsular opacification dramatically.¹⁴

In diabetes mellitus patients the rate of PCO development is lesser as compared with non-diabetic patients¹⁵. Additionally the presence of intraocular silicone oil may dramatically speed the progression of opacity.

Six Factors to Reduce PCO¹⁶

Surgery-Related Factors (“Capsular” Surgery)	IOL-Related Factors (“Ideal” IOL)
<ul style="list-style-type: none"> • Hydro dissection-enhanced cortical cleanup • In-the-bag fixation • Small CCC with edge on IOL surface 	<ul style="list-style-type: none"> • Biocompatible IOL to reduce stimulation of cellular proliferation • Maximal IOL optic-posterior capsule contact, angulated haptic, “adhesive” biomaterial to create a “shrink wrap”. • IOL optic geometry square, truncated edge

Treatment of Posterior Capsular Opacification

With the current popularity of ECCE and Phacoemulsification, there has been an increase of experience with prevention and treatment of after-cataract.

The finding that PCO results from lens epithelial cells proliferating onto posterior capsule at the site of apposition of anterior capsule flaps, explains

the inadequacy of polishing the capsule at surgery to delay onset or reduce the frequency of late capsular opacification, because polishing PC cannot remove the epithelial cells from the anterior capsule flaps¹⁷.

The Nd YAG laser is the non-invasive method can be performed in office with topical anaesthesia. It is usually performed in a few minutes with no discomfort to the patient and has an added benefit of eliminating endophthalmitis as a potential complication.

Laser fundamentals

Laser is an acronym for instrument's mode of action "Light Amplification by Stimulated Emission of Radiation". Lasers are only one of many sources of light energy¹⁸.

Nd YAG laser posterior capsulotomy:

Nd YAG laser: is a solid state laser with a wavelength of 1064 nm that can disrupt ocular tissues by achieving optical breakdown with a short high power pulse.

YAG laser is a solid state laser made up of manmade crystal originally developed as a gemstone -Yttrium-Aluminium-Garnet $Y_3Al_5O_{12}$.

Nd YAG laser is a pulsed instrument that acts by formation of plasma at its focal point inducing an explosive expansion of tissue.

Q switching (quality switching) is a technique to increase power by shortening time interval.

Two types of Q switching

1. Active form (simply referred as Q switching)
2. Passive form (known as mode locking.)

Due to non-linear absorption, an optical breakdown occurs a bubble is produced. This disruption is result of a shock wave which then spreads and changes into an acoustic wave causing a loud snap which can be heard by the patient.

Indications

- a. Following are the indications for Nd YAG posterior capsulotomy:
- b. Best corrected visual acuity symptomatically decreased as a result of hazy posterior capsule.

- c. A hazy posterior capsule preventing the clear view of ocular fundus required for diagnostic or therapeutic purposes.

Monocular diplopia or glare caused by posterior capsule wrinkling or by encroachment of partially opened posterior capsule into visual axis of patient with otherwise clear media and good acuity.

Contraindications

Absolute

1. Corneal scars, irregularities or edema that interferes with target visualization.
2. An uncooperative patient who is unable to remain still or hold fixation during the procedure, with threat of inadvertent damage to adjacent intraocular structures.

Relative

1. Glass IOL, because of possibility of causing a complete fracture in glass optic.
2. Known or suspected CME.
3. Active intraocular inflammation.
4. High risk for retinal detachment.

Technique

Preoperative Assessment

- Complete ophthalmic history including notation of medical history and use of any topical and systemic medication.
- Visual acuity recording.
- Measurement of IOP in both the eyes.
- Slit lamp examination to note down the degree of fibrosis and pearl form of PCO.
- Direct ophthalmoscopic visualization of fundus structure.

Assessment of optical significance of capsular opacity

1. Direct ophthalmoscopic visualization of fundus structures.
2. Retinoscopy.
3. Red reflex evaluation by
 - i. Slit lamp examination.
 - ii. Direct ophthalmoscopic examination.
 - iii. Indirect ophthalmoscopic examination.
4. Hruby lens view of fundus.

Dilatation of the Pupil (Optional)

It is optional however, there is some evidence to suggest that although smaller centralized

capsulotomy openings are as effective as large openings in terms of effect on visual acuity.

Capsulotomy size and laser energy

Holladay et al¹⁹ suggested that the minimum theoretical size that is 2.4 mm in diameter would cause decreased image intensity and increased problem with glare, larger capsulotomies may be needed to alleviate the symptoms of glare.

Results

Nd YAG laser posterior capsulotomy results in improved visual acuities in 83% to 96% of eyes. Failure of vision to improve following Nd YAG laser posterior capsulotomy is often due to pre-existing ocular diseases, including age related macular degeneration, CME, other macular diseases, RD, corneal edema, glaucoma, ischaemic optic neuropathy and amblyopia.

Post-Operative Care

After Nd YAG laser posterior capsulotomy, apraclonidine or a beta-blocker should be administered topically to minimize any intraocular pressure rise.

Treatment following laser therapy with topical and cycloplegic agents varies widely according to individual surgeon's experience.

In the early 1980's the application of Nd YAG laser as treatment for PCO was presented by Aron-Rosa²⁰ and Fankhauser, at a time when advantage of surgery with intact posterior capsules was becoming widely appreciated.

Complications causing decreased vision are uncommon but include:

- Elevated IOP
- CME
- RD
- IOL damage
- Endophthalmitis
- Iritis
- Vitritis
- Macular hole
- Corneal edema

AIMS AND OBJECTIVES

1. To study the efficacy of Nd YAG laser in treatment of postoperative posterior capsular opacification.
2. To study the complications of Nd YAG laser posterior capsulotomy.

Materials and Methods

The present study comprised of a total no 50 patients of Nd YAG laser in the treatment of posterior capsular opacification after cataract surgery, who attended the Department of Ophthalmology, Rajah Muthiah Medical College and Hospital from the period of 2015 to 2016.

Selection criteria:

Inclusion criteria:

All patients with postoperative posterior capsular opacification with vision <6/9.

Exclusion criteria:

- a. Posterior Capsular Opacification(PCO) associated with corneal scars, irregularities, or edema that interferes with target visualization.
- b. Posterior Capsular Opacification associated with active intraocular inflammation.
- c. Posterior Capsular Opacification associated with cystoid macular edema or other complications that is likely to reduce visual acuity.
- d. An uncooperative patient who is unable to remain still or hold fixation during the procedure, with threat of inadvertent damage to adjacent intraocular structures.

Sample Size

As the prevalence rate of posterior capsular opacification after five years of cataract surgery is 50 %, size of the sample works out to be 50 cases. All patients with posterior capsule opacification were subjected to Nd YAG laser capsulotomy.

Data Collection:

Name, Age, Sex and Address of all the patients were noted.

Local examination was done as follows:

- a. **Visual acuity** - BCVA was noted from Snellen's chart or Landoldt's broken ring depending upon cases.
- b. **Slit lamp examination-**

- i. Diffuse examination.
- ii. Oblique and slit illumination.
- iii. Retro illumination

On the slit lamp, apart from the other features of anterior segment, PC opacity was noted and was graded into 3 groups.

- c. **Direct Ophthalmoscopy:** was done and PCO was graded into 3 groups based on clarity of visualization of posterior segment.

Grading of PCO:

PCO was graded according to the protocol followed in Madurai Intraocular Lens study. PCO was graded according to following levels of severity based on slit lamp and dilated direct ophthalmoscopic evaluation²¹.

Grade 0-No PCO, no evidence of PCO seen before and after pupillary dilatation to a minimum of 6 mm. With a direct ophthalmoscope, a clear view of the optic disc, blood vessels and nerve fibre layer is obtained.

Grade 1-No central PCO is seen. PCO is seen only with pupil dilated to a minimum of 6 mm. With a direct ophthalmoscope, a clear view of optic disc, blood vessels and nerve fibre layer is obtained.

Grade 2 - PCO is present in central visual axis detectable with an undilated pupil. With a direct ophthalmoscope, there is a mild obscuration of fundus detail in that optic nerve head is clearly seen, but nerve fibre layer and blood vessels are not clearly seen.

Grade 3-PCO is present in central visual axis, with an undilated pupil. With a direct ophthalmoscope, there is marked obscuration of fundus details that even the margins of optic nerve head are not clearly defined, because of PCO.

Tonometry: Preoperative baseline intraocular pressure was taken by Schiottz tonometer. It was recorded at least 1 hour before the procedure.

Methods

All patients with Grade 2 and Grade 3 PCO were subjected to Nd YAG laser capsulotomy.

The procedure to be done and complications associated with it were described to all patients and informed written consent was taken.

All eyes were dilated with tropicamide 1% eye drops 1 hour prior to laser therapy and topical 4% Xylocaine was instilled to each eye under study. 1% Apraclonidine eye drops was installed 1 hour before the procedure to blunt the effect of IOP rise.

All the capsulotomies were done using Zeiss VISULAS YAG II laser system. Since Nd YAG laser beam is an invisible infrared ray (wavelength 1064 nm), the red semiconductor laser (wavelength 633 nm) is used as aiming beam from YAG laser. The laser system was so designed that aiming beam becomes co-axial with YAG laser beam and target for alignment is where the 2 alignment spots converge into 1 spot. (Dual beam focusing system).

Technique-Patient was seated comfortably with proper adjustment of stool, table and chin rest heights.

The procedure was done in a darkened room.

All the capsulotomies were done at single burst per pulse and energy level of procedure was between 1.2 mJ to 3.1 mJ. If the PC was too thick, the level of energy was increased. Most of the total energy used was between 14.4 mJ to 128 mJ. The aiming beam was focused on posterior capsule or just behind it in order to protect IOL. An inverted U-shaped capsulotomy of about 3 mm in diameter was performed. With time, the U-shaped flap retracts down to reveal a clear central visual axis. By this method, the chances of pitting of central visual axis of IOL were avoided. It was ensured that visual axis was clear of any opacity.

Post-operative care: after Nd YAG laser capsulotomy in all patients, apraclonidine 1 % eye drops was administered topically to minimize intraocular pressure spike.

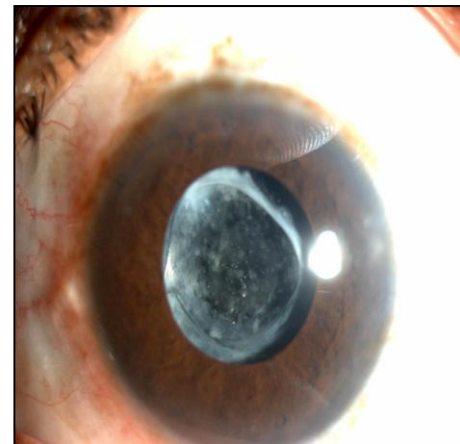
All the eyes were examined again postoperatively by Schiottz tonometer four hours after the procedure and after one day.

Best corrected visual acuity was recorded by Snellen's chart or Landoldt's broken ring, whichever was applicable at 24 hours postoperatively.

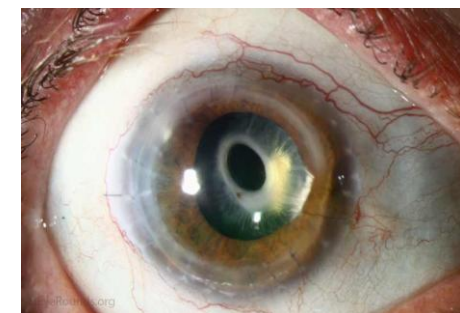
The patient was prescribed 1% prednisolone eye drops

QID tapered over 1 week.
 The following follow up protocol was used to observe for complications.
 Examination was done-
 4hrs after laser
 1day after laser

2 weeks after laser
 3 months after laser
 6 months after laser



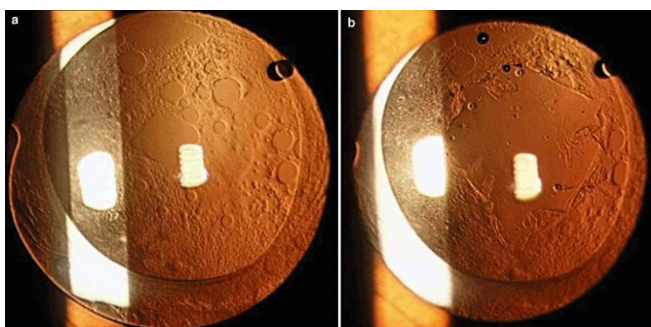
Fibrous type PCO



Fibrous type PCO after Yag Laser showing clear visual axis

Carl Zeiss NdYag Laser Instrument

Table – 1 : Sex Distribution of Patients



Pearl type PCO before and after Yag Laser

Sex	No. of cases	Percentage
Males	27	54.0
Females	23	46.0
Total	50	100.0

OBSERVATION AND RESULTS

In our present study of 50 patients with PCO, all eyes were subjected to Nd YAG laser posterior capsulotomy.

The results of study are as follows:

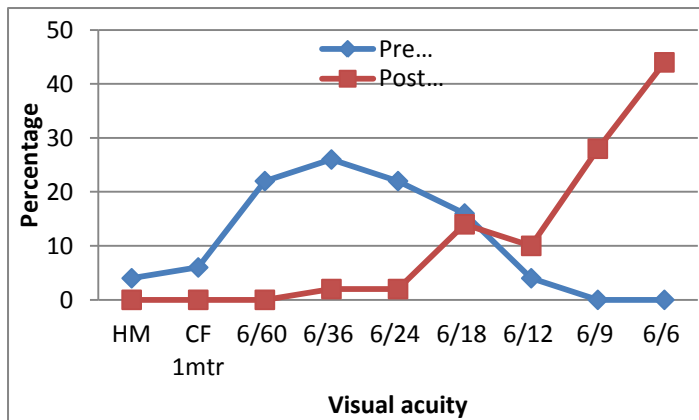
A total of 50 patients were treated, of which 27 were male and 23 were female. Majority of the people were from a low socio economic background.

The age incidence of patients was as follows. The youngest age among the female patients was 42 years and oldest was 76 years. Similarly in male patients, youngest male was 42 years, and oldest was 80 years. Maximum no. of patients affected were in the age group between 61-70 years. Their no was 22. They constituted more than 40% of total cases.

Table – 2 : Distribution of Total Energy Used

Total energy used	No. of eyes	Percentage
<30mJ	8	16.0
30.01-60mJ	31	62.0
60.01-90mJ	8	16.0
90.01-120mJ	2	4.0
>120mJ	1	2.0
Total	50	100.0

39 patients required total energy between 30 mJ and 90 mJ. Out of which most of them required below 60 mJ, their number was 31. A total of 2 patients required more than 90mJ out of which 1 required more than 120 mJ. The maximum amount of energy used was 117.8 mJ and minimum was 14.4 mJ.



Fig– 1: Distribution of Best Corrected Visual Acuity

Distribution of best corrected visual acuity. The preoperative BCVA was mostly within the range of counting fingers to 6/24. The no in that group was 38.

Only 2 had a BCVA of appreciating only hand movements.

Of the patients who had relatively better vision in the whole group, only 2 had BCVA of 6/12 and 8 had BCVA of 6/18.

Postoperatively, 36 patients had BCVA of 6/9 and 6/6. The no. of patients with BCVA of 6/12 was 5 patients, and BCVA of 6/24 was 1 and 7 patients had BCVA of 6/18. Only 1 had BCVA ≤ 6/36. He developed cystoid macular edema, with treatment his vision improved.

Table – 3: Distribution of Improvement of Vision in Snellen’s Chart

Improvement	No. of patients	Percentage
≥3 lines	25	50.0
> 2 lines	18	36.0
> 1 line	7	14.0
No improvement	0	0
Decrease	0	0
Total	50	100

Improvement of 3 lines or more was seen in 25 patients, 18 patients had an improvement of 2 lines and 7 patients had an improvement of 1 line

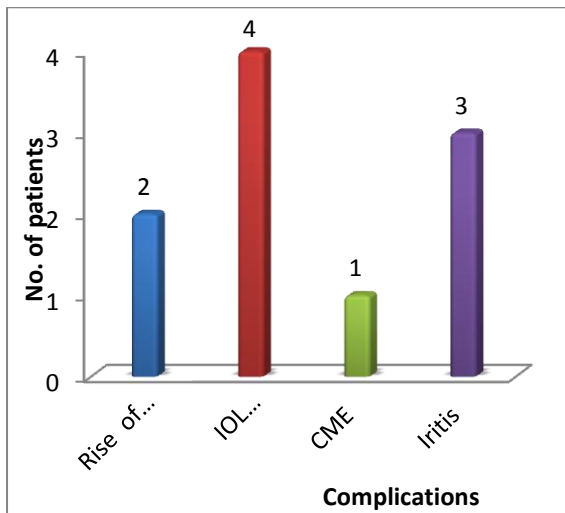
Table – 4: Distribution of Complications

Complications	No. of Patients
Rise of IOP	2
IOL markings & pitting	4
CME	1
Iritis	3

The patients were followed up for a period of 6 months. Out of 50 eyes treated, 2 patients had acute rise of intraocular pressure. Both the patients were treated with anti glaucoma medications their pressures returned to base line. IOL pitting was observed in 4 eyes. This pitting was not visually significant and did not produce any glare or image degradation.

3 patients developed iritis, which was treated with topical steroids and cycloplegics. Iritis resolved subsequently without causing any significant long term reduction of vision.

1 patient developed CME, with treatment it resolved without any deteriorating effect on vision.



Fig– 2: Distribution of Complications

Discussion

PCO is one of the most common complication following extra capsular cataract extraction. Postoperative opacification of initially clear posterior capsule occurs frequently in patients after any type of extra capsular cataract extraction. The patient complains of symptoms such as blurred vision, visual distortion and glare resulting in inability to carryout activities of daily living due to decreased visual acuity or an increase in glare.

Nd YAG laser capsulotomy is non-invasive, effective and it is done as an OPD procedure.

The present study of 50 eyes of Nd YAG laser in the treatment of posterior capsular opacification after cataract surgery was done in department of ophthalmology, Rajah Muthiah Medical College & Hospital Chidambaram

On comparing with the other studies the improvement in visual acuity is shown as follows. From the above data it may be summarized that more than 60% of eyes had an improvement of visual acuity of more than 2 lines after Nd YAG laser capsulotomy.

Our improvement in vision was better than what Skolnick RA et al²³ reported and less than what

Improvement	Greenidge et al	Sklonick et al	Terry AC et al	Michael J Flohr et al	Present study
≥3 lines	83%	45.3%	67%	57%	50%
2 lines		20.3%	25%	39%	36%
1 line	9%	24.1%			14%
No improvement	0	9%			0
Decrease in vision	3.5%	1.4%			0

Terry AC et al reported. Michael G Flohret al²⁴ had a finding similar to what we found in our present study.

Greenidge et al²² had a finding which can be compared to with our findings. Overall the above table suggests that our study findings are comparable with other studies and visual outcome in all studies are good.

Distribution of intraocular pressure during the study is as follows:

Intraocular pressure	Pre-operative	4hrs after laser	24 hrs after I laser
< 14mmHg	9	6	7
14-16mmHg	19	22	22
16-18mmHg	12	11	11
18-20mmHg	8	9	8
20-22mmHg	2	2	2
>22mmHg	0	0	0

There was no significant difference in intraocular pressure before and after Nd YAG laser capsulotomy, since we had used topical 1% apraclonidine eye drops, prophylactically to blunt the transient intraocular pressure rise, usually observed after Nd YAG laser capsulotomy. Only 2 patients had significant rise of intraocular pressure With prophylactic use of 1% apraclonidine eye drops topically the frequency and magnitude of intraocular pressure rises can be reduced significantly.

On comparing with other studies the complications of Nd YAG laser capsulotomy are as follows-

Complications	Juhas et al	Keates et al	Pop et al	Present study
Transient rise of intraocular pressure	1.4%	3.6%	14.73%	2%
Damage to intraocular lenses	40.3%	-	8.77%	9%
Moderate iritis	-	-	1%	3%
Disruption of anterior hyaloid face	3.8%	-	-	-
Cystoid macular edema	-	2.3%	-	1%
Retinal detachment	—	0.4%	—	—

We can conclude from the above data that the common complications associated with Nd YAG laser capsulotomy are transient rise of intraocular pressure and damage to intraocular lenses in the form of pitting.

The incidence of rise of intraocular pressure after YAG laser capsulotomy is almost similar in all the studies. Pop et al²⁶ reported a slightly higher incidence of rise of intraocular pressure.

The risk of damage to intraocular lenses in our study was significantly lesser than that reported by Juhas et al²⁵. Pop et al had a finding similar to our present study.

The incidence of moderate iritis and in our study was comparable with other studies.

Summary

The present study entitled Nd YAG laser in the treatment of Posterior capsular opacification after cataract surgery was carried out in Department of Ophthalmology, Rajah Muthiah Medical College & Hospital, Chidambaram between 2015 and 2016

A total of 50 patients were studied. The age of patients varied between 42 and 80 years. There were 27 males and 23 females, on whom Nd YAG laser posterior capsulotomy was done.

A comprehensive preoperative ophthalmic evaluation including Snellen's visual acuity, Slit

lamp examination, direct ophthalmoscopy, Schiottz tonometry and fundus examination (whenever possible) was done.

An inverted U-shaped capsulotomy was done. The postoperative IOP was measured at 4hrs and 24hrs after the procedure. The postoperative visual acuity was recorded at 24hrs after the procedure.

During the course of present study, the following observations were made:

The age of patients undergoing capsulotomy varied from 42 to 80 years with majority of patients in the age group of 60-70 years. This showed that most of cataract extraction was done at an older age group.

The no of males were more than the no of females treated.

The preoperative visual acuity had diminished grossly in patients with posterior capsular opacification. 80 % of patients had a vision of < 6/24.

Most of capsulotomies required an energy level between 1.6 mJ and 2.4 mJ. Maximum energy level required was 3.1 mJ.

Total energy required to perform the capsulotomies varied from 14.4 to 117.8 mJ. More than 50% of the patients required energy level in the range from 30mJ to 60 mJ.

At 24 hours, the improvement of visual acuity was excellent with all patients having an improvement of 1st line or more on Snellen's chart.

There was no significant difference in intraocular pressure before and after the laser, since we had used apraclonidine 1% topical eye drops as a prophylactic agent to blunt the intraocular pressure spike.

Out of 50 eyes treated, 2 patients had transient rise of intraocular pressure, intraocular lens damage was observed in 4 cases, iritis was seen in 3 patients, cystoid macular edema developed in 1 patient. These complications were not associated with long term loss of visual acuity.

Conclusion

The study of Nd YAG laser in the treatment of posterior capsular opacification after cataract surgery conducted on 50 eyes in the department of

ophthalmology RMMCH Chidambaram concludes that the improvement in visual acuity is excellent after Nd YAG laser capsulotomy. It is relatively non-invasive and can be performed as an OPD procedure.

Since PCO is a visually disabling condition reducing ability of patient to carry out the activities of daily living, Nd YAG laser capsulotomy with its remarkable outcome on visual acuity and with least complications acts as a boon to such patients limiting the need for undergoing a second operative procedure. It thereby reduces the cost that could have been imposed by operating room usage and inpatient care.

Although this procedure is safe, it is associated with complications like transient intraocular pressure rise, pitting of the intraocular lenses, mild iritis which are not vision threatening and they are transient. Therefore this treatment modality is cost effective and safe.

References

1. Murthy GVS, Gupta SK et al. Current status of cataract blindness and vision 2020. Indian J Ophthalmology. 2008;56(6): 489-494
2. Apple DJ, Solomon KD, Tetz MR et al, Posterior capsule opacification. SurvOphthalmol. 1992; 37:73-116.
3. Keates RH, Steinert RF, Puliafitoc A. Long term follow-up of Nd YAG laser posterior capsulotomy. Am Intraocular Implant Soc J.1984; 10; 164-8.
4. Roger F. Steinert, Howard Finek, Howard V. Gimbel et al, "Cataract surgery Technique, Complications and Management". 2nd Edition. WB Saunders Company. Pg.no.531-544.
5. Peng Q, Henning A, Vasavada AR et al, Posterior capsular plaque a common feature of cataract surgery in the developing world. Am J Ophthalmol 1998; 125:621-26.
6. Schaumberg DA, Dona MR, Christen WG et al, A systematic overview of incidence of posterior capsular opacification. Ophthalmology. 1998; 105: 1213-21.
7. Font RL, Brownstein S. A light and electron microscopic study of anterior subcapsular cataract. Am J ophthalmol. 1974; 78:972-84.
8. McDonell PJ, Zarbin MA, Green WR. Posterior capsule opacification in pseudophakic eyes. Ophthalmology. 1983; 90:1548.
9. Cowan A, Fry WE. Secondary cataract with particular reference to transparent globular bodies. Arch ophthalmol. 1937; 18:12-22.
10. Norman S Jaffe, Mark S Jaffe, Gary F. Jaffe. "Cataract surgery and its complications". 6th Edition. Mosby. Pg.no.404-410.
11. Sir Stewart Duke-elder "System of ophthalmology". Vol. XI. Disease of lens and vitreous; glaucoma and hypotony. C.V. Mosby Company. Pg. no.233-248.
12. Miyake K, Asabusa M, Kobayash H. Effect of IOL fixation on blood aqueous barrier. Am.J ophthalmology. 1984; 98:451-455.
13. Zaturinsky B, Naveen N, Sakr D et al. Prevention of PCO by cryolysis and" use of heparinised irrigating solution during ECCE in rabbits. Ophthalmol Surg. 1990; 2(6):431-34.
14. Chen RX, Emery JM, Kretzer F. Mitotic inhibitors in preventing PCO. Current concept in cataract surgery: selected proceedings of 7thbiennial cataract surgical congress, New York, 1982, Appleton-century-crofts. Pg. no 217-224.
15. Zaczekl, Zellerstorm C. PCO after phacoemulsification in patients with diabetes mellitus. J. Cataract Refract Surgery. 1999; 25:1943-49.
16. Suresh K Pandey, David J Apple, Werner L, Anthony J Maloof, Milverton J.A Review of the Aetiopathogenesis, Experimental and Clinical Studies and

- Factors for Prevention. Indian J Ophthalmol 2004; 52: 99-112.
17. Sinskey RM, Lain W. The posterior capsule and phacoemulsification. J Am Intraocular Implant Soc. 1978; 4:206.
 18. Andrew R Elkington, Helena J Frank Micheal J Greaner. "Clinical optics" 3rdEdition. Blackwell science. Pg.no.216-229.
 19. Holladay JT, Bishop JE, Lewis JW. The optimal size of a posterior capsulotomy. Am Intraocular Implant Soc J. 1974; 11:18-20.
 20. Aron-Rosa D, Aron JJ, Grisemann M et al, Use of Nd YAG laser to open the PC after lens implant surgery-a preliminary report. J Am Intraocular Implant Soc. 1980; 6:352-4.
 21. Prajna NV, Ellwein LB, Selvaraj S, Manjula K, Kupfer C. The Madurai Intraocular Lens Study IV: Posterior Capsule Opacification. Am J Ophthalmol 2000; 130:304–309.
 22. Greenidge KC. Nd YAG laser capsulotomy – Energy requirements and visual outcomes. Cataract.
 23. Skolnick KA, Perlman JT, Long DM et al. Neodymium:YAG laser posterior capsulotomy performed by residents. J Cataract Refractive Surg.2000;4:597-601.
 24. Michael J Flohr, Alan L Robin, James S Kelley. Early complications following Q-switched Nd YAG laser posterior capsulotomy. Ophthalmology. 1985; 9:359-62.
 25. Juhas T, Matisova G, Osifova A et al, Neodymium:YAG laser capsulotomy. CeskOftalmol. 1994; 50(1) 45-7.
 26. Pop I, Petroi C, Coroi M et al. secondary cataract treatment with laser YAG Nd. Oftalmologia. 2002; 54(3):68-71.