



## Cardiovascular Manifestations and ECG and ECHO Co-Relations of Scorpion Sting in Children

Authors

Dr J.K. Thaarani Priya<sup>1\*</sup>, Dr R. Ramanathan<sup>2</sup>, Dr E. Balasubramaniyan<sup>3</sup>,  
Dr S. Hari Vasudevan<sup>4</sup>

<sup>1</sup>Post Graduate in Pediatrics in RMMCH, Chidambaram

<sup>2</sup>Associate Professor in Department of Pediatrics, RMMCH, Chidambaram

<sup>3</sup>Senior Resident in Cardiology, Department of Medicine, RMMCH, Chidambaram

<sup>4</sup>Senior Resident in Department of Pediatrics, RMMCH, Chidambaram

### ABSTRACT

Scorpion sting envenomation is a relatively common medical emergency and causes serious health problems in tropical and subtropical regions. Symptomatology and severity of envenomation varies greatly. Scorpion sting may cause myocardial injury and heart failure (HF). Clinical signs of failure may develop several hours or even days after the sting, while electrocardiography (ECG) and blood examination soon after the sting may be normal. Clinical, laboratory, ECG, and ECHO results were checked. Abnormal echo included global hypokinesia and low fractional shortening and ejection fraction of the left ventricle.

**OBJECTIVES:** 1) To study the clinical manifestations 2) To study the various electrocardiographic and echocardiographic manifestations of scorpion sting.

**METHODOLOGY:** This is a prospective study conducted in the Department of Pediatrics, RMMCH during the period of Nov 2014 - Nov 2015. **RESULTS:** A total of 100 cases of scorpion envenomation were included in the study, 68 males and 32 females with majority of cases in 0-5 year age group. 88% reached the hospital within 5 hours. 59% had pain, 72% had tachycardia 28% had profuse sweating. Excessive salivation was seen in 5% and priapism in 18%. ECG changes were present in 72%. ECHO changes were present in 46%.

**CONCLUSION:** Scorpion sting envenomation is a relatively common health problem. Severe cardiopulmonary manifestations like myocarditis, pulmonary edema and severe hypotension are potentially lethal if proper care is not taken.

**KEYWORDS:** Scorpion bite, Clinical spectrum, ECG and ECHO changes.

### INTRODUCTION

Scorpion stings are common in our country, particularly in the rural areas. Among 86 species of scorpions present in India, *Mesobuthus tamulus* (Indian red scorpion) and *Palamnaeus swammerdami* are of medical importance<sup>1</sup>. Though local symptoms including severe pain and burning sensation at the site of the sting are the most

common manifestations, systemic complications can ensue<sup>2</sup>. Cardiovascular manifestations are particularly prominent following stings by the Indian red scorpion<sup>3</sup>. Such bites infrequently have serious clinical sequelae, including myocardial infarction, acute pulmonary edema, cardiogenic shock, and even death.

Cardiac involvement generally occurs as impaired left ventricle systolic function. This impairment contributes to development of pulmonary oedema. The rapid increase of cardiac muscle enzymes and sudden deterioration of cardiac functions after a sting are seen in the acute damage which develops in myocarditis. This acute damage basically triggered by the venom results in adrenergic expression or the direct effect of the toxin on myocardial fibrils. Immediately following a scorpion sting, an autonomic storm is responsible for hypertension, tachycardia, pulmonary oedema, and shock<sup>2</sup>.

**Aim & Objectives**

To study the clinical spectrum with ECG &ECHO findings in children upto 12 years of age admitted in Department of Pediatrics of Raja Muthiah Medical College and Hospital

**Methodology**

**Study Type:** Prospective observational study.

**Source of Data:** 100 children admitted with scorpion sting during the period November 2014 to November 2015 from department of Pediatrics, RMMCH were studied.

**Inclusion Criteria:** All children with definite history of scorpion sting.

**Exclusion Criteria:**

- 1) Children > 12 years
- 2) Children with history of unknown bite
- 3) Children admitted with late complications.
- 4) Place of study:

Department of Pediatrics, RMMCH.

**METHODS**

All children with scorpion sting were subjected to thorough clinical examination, investigations including ECG &ECHO to assess various systemic manifestations. All patients received tetanus toxoid depending on immunization status. Patients were treated with Tablet Prazosin, (except those with hypotension), I.V fluids, diuretics, O2 inhalation and ionotropic supports were given whenever required. The patients vitals were

initially continuously monitored and later once daily till the time of discharge.

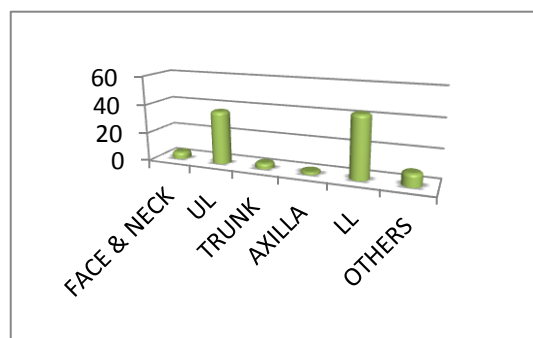
**OBSERVATION & RESULTS**

**Table-1** Age Distribution in <5 Years of Age

AGE	MALE	FEMALE
0-1	18	5
2	10	11
3	12	5
4	7	3
5	2	2
TOTAL	49	26

In this study, 49 patients were male (65%) and female patients were 26 (34.6%). It is found that 3/4<sup>th</sup> percentage of cases of the study population were under 5 years of age.

In this study, 68 patients were males and females contributed to 32 (32%). It is found that scorpion sting were common among males.

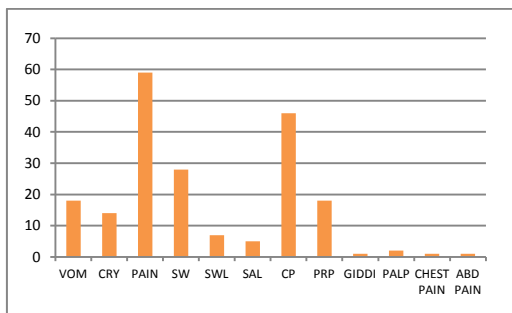


**Fig – 1** Site of Sting in Study Population

In this study, 80% patients were stung over extremities, 4% over Thorax and abdomen and 5% over face.

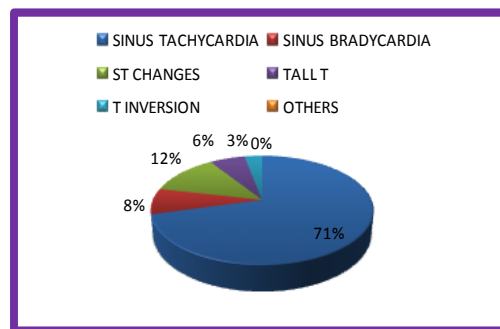
In this study of 100 patients, 59 cases stung by scorpion were in the time 6pm to 12am which explains the nature of scorpions.

In this study 41% of patients received prazosin in <1 hr, 38% of patients received prazosin in 1-2 hrs, 6% in 2-3 hrs, 3% in 4 hrs and 1% in 5hrs.



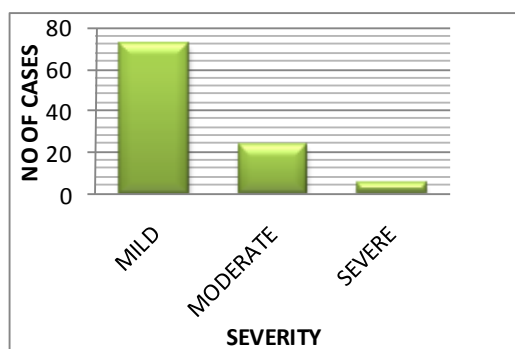
**Fig 2:** Symptoms in Scorpion Sting

In this study, 59 cases had history of pain, 46 cases had cold peripheries, 28 cases had increased sweating, 18 cases had vomiting, 14 cases had cry alone.

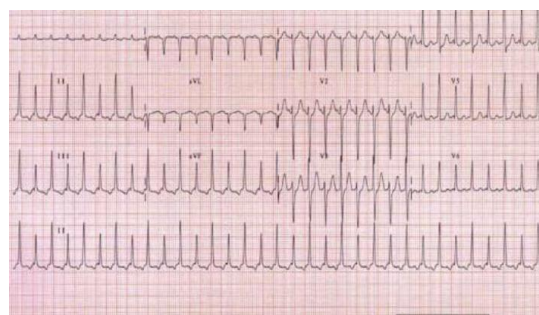


**Fig 5-**ECG Changes

In this study, 72 cases had sinus tachycardia, 8 cases had sinus bradycardia, ST changes in 12 cases, tall T waves in 8 cases and T wave inversion in 3 cases.

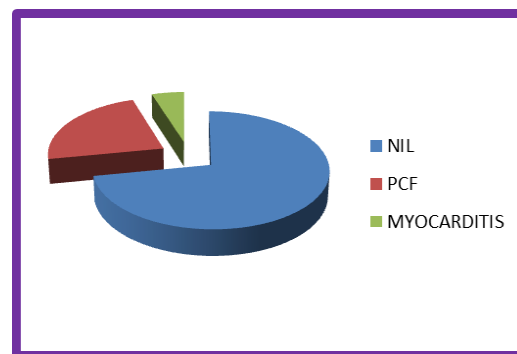


**Fig-3** Severity in Scorpion Sting



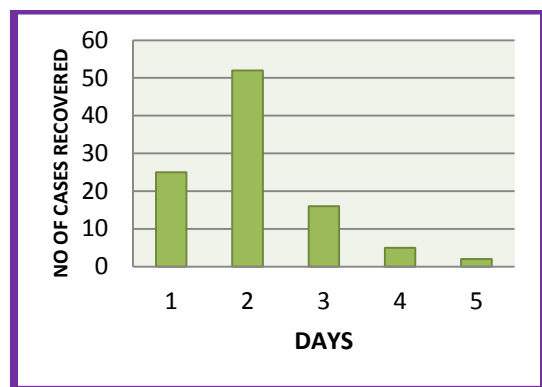
**Fig 6-**ECG – Sinus tachycardia

In this study mild envenomation is noted in 72 cases, moderate in 23 cases and severe envenomation in 5 cases



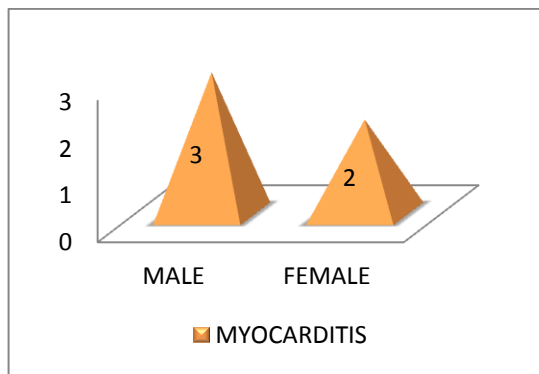
**Fig 7-**Complications

In this study of scorpion sting, 23 cases had peripheral circulatory failure, 5 cases had myocarditis and 72 cases had no complications



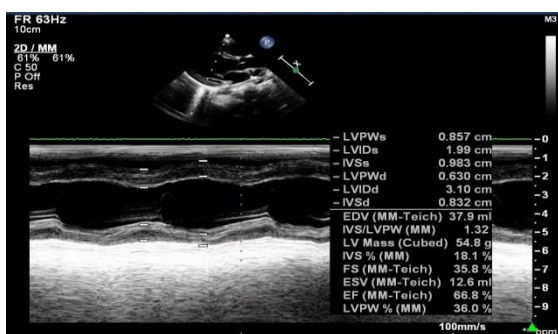
**Fig-4** Recovery Time

In this study, 25 cases recovered within 24 hrs, 52 cases within 2 days, 16 cases within 3 days, 5 cases in 4 days and 2 cases recovered after 5 days.

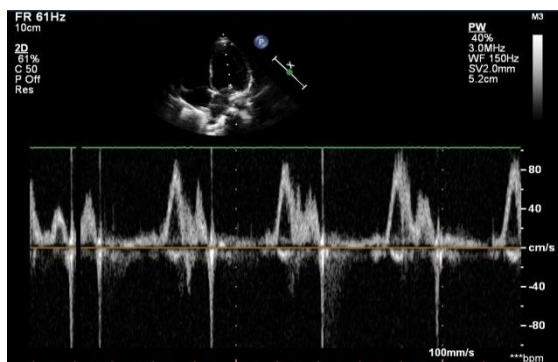


**Fig 8-Incidence of Myocarditis**

In this study, myocarditis were found in 5 % cases in which male child were 60% ( 3 cases) and female child were 40 % ( 2 cases).



**Fig 9: ECHO showing LV systolic dysfunction**



**Fig 10: ECHO showing mild MR**

**DISCUSSION**

**Age Distribution**

In our study, proportion of cases of 0-5 years, 5 to 10 years, more than 10 years are 75%, 22% and 3% respectively and 3/4<sup>th</sup> of the patients were under 5 years of age.

**Sex Distribution**

In our study, there was a male preponderance (68%). Jahan et al also reported a male / female ratio of 1.9:1<sup>14</sup>.

**Site of Sting**

In our study, the sting sustained on the upper limb was 37%r limb & 43% on the lower limb i.e on the extremities. In a study by Bashir M. Jarrar in 2008 scorpion stings were common in extremities, upper limb (36%) & lower limb (51%).

**Time of Scorpion Sting**

Majority (59%) of the patients had sting during 6 pm to 12 am which explains the nocturnal habitat of scorpions.

**Presenting Symptoms**

Pain at the sting site was the commonest complaint noted (59 cases) & was invariably present in all the cases. Incessant cry was the only presenting complaint in 14 cases. Cold peripheries were noted in 46 cases, sweating in 28 cases, vomiting in 18 cases, priapism in 18 cases in our study, but cold peripheries seen in 81.81% in children according to S.Das et al<sup>2</sup>.

Fevzi Yilmaz et al in 2009 also found that local pain was the most common presenting symptoms in patients with scorpion sting (95%).

**Pre-Admission Treatment & 1<sup>st</sup>Referral Duration:**

In our study, 65 cases were given Inj.TT and 26 cases were treated with T.Prazosin before reaching our hospital and 41% received prazosin in less than 1 hour, 38 % received prazosin in 1- 2 hours, 3% cases in 4 hours & 1 % received prazosin in 5 hours.

**Month wise Distribution of Cases**

In our study, 36% cases were in the month of Feb and Mar (late winter & early spring) and 20% were in the month of Aug and Sep (late summer and early autumn).

**Severity of Envenomation**

In our study, 72% patients had mild envenomation, 23% had moderate envenomation and 5% had severe envenomation.

**Investigations**

Hyperglycemia is noted in 63 cases, elevated CK MB in 12 cases and abnormal amylase in 6 cases. In ECG, sinus tachycardia were noted in 71% cases, ST changes in 12% & T wave changes in 33 cases whereas in a study conducted by

Sashidhar G et al 60 patients had ECG changes<sup>11</sup>. ECHO showed sinus tachycardia in some cases whereas myocarditis was observed in 5% cases (male -3, female-2).

#### Recovery Time

In our study, 25 cases recovered within 24 hours, 52 cases recovered within 2 days, 16 cases in 3 days, 5 cases in 4 days & 2 cases after 5 days. No deaths were reported in our study population.

#### DISCUSSION

Scorpion<sup>10</sup> venom can cause myocardial damage by several pathogenetic mechanisms:-

Myocardial ischaemia by coronary spasm: Release of vasoactive, inflammatory and thrombogenic peptides and amine constituents (histamine, serotonin, bradykinin, leukotrienes, thromboxane), which act on the coronary vasculature and induce coronary artery vasospasm and facilitate platelet aggregation as well as thrombosis<sup>8</sup>

The unopposed effects of alpha-receptor stimulation lead to myocarditis.

Direct cardiotoxic effect of the venom causing toxic myocarditis by reduction of Na-K<sup>+</sup> ATPase and adrenergic myocarditis by releasing adrenaline and noradrenaline thereby increasing myocardial oxygen demand by direct inotropic and chronotropic effect<sup>9</sup>.

Anaphylactic reaction: Release of allergenic proteins causes anaphylactic shock.

Scorpion venom inhibits angiotensin converting enzyme (ACE), resulting in accumulation of bradykinin, which is implicated in the development of pulmonary oedema<sup>10</sup>.

ECG is an important investigation which helps in the diagnosis of fatal conduction disturbance, ischaemia and very importantly myocarditis<sup>15</sup>.

**ECHOCARDIOGRAPHY-** helps to detect left ventricular systolic dysfunction. The findings may be 1. Left ventricular dilatation 2. Regional wall motion abnormalities 3. Decreased left ventricular ejection fraction<sup>15</sup>.

#### CONCLUSION

Scorpion stings are frequently seen in our country and the stings of scorpions living in some regions may be fatal. Although cases of scorpion stings are generally seen with simple local findings, it must be remembered that serious cardiovascular impairments, such as acute myocarditis, acute heart failure, and acute pulmonary oedema, may occur. Particularly in cases with high levels of cardiac enzymes, it must be kept in mind that myocarditis can develop and the patients should be evaluated in this regard.

#### REFERENCES

1. Bahloul M, Ben Hamida C, Chtourou K, Ksibi H, Dammak H, Kallel H, et al. Evidence of myocardial ischaemia in severe scorpion envenomation. Myocardial perfusion scintigraphy study. *Intensive Care Med.* 2004; 30(3):461–7.
2. Bhadani UK, Tripathi M, Sharma S, Pandey R. Scorpion sting envenomation presenting with pulmonary edema in adults: a report of seven cases from Nepal. *Indian J Med Sci.* 2006;60(1):19–23.
3. Cupo P, Figueiredo AB, Filho AP, Pintya AO, Tavares Junior GA, Caligaris F, et al. Acute left ventricular dysfunction of severe scorpion envenomation is related to myocardial perfusion disturbance. *Int J Cardiol.* 2007; 116(1):98–106.
4. Gaitonde BB, Jadhav SS and Bawaskar HS. Pulmonary edema after scorpion sting. *Lancet* 1978; 2:445-46.
5. Bawaskar HS and Bawaskar PH. Prazosin in management of cardiovascular manifestations of scorpion sting. *Lancet*; 2:510-11.
6. Bawaskar HS and Bawakar PH. Efficacy and safety of scorpion antivenom plus prazosin compared with prazosin alone for venomous scorpion (*Mesobuthus tamulus*) sting: randomized open label clinical trial. *British Medical Journal* 2010;341: c7136doi10.1136/bmj.c7136.

7. Bahloul M, Chabchoub I, Chaari A, Chatara K, Jallel H, Dammak H, Ksibi H, Chelly H, Rekik N, Ben Hamida C, and Bouaziz M. Scorpion envenomation among children: clinical manifestations and outcome (analysis of 685 cases). *Am J Trop Med Hyg* 2010; 83:1984-1092.
8. Ho-Pang Yang, Fu-Chung Chen, Chien-Cheng Chen *et al.* Manifestations Mimicking Acute Myocardial Infarction after Honeybee Sting. *Acta Cardiol Sin* 2009; 25: 31-5.
9. Rahav G, Weiss T. Scorpion sting induced pulmonary oedema. Scintigraphic evidence of cardiac dysfunction. *Chest* 1990; 97:1478-80.
10. Bawaskar HS, Bawaskar PH. Management of scorpion sting. *Heart* 1999; 82: 253-4.
11. Shashidhar G, Lokesh S, Aravind . “A Clinical Spectrum of Scorpion Sting at Vijayanagar Institute of Medical Sciences, Bellary”. *Journal of Evolution of Medical and Dental Sciences* 2014;Vol.3, Issue 57, Oct 30; page 12961-12970,DOI: 10.14260/jemds/2014/3720.
12. Das S, Nalini P, Ananthkrishnan S, et al: Scorpion envenomation in children in southern India. *J . Trop. Med. Hyg*, oct 1995; 98(5): 306-308.
13. Bawaskar HS. Diagnostic cardiac Premonitory signs and symptoms of red scorpion sting. *Lancet* 1982; 2:552-54.
14. Jahan S, Mohammed Al Saigul A, Abdul Rahim Hamed S. Scorpion stings in Qassim, Saudi Arabia-a-5 year surveillance report. *Toxicon* 2007; 50:302-5
15. Joshi SR, Sapatnekar SM. Stings and Hopes: Toxonomics and Autonomic storm in the Indian Red Scorpion (*Mesobuthus tamulus concanensis pocock*) *J Assoc Physicians India* 2007; 55:11.