



## Detection of a Tertiary Pattern of Higher Grade in Core Biopsy Tissues of Prostatic Adenocarcinoma– A Case Report

Authors

Ashok Kumar Kapoor,\*Mustafa Ali, Yamini Jindal

### ABSTRACT

*Present study relates with the results of histopathological examination of core biopsy tissue from a patient with prostatic adenocarcinoma. Adenocarcinoma was graded according to Gleason's criteria into 5 grades (grade 1 to 5) with decreasing differentiation. Histopathological classification of tumour mainly depends upon architectural irregularities with increasing anaplasia. At least 2 patterns are recognized in a prostatic carcinoma. In addition, most prevalent grade is added with second most common grade to obtain a Gleason score.*

**KEY WORDS:** Adenocarcinoma Prostate Gleason tertiary pattern.

### INTRODUCTION

Gleason's grading system<sup>1</sup> depends upon architectural alterations which may occur in a biopsy specimen of a prostatic adenocarcinoma. According to Gleason's criteria, prostate cancer can be classified into 5 grades (grade 1 to 5) with decreasing differentiation. Architectural changes are also associated with increasing anaplasia. Prostatic adenocarcinoma appears to be multicentric. At least 2 grades or patterns are recognized in a tumour. Most prevalent grade or pattern is added with second most common pattern to obtain a Gleason score (GS)<sup>2</sup> or sum. Prognosis of a prostate cancer directly correlates with GS. For example, a tumour with relatively low score (GS 2 to GS4) are graded as well-differentiated tumour. Tumour with GS 5 to GS 7 is graded as moderately differentiated. A tumour with GS 8 to GS10 is graded as poorly differentiated. The international society of

urological pathology Gleason grading system was modified in 2005. Since the introduction of a modified system<sup>2</sup>, many cancers that were previously scored as GS 6 were later revised as GS 7 based on biopsy specimens that contained minimal amount (< 6%) of tertiary Gleason pattern. It has been observed that the prognosis of a tumour is worse if 3 or more grades are seen when compared with another tumour with similar score having 2 patterns alone. Here, we describe a tumour with additional tertiary grade.

### CASE REPORT

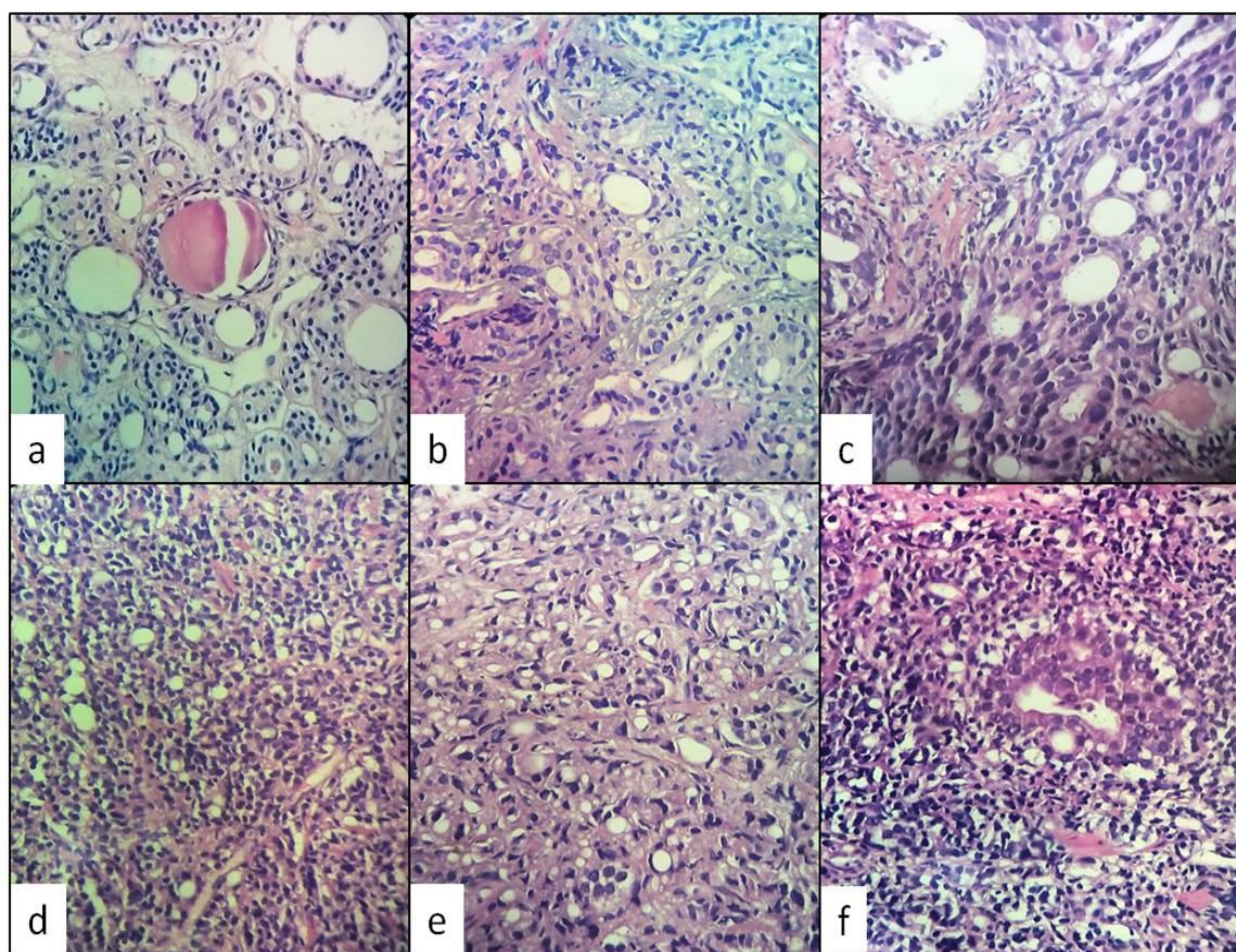
Eighty years old patient presented with acute retention of urine. Digital rectal examination revealed nodular swellings in prostatic lobes. Core biopsy pieces were obtained from both the lobes using trucut biopsy needle. Seven pieces were obtained from right lobe and 5 pieces were obtained from left lobe. Pieces were fixed in 10%

formalin in buffered saline and paraffinized blocks were sectioned and stained by HE method. Histopathological examination revealed a diagnosis of adenocarcinoma. Primary or most prevalent pattern was grade 2 tumour which showed excessive proliferation of malignant glands and scanty stroma (Figure 1a). Second most common pattern was grade 4 tumour which showed fused malignant glands (Figure 1b) and cribriform carcinoma (Figure 1c). According to Gleason criteria its Gleason score was  $2+4 = 6$ . Third small tertiary pattern ( $< 10\%$  of tumour)

was poorly differentiated grade 5 tumour (Figure 1d).

Results of histopathological examination revealed 3 patterns. Presence of an additional minor pattern (Figure 1e) might adversely affect the prognosis of this case because of higher grade of tertiary pattern as compared to primary and secondary patterns.

Most of the tumour tissue did not show lymphocytic infiltration. However, at few places, dense lymphocytic infiltration was seen (Figure 1f).



**Figure 1:** (a) Gleason's grade 2 pattern showing excessive proliferation of malignant glands and scanty stroma. (b) Gleason grade 4 tumour showing fused malignant glands.(c) Gleason grade 4 pattern showing cribriform appearance. (d) Third small tertiary pattern ( $< 10\%$  of tumour) showing poorly differentiated Gleason's grade 5 pattern.(e) Another area showing tertiary pattern. (f) Photomicrograph showing dense lymphocytic infiltration of tertiary tumour tissue.

## DISCUSSION

Several reports have appeared in literature which suggest that 3 or >3 grades in a prostate cancer may adversely affect the prognosis of adenocarcinoma<sup>3</sup>. In another study<sup>4</sup> 466 cases of prostatic adenocarcinomas with multiple grades were studied. A tertiary Gleason pattern 5 was present in 24.2% of patients with a Gleason score of < 9; in 12.2% of patients with a Gleason score of 3+4 and in 45.9% of patients with a Gleason score of 4+3. One hundred and eighty seven patients had any rate of Gleason pattern 5 and significantly worse pathological factors compared with patients who did not have this pattern<sup>4</sup>. Clearly, multiple grades (3 or >3); tertiary grade being of higher grade than previous grades appeared to adversely affect the outcome of the patients with prostatic cancer. Tertiary pattern 5 remained a strong prognostic factor imparting a 1.8-fold increase in the risk of biochemical recurrence<sup>5</sup>.

Another interesting finding of the current study was the lack of lymphocytic infiltration of most of primary malignant tumour tissue. It appeared that either tumour cells were not expressing tumour associated antigens (TSA) or TSA were covered by blocking factors. These possibilities might have down-regulated T-cell stimulation resulting in anergy<sup>6</sup>. However, at few places dense lymphocytic infiltration and lysis of tertiary grade tumour cells was seen, suggesting development of tumour rejection type of response (Immunity).

Another important histological prognostic factor is perineural invasion (PNI)<sup>7</sup>. PNI also correlates with periprostatic invasion<sup>8</sup>. However, in the current study PNI as well as vascular and periprostatic invasions were not seen.

High-grade prostatic intraepithelial neoplasia (PIN) is believed to be a premalignant lesion<sup>9, 10</sup>. However, in the current study high-grade PIN was seen at few places.

## CONCLUSION

Histopathological examination of prostatic core biopsy specimens from a case of prostatic

adenocarcinoma revealed a Gleason score of 2+4 = 6. Moreover, an additional tertiary pattern (< 10% of tumour mass) was found. Tertiary pattern of higher grade may adversely affect the prognosis of a case of prostatic adenocarcinoma.

**Financial support and sponsorship:** Nil

**Conflicts of interest:** There are no conflicts of interest

## REFERENCES

1. Humphrey PA. Gleason grading and prognostic factors in carcinoma of the prostate. *Modern Pathol* 2004; 17:292-306.
2. Kir G, Senelder H, Gumus E. Outcomes of gleason score 3+4 = 7 prostate cancer with minimal amounts (< 6%) Vs  $\geq$  6% of Gleason pattern 4 tissues in needle biopsy specimens. *Ann Diagn Pathol* 2015; 20:48-51.
3. Montironi R, Mazzucheli R, Scarpelli M, Lopez-Beltran A, Fellegara G, Algaba F. Gleason grading of prostate cancer in needle biopsies or radical prostatectomy specimens contemporary approach, Current clinical significance and sources of pathology discrepancies. *BJU international* 2005; 95:1146-1152 (doi:10.1111/J.1464-410 x 2005.05540 x).
4. Hashima K, Yuasa A, Sinomori K, Shirato A, Ninomiya I, Teramoto N. Tertiary Gleason pattern 5 and oncological outcomes after radical prostatectomy. *Japanese J Clin Oncol* 2011; 41:571-576.
5. Koloff ZB, Hamstra DA, Wei JT, Montgomery JS et al. Impact of tertiary Gleason pattern 5 on prostate cancer aggressiveness: Lessons from a contemporary single institution radical prostatectomy series. *Asian J Urol* 2015; 2:53-58.
6. Greenberg PD, Mechanisms of tumour immunology. In Parslow TG, Slites DP, Terr AI, Imboden JB eds. *Medical immunology* 10<sup>th</sup>ed. New York: Lange



medical books / McGraw-Hill publishing division: 2001, p568-571.

7. Montie JE, Wood DP, Pontre JE, Boyett JM, Levin HS. Adenocarcinoma of the prostate in cystoprostatectomy specimens removed for bladder cancer. *Cancer* 1989; 63:381-385.
8. Ismar TA, Lewis JS jr, Vollmer RT, Humphrey PA. Multiple measures of carcinoma extent versus perineural invasion in prostatic needle biopsy tissue in prediction of pathologic stage in a screening population. *Amer J SurgPathol* 2003; 27:432-440.
9. Damjanov I, McCue PA. In situ and invasive adenocarcinoma of the prostate. In Rubin's Pathology, 7<sup>th</sup> ed. Strayer DS, Rubin E, Saffiz JE and Schiller AL 2015; Philadelphia : Wolters Kluwer p990-994.
10. Kim HL, Yang XJ. Prevalence of high-grade intraepithelial neoplasia and its relationship to serum prostate specific antigen. *IntBraz J Urol* 2002; 28:413-417.