



A Study on Variations of Levator Palpebrae Superioris Muscle with Its Embryological Basis and Clinical Significance

Authors

Dr Gopal Bagal^{1*}, Dr Savita Takale²

¹Associate Professor, ACPM Medical College, Dhule, Maharashtra, India-434002

²Associate Professor, CSMSS, Ayurvedic Medical College, Aurangabad, Maharashtra, India-434000

Corresponding Author

Dr Gopal Bagal

Associate Professor, Dept of Anatomy, ACPM Medical College, Sakri Road, Dhule, Maharashtra, India-434001

Email: drgopalbagal@gmail.com

ABSTRACT

The human beings are a highly species. Most of our information about the world comes to us through our eyes and most of our cultural and intellectual heritage is stored and transmitted as words and images to which our vision gives access and meaning. Knowing more about our eyes and vision is, therefore, one path to better understanding of ourselves.

The extraocular muscles are pivotal to the movement of the eye. There are 7 muscles within the orbit: 4 rectus muscles, 2-oblique muscles and the levator palpebrae superioris. Abnormalities of the extraocular muscles are rare and most accounts describe unilateral or bilateral absence of individual muscles. Numerical aberrations of extraocular muscles are commonly associated with syndromes of premature cranial bone stenosis. Although many variations of the levator palpebrae superioris muscle have been reported in fetuses. Accessory muscle slips may be associated with congenital eyelid retraction or blepharoptosis. Because of the clinical importance of the accessory levator muscle slip of the levator palpebrae superioris muscle, this study aimed to describe the morphological appearance of this variation in human adult orbits.

Keywords: *Accessory levator muscle slip, blepharoptosis, extraocular muscles, eyelid retraction, levator palpebrae superioris.*

INTRODUCTION

The levator palpebrae superioris (LPS) muscle is a thin, triangular muscle; it arises from the inferior aspect of the lesser wing of the sphenoid. It has a short narrow tendon at its posterior attachment. The muscle ends anteriorly in a wide aponeurosis with some of its tendinous fibres passing directly into the upper eyelid to attach to the anterior surface of the tarsus. The remaining fibres

radiated and pierced the orbicularis oculi to pass to skin of the upper eyelid ⁽¹⁾.

Abnormalities of the extraocular muscles are rare and most accounts describe unilateral or bilateral absence of individual muscles. Variations of the Levator palpebrae superioris muscle in adults and fetuses have been reported as follows;

1. Complete absence of the Levator palpebrae superioris muscle.

2. The Levator palpebrae superioris muscle having a unilateral accessory levator muscle slip parallel to the superior oblique muscle.
3. The Levator palpebrae superioris muscle exhibiting a divided main belly forming a retrobulbar muscular arch.
4. Slender accessory levator muscle slips from the medial and lateral margins of the LPS.
5. Small fibrous bands reinforcing the medial margin of the LPS muscle and replacing accessory levator muscle slips ^(2,3).

Accessory levator muscle slips may be associated with congenital eyelid retraction or blepharoptosis ⁽⁴⁾. Nevertheless, congenital retraction of the upper eyelid is a poorly defined entity about which little is known.

Variations in the rectus and oblique muscles have been described in studies which date back to 1893 in which an anomalous rectus muscle was found arising with and medial to lateral rectus ⁽⁵⁾. The variations of the rectus muscles are thought to be remnants of the retractor bulbi, responsible for preventing the protrusion of the eyeball in most mammals, amphibians and certain reptiles ⁽⁶⁾.

Anatomical variations found in the previous studies are;

1. A supernumerary rectus muscle between the inferior rectus and lateral rectus,
2. A tripartite inferior rectus with a lateral muscle belly inserting into the inferior oblique,
3. A medial muscle belly inserting medially into the inferior rectus.

Numerical aberration of the extraocular muscles are commonly associated with syndromes of premature cranial bone stenosis, notably craniofacial dysostosis (Crouzon's disease), acrocephalosyndactyly (Apert's syndrome), and oxycephaly.

Although many variations of the levator palpebrae superioris muscle have been reported in fetuses, investigations and demonstrations of these may be

more important in children and adults for ophthalmic surgery. We believe that detailed knowledge regarding the morphological appearance of an accessory levator muscle slip of the levator palpebrae superioris may be useful for successful outcomes in ophthalmic surgery.

MATERIAL AND METHODS

This study has been carried out in the department of anatomy of a reputed medical institution. The unclaimed cadavers which the department received were used for present study. A total of 100 eyes were dissected (100 orbits of 50 embalmed adult human cadavers, 33 male and 17 female, between the ages of 40 to 80 yrs) at death, and observation recorded after meticulous dissection of the orbits in a stepwise manner. All the cadavers were registered with the department of Anatomy.

The cadavers were embalmed in 4% formalin solution. None of them showed any macroscopic pathological changes to the orbits. The cause of death was unrelated to the ophthalmic region and organs of the head and neck, which were carefully examined to ensure that there were no signs of trauma, deformities, tumours or significant volume loss. The orbit was dissected from above. The orbital plate of the frontal bone was fractured by chiseling, and the roof of the orbit removed with a rongeur, care being taken to preserve the periorbita. The skin and tissue overlying the superior rim of the orbit was removed in block. The superior bony orbital margin was then removed by making two vertical cuts through it. The bone between the two incision was freed from the underlying structures. The periorbita was opened, care being taken not to damage the frontal nerve, and the orbital fat was removed piecemeal to expose the superficial structures of the orbit.

OBSERVATION AND RESULTS

Macroanatomically, the roof of the orbit and periorbita appeared to be normal in all specimens. The LPS muscle did not exhibit accessory levator muscle slips in 98 of 100 orbits.

The following description relates two male cadavers in which an additional muscle was noted in the superior part of the orbit, medial to and in the same plane as, the levator palpebrae superioris muscle, parallel to superior oblique muscle. It was present unilaterally in both cadavers, when the muscle belly was pulled on with a pair of forceps,

the upper eyelid was elevated; this movement was more marked on the medial part of the eyelid. There was no evidence of cranial malformation nor of previous orbital or eyelid surgery. The four recti as well as the superior and inferior oblique muscles were normal.

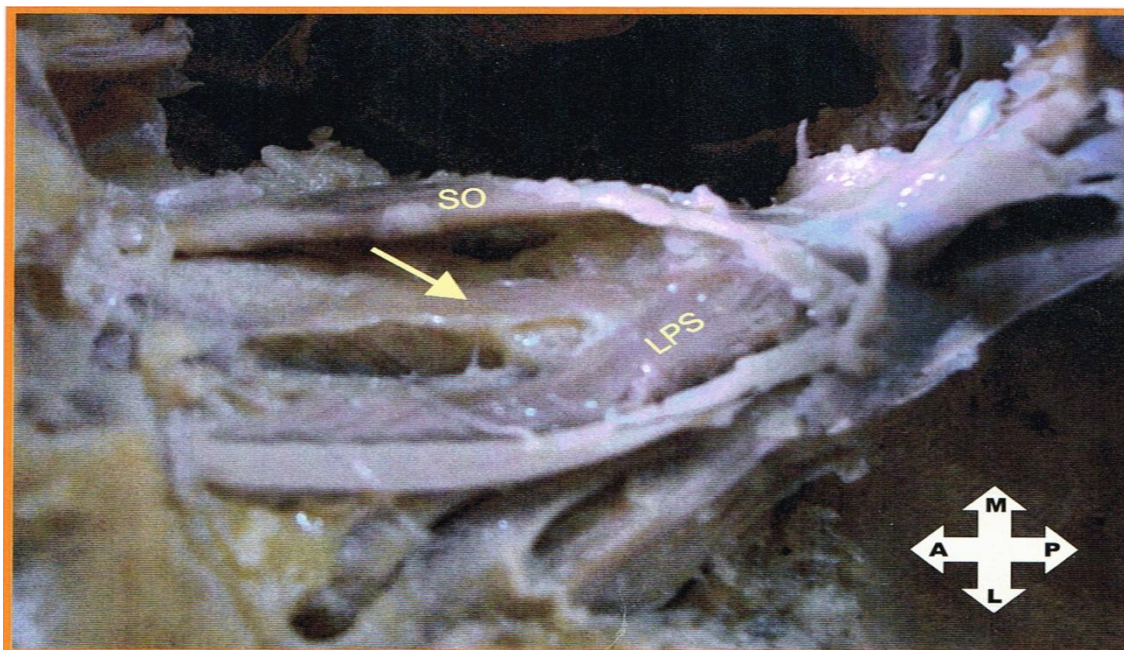


Figure 1. Illustration showing the muscular slip (arrow) between the Levator palpebrae superioris(LPS) and Superior oblique (SO) in left eye.



Figure 2. Illustration showing the muscular slip (arrow) between the Levator palpebrae superioris(LPS) and Superior oblique (SO) in right eye.

In two cadavers, variations in the extraocular muscle was seen. In one cadaver it was in the left eye while in other it was in right eye. In both these cadaver, there was a muscular slip 2-3 mm width, arising from the apex of the orbit close to the origin of the levator palpebrae superioris and superior rectus muscle. It was running anteriorly and slightly medially parallel to the superior oblique muscle. Anteriorly it was inserted into the fibrous tissue of the orbit. This muscular slip was supplied by superior division of the oculomotor nerve in both cadavers. After going through the literature it was found that the congenital anomalies in the extraocular muscles are rare, but the muscular slip from the margins of the levator palpebrae superioris occur quite frequently i.e. in 8 – 15 % of cases ⁽⁷⁾.

Such muscle is also called as the levator or tensor trochleae or gracillimus muscle ⁽⁸⁾. Such an anomaly of levator palpebrae superioris muscle was first described by Vesalius.

DISCUSSION

An accessory levator muscle slip of the LPS muscle occurs in 8-15% of cases. This variation was found to be present in 4 % of our cases. Accessory levator muscle slips have been described unilaterally or bilaterally in 70% of fetuses. These variations originated either from the medial edge of the LPS muscle or separately from the common tendinous ring. They appeared in various forms;

1. Small short slips,
2. Constant long thin muscles,
3. Or muscles with an anterior enlargement.

The apparent lack of previous reports of this muscle in lower animals make it unlikely that it is vestigial. Yapp (1965) showed that lower vertebrates had six extraocular muscles, homologous to human extrinsic eye muscle as well as mobile eyelids, but did not possess levator palpebrae superioris muscle ⁽⁸⁾. Holmes (1975) confirmed the accounts of Yapp in fish, amphibia, reptiles, birds and quadruped mammals. William et al. (1995) suggested that LPS was a

phylogenetically new muscle, formed as a later delamination from the superior rectus muscle to serve the upper eyelids in the higher tetrapods. The weight of comparative anatomical evidence, therefore appears to rule out the possibility that the levator palpebrae superioris accessorius is a vestigial muscle.

Amonoo-Kuofi and Darwish (1998) reported bilateral accessory LPS muscle between superior oblique and LPS that ran from the lesser wing of the sphenoid to the skin of the upper lid, but these muscle were not bipartite ⁽⁹⁾. Fetal LPS exhibit a broad aponeurotic insertion on the upper lid and the connective tissue of the lacrimal gland, often with medial and lateral accessory muscular slips or fibrous bands arising from LPS (Plock et al. 2005) ⁽¹⁰⁾. Changes during embryogenesis upto 24 months postnatally may result in LPS undergoing adaptation ⁽¹¹⁾.

Ettl et al. (1998) reported a delicate superior transverse fascial expansion present between the trochlea and the lacrimal gland in the embryo and is represented by anterior aponeurotic sheath of the superior rectus and LPS in adults ⁽¹²⁾. Loukas (2006) reported a bilateral lateral bipartite LPS muscle ⁽¹³⁾. The right and left LPS muscle received a broad accessory levator muscle slip originating from the greater wing of the sphenoid to form a retrobulbar arch.

In another report by Ludinghausen et al., the LPS muscle was found to have a unilateral accessory levator muscle slip parallel to the superior oblique muscle in a adult ⁽²⁾. Variations of the LPS may also cause congenital blepharoptosis. This pathological condition usually occurs as an isolated defect in otherwise healthy children, although it may associated with craniofacial malformation and ocular motility disorder ⁽¹⁴⁾.

Because of the similarity of such accessory levator muscle slips to large orbital vessels on magnetic resonance imaging or computed tomography scans, the presence of abnormal extraocular muscles might be misinterpreted although, with the advent of newer imaging techniques, fine structures such as the levator aponeurosis,

superior tarsal muscle (Muller muscle) and components of the connective tissue system may be observed ⁽¹⁵⁾.

EMBRYOLOGY

The extrinsic ocular muscles develop from three pre-otic somites ⁽¹⁶⁾, while their connective tissue components are derived from neural crest cells. Gilberts (1952) showed that these extraocular muscles innervated by the oculomotor nerve developed from the most rostral of the three, the premandibular somite which is formed from mesoderm originating in the prechordal plate. Superior rectus muscle appeared on the 24th day of gestation where as medial and inferior recti and inferior oblique muscles were formed between the 28th and 30th day of gestation. LPS was the last muscle to form, appearing early in the 8th week by delamination from medial aspect of superior rectus muscle ⁽¹⁷⁾. The oculomotor nerve reached the vicinity of the developing eye early in the 5th and quickly innervated these muscles. All skeletal muscle formation is completed by mid-fetal stage and their innervation established by the 15th week of gestation.

CONCLUSION

In our study, we showed the morphological appearance of two accessory levator muscle slips in 100 orbits. It is known that the LPS muscle raises the upper eyelid but during this process, the lateral and medial parts of its aponeurosis are stretched and thus limit its action. Because of that, abnormal structure such as accessory levator muscle slip may effect position of the eyelid and cause its disfunction. Although many variations of the LPS muscle have been reported in fetuses. Investigations and demonstration of these may be more important in children and adults for ophthalmic surgery. We believed that detailed knowledge regarding the morphological appearance of accessory levator muscle slips of LPS muscle may be useful for successful outcomes in ophthalmic surgery.

REFERENCES

1. Ruskell GL. Accessory visual apparatus. In: Williams PL, ed. Gray's Anatomy, 38th edn. New York: Churchill-Livingstone; 1995: 1353.
2. Von Ludinghausen M, Miura M, Wurzler N. Variations and anomalies of the human orbital muscles. Surg Radiol Anat. 1999; 21: 69-76.
3. Plock J, Contaldo C, Von Ludinghausen M. Levator palpebrae superioris muscle in human fetuses: anatomical findings and their clinical relevance. Clin Anat. 2005; 18: 473-80.
4. Ballen PH, Rochkopf. Congenital retraction of the upper lid. Ophthalmic Surg. 1987; 18: 680-690.
5. Edward R. Extraocular muscles: variations in their anatomy, length and cross sectional diameter. Int J Anat and Research. 2015; 3(3): 1198-1206.
6. Carruthers JD. Strabismus in craniofacial dysostosis. Clin Exp Ophthalmol.1988; 226: 230-234.
7. Whitnall SE. An instance of the retractor bulbi muscle in man. J of Anatomy and Physiology. 1911; 46: 36-40.
8. Yapp WB. Sense organs, In Vertebrates: Their structure and Life. New York: Oxford University Press. 1965: 279-321.
9. Amonoo-Kuofi HS, Darwish HH. Accessory levator muscle of the upper eyelid: A case report and review of the literature. Clin Anat. 1998;11: 410-416.
10. Plock J, Contaldo C, Von Ludinghausen M. Extraocular eye muscles in human fetuses with craniofacial malformation: anatomical findings and their clinical relevance. Clin Anat. 2007; 20: 239-245.
11. Sevel D. Development of the connective tissue of the extra ocular muscles and clinical significance. Clin Exp Ophthalmol. 1988; 226: 246-251.
12. Ettl A, Priglinger S, Kramer J. Functional anatomy of levator palpebrae superioris

- muscle and its connective tissue system.
Br J Ophthalmol. 1996; 80: 702-707.
13. Loukas M, Curry B. Bilateral lateral bipartite levator palpebrae superioris muscle. Clin Anat. 2006; 19: 698-699.
 14. Plock J, Contaldo C, Von Ludinghausen M. Extraocular eye muscles in human fetuses with craniofacial malformation: anatomical findings and clinical relevance. Clin Anat.: 2007; 20: 239-245.
 15. Hoffman KT, Hosten N, Lemke AJ, Sander B. Septum orbitale: high resolution MR in orbital anatomy. Am J Neuroradiol. 1998; 19: 91-94.
 16. Neal HV. The history of eye muscles. J Morphol. 1918; 30: 433-453.
 17. Gilbert PW. The origin and development of the head cavities in the human embryo. J Morphol. 1952; 90: 149-187.