



Abnormal Origin of Common Hepatic Artery-A Case Report

Authors

**Dr Sarita Behera¹, Dr Bijaya Kumar Dutta², Dr Mamata Sar³,
Dr Manoj Kumar Dehury⁴**

¹Senior Resident/Tutor, Department of Anatomy, V.S.S. Institute of Medical Science & Research, Burla, Sambalpur, Odisha, India

Email: drsaritabehera81@gmail.com

²Professor & H.O.D, Department of Anatomy, V.S.S. Institute of Medical Science & Research, Burla, Sambalpur, Odisha, India

Email: dutta.b71@gmail.com

³Associate Professor, Department of Anatomy, V.S.S. Institute of Medical Science & Research, Burla, Sambalpur, Odisha, India

Email: mamatasar@gmail.com

⁴Senior Resident/Tutor, Department of Anatomy, V.S.S. Institute of Medical Science & Research, Burla, Sambalpur, Odisha, India

Email: dr.mkdehury@gmail.com

ABSTRACT

Common hepatic artery normally arises as a branch of coeliac trunk, which is one of the median splanchnic branches of the abdominal aorta. During routine dissection classes of first MBBS students, we observed a variation in the origin of common hepatic artery in a 50 years male cadaver where, it was found to be arising from the superior mesenteric artery instead of coeliac trunk. After its origin, the course, relations and branches were normal. Other two branches of the celiac trunk namely left gastric and splenic were normal in their origin. Surgical mistakes from failing to appreciate hepatic artery anatomy continue to be made with serious consequences to the patient with medico-legal implications. Though vascular variations of the splanchnic branches of abdominal aorta are frequently reported, this particular case will certainly throw some light for safe surgery and low morbidity in hepatobiliary surgery.

Keywords- common hepatic artery, celiac trunk superior mesenteric artery

INTRODUCTION

Coeliac trunk, which is one of the median splanchnic branches of the abdominal aorta normally gives rise to three branches namely common hepatic, left gastric and splenic arteries to supply the derivatives of the foregut. Liver and gall bladder derive their blood supply from the branches of common hepatic artery. Variations are frequently

observed in the anatomy of common hepatic artery which should be kept in mind during surgical and radiological interventions.

CASE REPORT

During routine dissection classes of first MBBS students, some variations in the branching pattern of the median splanchnic branches of Abdominal aorta

were observed in a 50 year old male cadaver. The three median splanchnic branches of Abdominal aorta, namely coeliac trunk, superior mesenteric artery and inferior mesenteric artery were found to be arising at their normal vertebral levels. Coeliac trunk divided into 2 branches i.e left gastric and splenic artery. The left gastric artery was found to be ascending up to the esophagus and descending down along the lesser curvature of stomach. The splenic artery followed its usual course along the upper border of pancreas up to the splenic hilum. The common hepatic artery was found to be arising from superior mesenteric artery. It was running behind the neck of pancreas and 1st part of duodenum to give the gastroduodenal branch and then entered the free margin of lesser omentum as proper hepatic artery. The proper hepatic artery maintained its normal relation with the bile duct and portal vein and terminated by dividing into right and left hepatic arteries. Right hepatic artery was found to give the cystic branch to gall bladder.

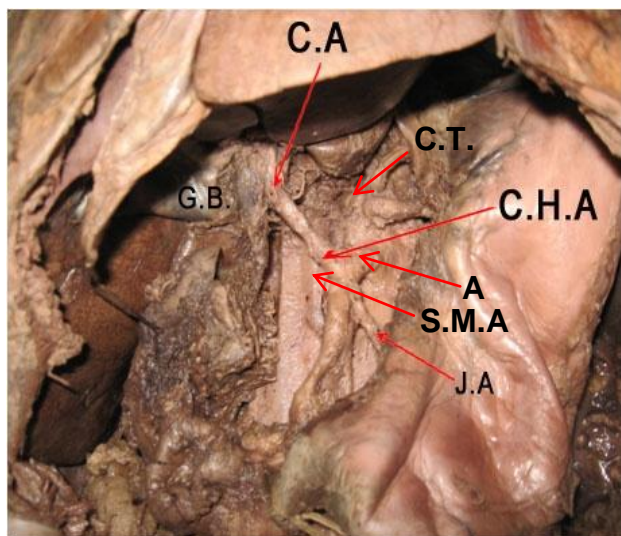


Fig 1: Photograph showing origin of common hepatic artery from superior mesenteric artery. (C.T=Coeliac trunk S.M.A=superior mesenteric artery, A=Abdominal aorta, C.H.A=Common hepatic artery, J.A.= Jejunal artery, C.A.- Cystic Artery)

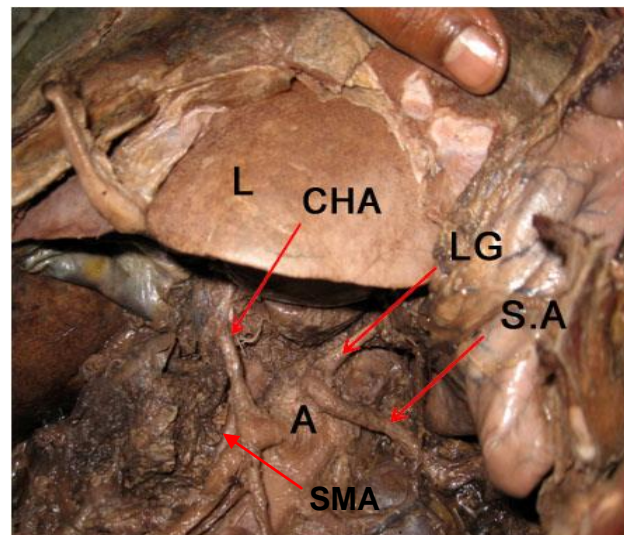


Fig-2: Photograph showing the left gastric and splenic artery arising from coeliac trunk and common hepatic artery from superior mesenteric artery. (S.A=splenic artery, S.M.A=superior mesenteric artery, L.G=Left gastric artery, C.H.A=Common hepatic artery & A=Abdominal aorta)

DISCUSSION

The stages of development of hepatic artery explains the reason for commonly observed variations in the artery supply of liver. In the embryonic life liver is supplied from 3 arterial sources-

1. Left hepatic artery from left gastric artery
2. Middle hepatic artery from coeliac trunk
3. Right hepatic artery from Superior mesenteric artery

With further development, middle hepatic artery establishes communications with right and left hepatic arteries and their proximal portions disappear. Thus the adult arterial pattern is established with both right and left hepatic arteries arising from middle hepatic artery which becomes the common hepatic artery. Persistence of all the three arteries that normally disappear or disappearance of an artery that normally persists can lead to any of the following variations in artery supply of liver.

- 1) Common hepatic artery supplying right lobe of liver and left hepatic artery arising from the left gastric artery

- 2) Common hepatic artery supplying left lobe of liver and right hepatic artery arising from superior mesenteric artery
- 3) Persistence of all the three arteries
- 4) In atrophy of middle hepatic artery, the common hepatic artery arises either from superior mesenteric artery(9%) or left gastric artery(1%) or from both(2%).

experience. *Zhonghua yi xue za zhi* (Taipei) 1998; 61:17-23.

CONCLUSION

Variations of hepatic artery is so common that all the possibilities should be kept in mind in addition to normal anatomy. Introduction of laparoscopic cholecystectomy has stimulated a renewed interest in the anatomy of hepatic artery. Surgical mistakes from failing to appreciate hepatic artery anatomy continue to be made with serious consequences to the patient with medico-legal implications. For safe surgery and low morbidity, care must be taken to prevent division or damage to any such artery arising and taking an abnormal course and relation.

REFERENCES

1. Bhardwaj N. Anomalous origins of hepatic artery and its significance for hepatobiliary surgery. *J. Anat. Soc. India* 2010;59(2) 173-176.
2. Suganthy J, Indra Singh I, Jacob T, Agrawal R. Multiple vascular variation of splanchnic branches of abdominal aorta in a 103 year old south Indian male: A case report. *J. Anat. Soc. India* 2008;57(1) 37-42.
3. Hiatt JR, Gabbay J, Busutil RW. Surgical anatomy of hepatic arteries in 1000 cases. *Ann Surg* 1994;220:50-2.
4. Flint ER. Abnormalities of right hepatic, cystic and gastroduodenal arteries and of the bile duct. *Brit J Surg*, 1923;10:509-19.
5. Pujahari AK. Problem of a rare anomalous hepatic artery during whipple procedure. *Saudi J Gastroenterol* 2010;16:122-3.
6. Chen CY, Lee RC, Tseng HS, Chiang JH, Hwang Ji, Teng MM. Normal and variant anatomy of hepatic arteries: angiographic