



## Unilateral Pulmonary Hypoplasia In An Asymptomatic Adult

Authors

**Dr. M Umar Majid MD, DNB, FCCP, Dr. Nisar Hajam MD,  
Dr. Javaid A Malik MD,DM,FCCP, Dr. Bilal Ahangar MD**

Dept of Pulmonary Medicine, SKIMS Medical College Hospital Bemina Srinagar Kashmir, J & K India

Corresponding Author

**Dr. M Umar Majid**

311C Lane No.7 Budshah Nagar Natipora Srinagar Kashmir 190015 J&K India

Email: [drumarmajidrx@yahoo.com](mailto:drumarmajidrx@yahoo.com), Tele: +919419477354

### Abstract

*A case of Unilateral hypoplasia lung in a 24 years old male is presented here who was referred to our hospital by his primary care provider with an abnormal chest x-ray and on further investigation with computed tomography of thorax and bronchoscopy he was found to have left hypoplastic lung with no other anatomic abnormalities.*

**Keywords:** Pulmonary Hypoplasia, CT scan thorax, Bronchoscopy

### Introduction

Pulmonary hypoplasia usually manifests in infancy or childhood with other organ dysfunction. It rarely manifests in adults. Common developmental anomalies associated with pulmonary hypoplasia involve urinary system, diaphragm, cardiovascular system, central nervous system and also musculoskeletal system.<sup>1</sup> Because of its rarity we are presenting a case of isolated Unilateral Pulmonary hypoplasia in an asymptomatic adult.

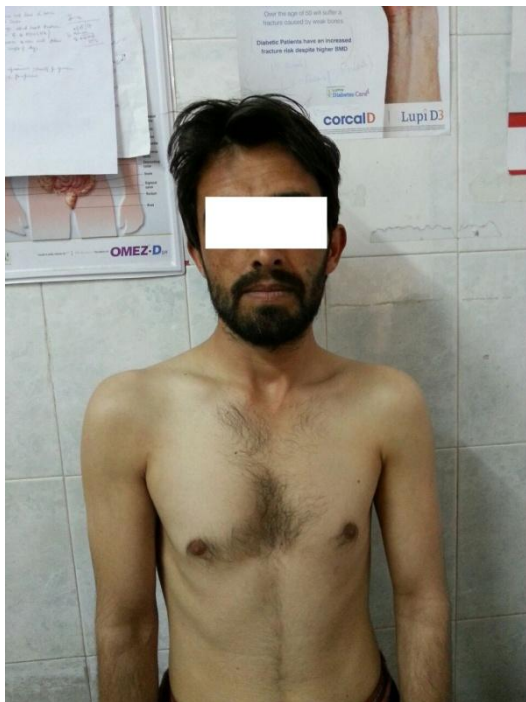### Case Report

A 24 years old male without any significant past medical history presented to his primary care provider with complaints of mild breathless and

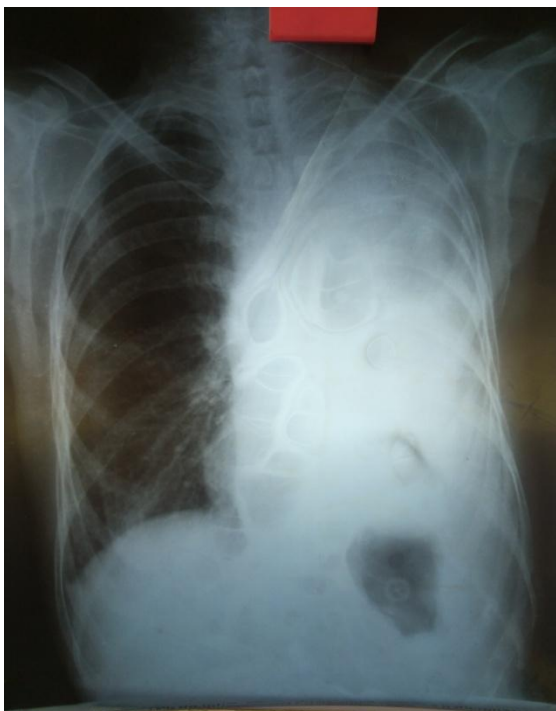cough of 5 days duration and was found to have an abnormal chest X-ray was referred to our hospital for further evaluation. While asking the history patient recalls having frequent respiratory tract infections in his childhood. Physical examination of respiratory system reveals flat left hemi thorax fig.(1), trachea and cardiac impulse shifted to the left, with decrease to absent breath sounds on the left side. His chest x-ray showed opacification of the left hemi thorax with ipsilateral mediastinal shift fig.(2). Contrast enhanced CT scan of thorax revealed profoundly hypoplastic left lung fig.(3,4). Spirometric results showed mild restriction. Video bronchoscopy showed normal trachea, carina and right bronchial tree. Left main bronchus was so narrowed that

bronchoscope couldn't get passed through. Further workup for other associated congenital anomalies was done. Echocardiography and ultrasound abdomen were reported normal. On the basis of CT scan and bronchoscopic findings left lung hypoplasia was diagnosed in this patient and was discharged with annual prophylactic vaccination and periodic follow up.

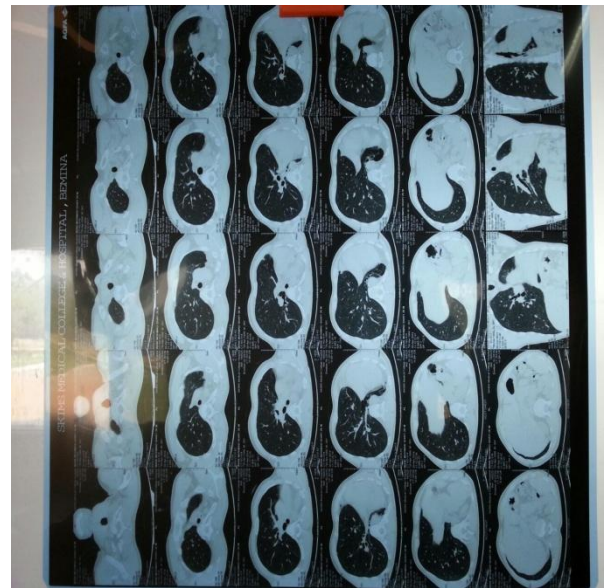
**Fig.(1)**



**Fig.2**



**Fig.3**



**Fig.(4)**



### Discussion

Pulmonary hypoplasia is of two types:<sup>1</sup>

1. Primary or Idiopathic
2. Secondary

**Primary Pulmonary hypoplasia:** It is an intrinsic defect during lung development with an incidence of 1-2 cases per 12000 live births.<sup>2</sup> Contributing factors which may play the role as etiology are vitamin A deficiency, genetic factors or viruses.

**Secondary Pulmonary hypoplasia:** It is known to be caused by several mechanisms, most

common being space occupying lesion like congenital diaphragmatic hernia. Thoracic neuroblastoma, sequestered lung also may contribute.<sup>3,4,5</sup>

Congenital pulmonary hypoplasia is associated with other anomalies like diaphragmatic hernia, bronchopulmonary sequestration or cardiac and vascular developmental abnormalities. Most frequent associated syndrome is POTTER'S syndrome<sup>6,7</sup>--- which includes renal agenesis, pulmonary hypoplasia, limb and facial abnormalities.

**Presentation:** Usually presents in childhood with dyspnea, cough, hemoptysis and rarely presents in adults with past history of recurrent respiratory tract infections, exertional breathlessness, cough with or without hemoptysis<sup>8,9</sup>. Very rarely patient remains asymptomatic till adulthood and the diagnosis is made incidentally while taking chest x-ray for other mild respiratory symptoms as in our case.

**Clinical findings:** Flat hemithorax, reduced respiratory movements, tracheal and cardiac impulse shift towards affected side and absent breath sounds.

**Diagnosis:** can be made by contrast enhanced computed tomography and bronchoscopy. Pulmonary angiography may also be needed in some cases.<sup>9</sup>

**Treatment:** Depends upon the degree of abnormality and also associated other organ dysfunction<sup>10</sup>. Adult asymptomatic patients as in our case does not need any treatment except prophylaxis against Influenza, respiratory syncytial virus and pneumococcal infections.

## References

1. Kant S: Unilateral Pulmonary Hypoplasia. A case report. Lung India 2007; 24: 69-71
2. Sangeeta Sharma, Suresh Kumar, Deepak Yaduvanshi et al. Isolated Unilateral Pulmonary Agenesis: Indian paediatr.2005; 42: 170-172.
3. Terry Chin, Yazin Said Natrajan Abdulhamid I. Pulmonary hypoplasia. Available from: <http://www.emedicine.com/ped/topic2627.htm> [cited Nov 17.2006]
4. Khalid Kamal, Abdulhamid I, Eric R Eggenberger et al: Congenital Lung Malformations. Available from: <http://www.emedicine.com/ped/TOPIC2935.HTM> [cited Dec 5.2007]
5. Suzuki Keij i. Respiratory characteristics of infants with pulmonary hypoplasia syndrome following preterm rupture of membranes: a preliminary study for establishing clinical diagnostic criteria. Early Human Development 2004; 79: 31-40.
6. Gabarre JA, Alberto Galindo Izquierdo, Miguel Rasero Ponferrada et al: Isolated unilateral Pulmonary Agenesis, Early Prenatal Diagnosis and Long-term Follow-up. J Ultrasound Med 2005: 865-868.
7. Sundararajaperumal A, Vinodkumar V, Sundar V, Ranganathan D : Primary pulmonary hypoplasia in an adult. Pulmonol 2008; 10 : 1 : 12 – 15
8. Nogueira-Silva C, Moura RS, Esteves N, Gonzaga S, Correia-Pinto J. Intrinsic catch-up growth of hypoplastic fetal lungs is mediated by interleukin-6. Pediatr Pulmonol. Jul 2008;43(7):680-9.
9. Hsu JS, Lee YS, Lin CH, Li FY, Jeng MJ, Soong WJ, et al. Primary congenital pulmonary hypoplasia of a neonate. J Chin Med Assoc. Feb 2012;75(2):87-90.
10. Ackerman KG, Herron BJ, Vargas SO, et al. Fog2 is required for normal diaphragm and lung development in mice and humans. PLoS Genet. Jul 2005;1(1):58-65.