



## Malignant Fibrous Histiocytoma with Giant Cell: A Cytological, Histopathological and Immunohistochemical Study of A Rare Differential

Authors

**M.A. Muzaffar<sup>1</sup>, Anju Singh<sup>2</sup>, Amod Kumar<sup>3</sup>, Mona Lisa<sup>4</sup>, Subhash Chandra Jha<sup>5</sup>, Shahab Raza<sup>6</sup>**

<sup>1</sup>Tutor, Department of Pathology, Patna Medical College, Patna,

<sup>2</sup>Assistant Professor, Department of Pathology, Indira Gandhi Institute of Medical sciences, Patna,

<sup>3</sup>Consultant Pathologist, SRL Diagnostics, Patna,

<sup>4</sup>Senior Resident, Department of Pathology, Indira Gandhi Institute of Medical sciences, Patna

<sup>5</sup>Assistant Professor, Department of Pathology, Government Medical College, Bettiah

<sup>6</sup>Associate Professor, Department of Pathology, Patna Medical College, Patna

Corresponding Author

**Dr. Subhash Chandra Jha**

Assistant professor, Department of Pathology, Government, Medical College, Bettiah, Pin code: 847428,  
Email ID: [jhatho25@gmail.com](mailto:jhatho25@gmail.com) Mobile: 09771434052

### Abstract

*Malignant Fibrous histiocytoma (MFH) is now diagnosis of exclusion, comprising <5% of adult soft tissue malignant lesion. MFH predominantly is originating from extremities and retroperitoneum. Uncommon presentation can be in chest wall, bone, spermatic cord and other organs. As other malignant soft tissue tumour; histologically mimics MFH, hence immunohistochemistry (IHC) is essential for final diagnosis. The IHC findings revealed strong positive staining for CD68 and negative staining for SMA, CD34. The patient was managed by wide margin surgery followed by radiotherapy. He was disease free when followed up for a year. Although MFH of the chest wall is rare, however it must be considered as a differential diagnosis of chest wall tumours.*

**Keywords:** Malignant fibrous histiocytoma, immunohistochemistry, soft tissue sarcoma, chest wall

### INTRODUCTION

Malignant Fibrous histiocytoma (MFH) is now diagnosis of exclusion, comprising <5% of adult soft tissue malignant lesion <sup>[1]</sup>. MFH is predominantly originating from extremities and retroperitoneum, previously it was considered most common soft tissue malignant tumour of adults. With advent and application of immunohistochemistry; different types of this

group of tumour are regrouped either in fibrosarcoma, leiomyosarcoma, angiosarcoma or malignant osteoclastoma<sup>[2,3]</sup>. There are vast number of benign and malignant differentials of soft tissue tumour including benign lesion like lipoma, benign fibrous histiocytoma and sarcomas of different lineages, malignant melanoma and metastasis.

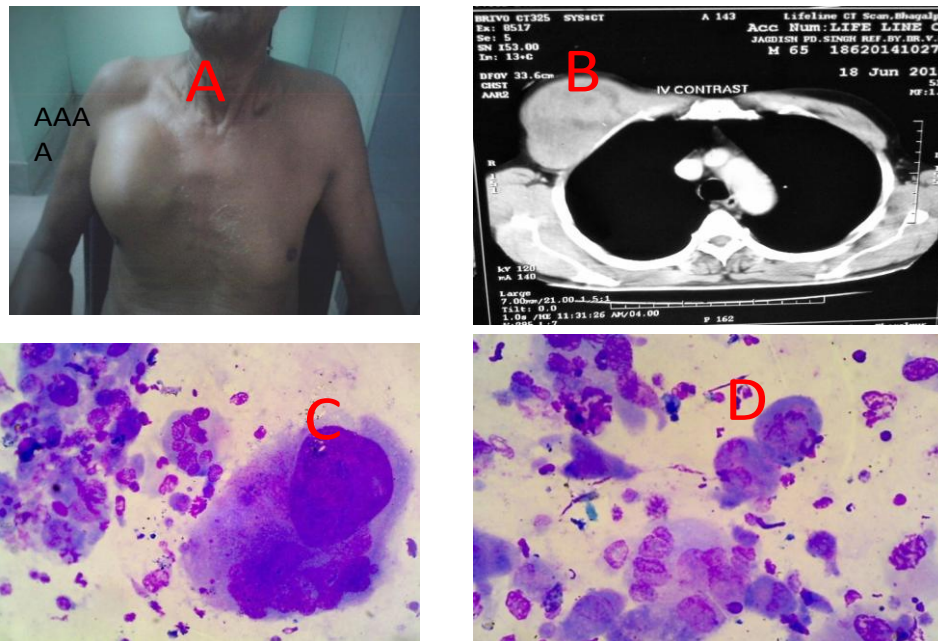
Uncommon presentation can be in chest wall, bone, spermatic cord and other organs. In the WHO classification (2002), MFH is renamed as undifferentiated high grade pleomorphic sarcoma<sup>[1]</sup>. The presentation of MFH–giant cell variant (undifferentiated pleomorphic sarcoma with giant cell) is rare in chest wall. Histopathologically this variant has malignant proliferation of fibroblasts admixed with pleomorphic giant cells of so-called histiocytic origin<sup>[3,4]</sup>. As other malignant soft tissue tumour; histologically mimics MFH, hence immunohistochemistry (IHC) is essential for final diagnosis. Specific diagnosis is essential in view of very aggressive nature of disease so that proper surgical, chemotherapeutic and radiotherapeutic interventions can be done.

The widespread introduction of immunohistochemistry has been one of the major factors in demolition of the MFH concept. Most high grade pleomorphic sarcomas show a definable line of differentiation, foremost among which are the pleomorphic variants of leiomyosarcoma, liposarcoma, rhabdomyosarcoma and myxofibrosarcoma, after carcinomas, melanomas and lymphomas have been excluded<sup>[2,3,4]</sup>. Immunohistochemistry is critical in helping to separate the latter non-mesenchymal malignancies. Controversy exists as to the extent of immunopositivity required for a given antigen to define a specific line of differentiation but diagnostic criteria have been proposed for the different pleomorphic sarcomas and these appear to be reproducible<sup>[6,7]</sup>. The presence of just rare cells showing positivity for epithelial or myogenic antigens most often has little significance and does not, itself, exclude this diagnosis. It is now accepted that histiocytic antigens (such as alpha-1-antitrypsin, alpha-1-antichymotrypsin, lysozyme and CD68) play no useful role in the diagnosis of pleomorphic sarcomas.

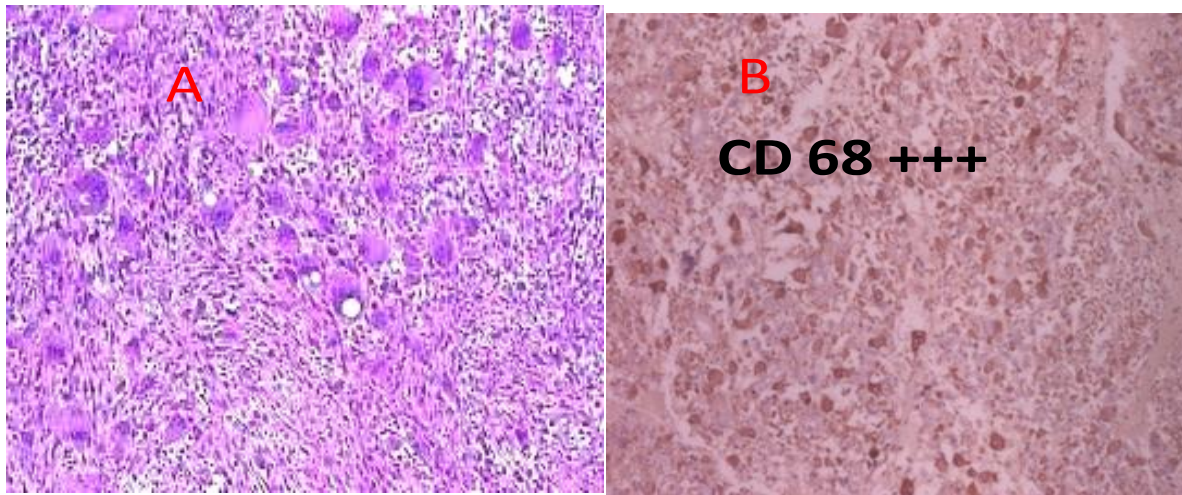
#### CASE SUMMARY

A 65 year old male farmer presented with a painless mass from 4 months duration in the right anterior chest wall. (Fig.1A) On clinical

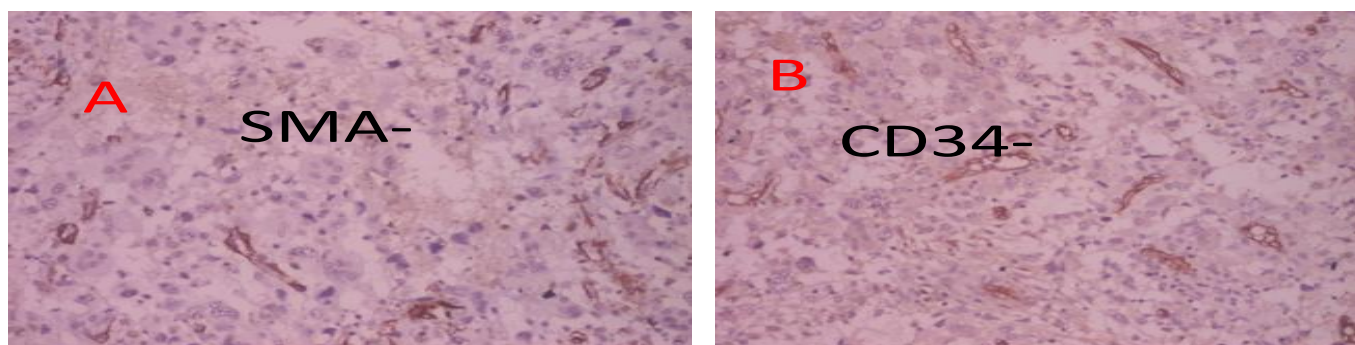
examination, the mass was firm in consistency and measured 10 X 6 cms. CT scan showed a mass involving the pectoralis muscle and pushing the pleura of the right upper lung but not invading the ribs (Fig. 1B). Fine Needle Aspiration Cytology (FNAC) yielded a cellular smear with predominantly dispersed oval to spindle cells with markedly pleomorphic hyperchromatic bizarre nuclei and numerous multinucleated tumour giant cells (Fig. 1 C,D)). It was cytomorphologically reported as malignant fibrous histiocytoma. Tru cut biopsy of the lesion was done and histopathological diagnosis was Giant Cell MFH which was reassured by immunohistochemistry (IHC) (Fig. 2 A,B). The IHC findings revealed strong positive staining for CD68 and negative staining for SMA, CD34 (Fig. 2B, Fig. 3A, B). In this case, on fine needle aspiration cytology (FNAC) and histopathology, impression was MFH, so cost effective panel of antibodies were used.



**Figure 1. (A)** Photograph showing large soft mass in right upper chest wall **(B)** CT scan revealing destructive lesion involving pectoralis muscle & pushing the pleura **(C,D)** microphotograph showing pleomorphic tumour cells with bizarre nuclei & osteoclast-like giant cells



**Figure 2.(A)** The microphotograph of histopathology shows fascicles of tumour cells and multinucleated giant cells **(B)** The pleomorphic tumour cells and giant cells are positive for CD68



**Figure 3. ( A ) Tumour cells are negative for SMA but smooth muscle cells of blood vessels are showing positivity ( B ) Tumour cells are negative for CD34 ( marker of haemangiopericytoma & SFT ) but endothelial cells of blood vessels are positive**

5

## DISCUSSION

Malignant Fibrous Histiocytoma is synonymous with undifferentiated pleomorphic sarcoma, is a deep seated pleomorphic sarcoma of uncertain origin. The recent WHO classification renamed it as undifferentiated pleomorphic sarcoma, NOS<sup>[1]</sup>. Actually it represents <5% of adult soft tissue sarcoma. It occurs most frequently in the lower extremities. Occurrence in chest wall is rare<sup>[7]</sup>. The histological subtypes include pleomorphic, giant cell, inflammatory, angiomatoid and myxoid types. The prognosis after surgery and adjuvant therapy is very poor<sup>[7,8]</sup>.

Sawai H. et al (1998) reviewed 36 similar cases of primary chest wall MFH and found that 25% cases had subsequent metastasis and 31 % had local recurrence. Krishnamurthy et al (2013) also reported a similar case of chest wall MFH but the tumour was also invading the ribs at the time of diagnosis.

## CONCLUSION

The patient was managed by wide margin surgery followed by radiotherapy. He was disease free when followed up for a year .Although MFH of the chest wall is rare ,however it must be considered as a differential diagnosis of chest wall tumours. Now, IHC is essentially needed for definitive diagnosis in view of rarity of this tumour.

## REFERENCES

1. Christopher D.M., Fletcher K. Krishnan Unni, Fredrik Mertens (eds) .Pathology and Genetics of Tumours of Soft Tissue and Bone. IARC Press Lyon, 2002
2. Fletcher CD (1992). Pleomorphic malignant fibrous histiocytoma: fact or fiction? A critical reappraisal based on 159 tumors diagnosed as pleomorphic sarcoma. *Am J Surg Pathol* 16: 213-22820
3. Fletcher CD, Gustafson P, Rydholm A, Willén H, Åkerman M (2001). Clinicopathologic re-evaluation of 100 malignant fibrous histiocytomas: prognostic relevance of subclassification. *J Clin Oncol* 19: 3045-3050.
4. Angervall L, Hagmar B, Kindblom LG, Merck C (1981). Malignant giant cell tumor of soft tissues: a clinicopathologic, cytologic, ultrastructural, angiographic, and microangiographic study. *Cancer* 47: 736747.
5. Guccion JG, Enzinger FM (1972). Malignant giant cell tumor of soft parts. An analysis of 32 cases. *Cancer* 29: 1518-1529.
6. Mertens F, Fletcher CD, Dal Cin P, de Wever I, Mandahl N, Mitelman F, Rosai J, Rydholm A, Sciort R, Tallini G, van den Berghe H, Vanni R, Willén H (1998).

Cytogenetic analysis of 46 pleomorphic soft tissue sarcomas and correlation with morphologic and clinical features: a report of the CHAMP study group. *Genes Chromosomes Cancer* 22: 16-25.

7. Krishnamurthy A ,Ramshankar V,Majhi U :Malignant fibrous histiocytoma of the chest wall: A rare differential. *South Asian J Cancer*. 2013 Jul;2(3):185.  
doi: 10.4103/2278-330X.114154.
8. Sawai H, Kamiya A, Kurahashi S, Yamanaka Y, Manabe T: Malignant fibrous histiocytoma originating from the chest wall: report of a case and collective review of cases. *Surg Today*. 1998; 28(4): 459-63.