



An Unusual Delayed Complication of Central Venous Cannulation: A Case Report

Authors

Dr. Shubha N. Mohite¹, Dr. Swati Chhatrapati², Dr. Rochana G. Bakhshi³

^{1,3}Department of Anaesthesiology, D.Y.Patil Medical College & Hospital, Nerul, Navi- Mumbai-400706.

²Department of Anesthesiology TNMC & B.Y.L.Nair
Hospital & Medical College, Mumbai

ABSTRACT

The venous system is a common anatomical site for a number of foreign bodies. Our case reports a central venous catheter left accidentally in the venous system. The catheter was found with its one end in the right ventricle and the other in the pelvis adjacent to right utero vesical junction and bladder and traversing inferior vena cava, right iliac vein and proximal internal iliac vein. It was found as an incidental finding during investigations (CT abdomen and X ray abdomen). It was retrieved after surgical exploration. A brief case report with review of literature is presented.

Keywords: central venous catheter, complications, foreign body, right ventricle.

INTRODUCTION

Central venous cannulation requires technical skill as well as guidance. Turner and Sommer first reported the accidental disappearance of a catheter piece 22 cm in length, from the cubital vein, with the catheter getting lodged in the right atrium and superior vena cava and patient's death occurring two days later. ⁽¹⁾ Patients with cardiopulmonary localization of foreign bodies are at risk for developing cardiac arrhythmias and perforation. ⁽²⁾ Similar incidences have been reported but are unusual. We report a case of a 32 year old woman with a catheter left in situ in the venous system for 10 years with its tip in the right ventricle.

CASE REPORT

A 32 years old female presented with complaints of generalized weakness, blackout, giddiness,

multiple episodes of vomiting, menorrhagia with pain in abdomen and recurrent respiratory tract infections for 10 years. She received symptomatic treatment for the same without any benefit. On further enquiry, she gave history of right sided ectopic pregnancy and circulatory collapse 10 years back. She was treated for hypovolemic shock and underwent right oophorectomy. The retrospective detailed history did not give any clue about central venous cannulation, but since then she started getting above complaints on and off. Systemic examination was unremarkable except pallor with hemoglobin of 7gm% with normal coagulation studies. Plain X-ray abdomen showed a possibility of a DJ stent in situ. However, Ultrasonography (USG) abdomen and Barium meal study were normal. Magnetic Resonance Imaging (MRI) showed a retained femoral line

displaced and seen posterior to the bladder. Computed tomography (CT) scan confirmed a displaced stent with its tip in Right ventricle and another end in pelvis just adjacent to right uterovesical junction and traversing the IVC, Right iliac vein and proximal internal iliac vein. Patient was given blood transfusion for correction of anaemia. Later, patient underwent surgical exploration by oblique lower abdominal incision and extra peritoneal approach under general anaesthesia. A central venous catheter was retrieved (Fig.1). Rest of the intraoperative and postoperative course was uneventful.

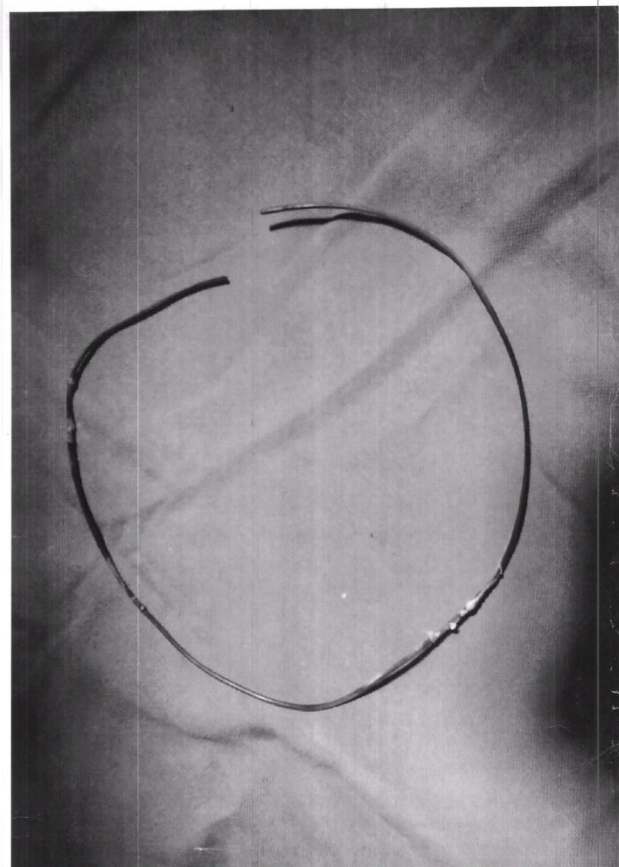


FIG -1 : The Retrieved Catheter

Figure 1. Image showing retrieved catheter

DISCUSSION

Central venous catheter is mainly put for measurement of central venous pressure, administration of vasoactive/inotropic drugs, administration of total parenteral nutrition and hemodialysis/plasmapheresis⁽³⁾. There are various

complications of catheter placement in venous system. Early complications include pneumothorax, venous rupture, Air embolism, Catheter malposition, ventricular perforation, cardiac arrhythmias, tamponade, Acute airway obstruction, Nerve injury, Diaphragmatic paralysis⁽⁴⁾. Insertion of a central venous cannulation is a blind procedure which may lead to complications as mentioned. However, complication rates can be significantly reduced with aid of imaging guidance during catheter placement.

Late complications include catheter related infections, septicemia, occlusions and catheter fracture and migration. The major error in technique that leads to catheter embolism is an attempt to withdraw the catheter through the sharply beveled needle. If the lacerated catheter is within the venous system, it may then embolize to the heart. Presence of the catheter as a foreign body may lead to chronic infection with resultant chronic anemia which was present in our patient. The patient may have undergone a right femoral vein cannulation with tip lying in the right ventricle. Sudden blackouts may be explained as arrhythmias caused by the tip of the catheter irritating the right ventricle as well as chronic anemia. Egglin et al in their study have mentioned a 77 year old woman with ventricular ectopy and hypotension, due to a triple lumen catheter fragment lying in the right ventricle.⁽⁵⁾

To minimize catheter related problems the following points may prove to be of help:

- Incorporation of a radio opaque fibre or material into the catheter by the manufacturer.
- Adherence to the well defined indications and contraindications of central venous catheterization
- Chest radiography, as a routine procedure after any attempted central venous catheterization (whether successful or not)
- Immediate reporting of a broken catheter
- Removal of catheter at the earliest

- Least movements of body parts like flexion of neck, arm leg etc.

The significance of this case is that it is mandatory to check the hard end of the guidewire sticking out the end of the sheath dilator system, so as to prevent it from entering the venous system and thus preventing subsequent complications.

REFERENCES

1. Turner .D.D. and Sommers, S.C: New Eng. J. Med., 1954, 251 : 744.
2. Muhsin Turkmen, Atila Bitigen, Ali Cevat Tanalp, Evren Kaynak, Yelda Basaran, Cevat Yakut; A guidewire Accidentally left in venous system for 6 years. Turkish J. Thorac Cardiovasc surg 2004;12;138-40.
3. Sally E Mitchell and Robert A Clark ,Complications of Central venous Catheterization: AJR 1979 133; 467-76.
4. Ashutosh Chauhan ,Malpositioning of Central Venous Catheter: Two case reports: IJA 2008;52 :337-9
5. Thomas K.P.Eggin, Kevin W.Dickey, Melvin Rosenblatt Jeffrey S.Pollak, Retrieval of Intravascular Foreign bodies: Experience in 32 Cases, AJR 1995;164: 1259-64