



Artery of Percheron Occlusion as a Cause of Bilateral Median Thalamic Infarct – A Case Report

Authors

Dr. Lalitha Kumari G¹, Dr. Panil Kumar B E², Dr. M V Ramanappa³

¹Assistant professor, Department of Radiodagnosis, Santhiram Medical College and General Hospital ,
Nandyal, Kurnool Dist, Andhra Pradesh, India

²Professor, Department of Radiodagnosis, Santhiram Medical College and General Hospital , Nandyal,
Kurnool Dist, Andhra Pradesh, India

³Professor, Department of Radiodagnosis, Santhiram Medical College and General Hospital , Nandyal,
Kurnool Dist, Andhra Pradesh, India

Corresponding Author

Dr. Lalitha Kumari G

Assistant Professor, Department of Radio-Diagnosis, Santhiram Medical College and General Hospital,
NH 18, Nandyal, Andhra Pradesh, India.518501

Email: drlalithanarayang@gmail.com

ABSTRACT

Thalamic nuclei have wide variations in arterial supply. Bilateral thalamic infarcts could be due to occlusion of occlusion of artery of Percheron which is one of variant of thalamo perforator arteries. High level of clinical suspicion, early diagnosis and prompt treatment aids in effective management of these cases.

KEY WORDS: *Bilateral thalamic infarcts, Artery of Percheron (AOP)*

CASE REPORT

A 60 year old lady presented to casualty with history of sudden loss of consciousness. She is a known diabetic and hypertensive. Her vitals are normal and patient is responding to painful stimuli. Her blood investigations including for hypercoagulable state are normal. EEG and Echo

cardiogram are normal. Ophthalmic examination revealed no obvious abnormality.

CT has been performed after 8 hrs of onset of symptoms. This revealed symmetrical hypodensities in bilateral median thalami and in rostral midbrain which are consistent with acute infarction.

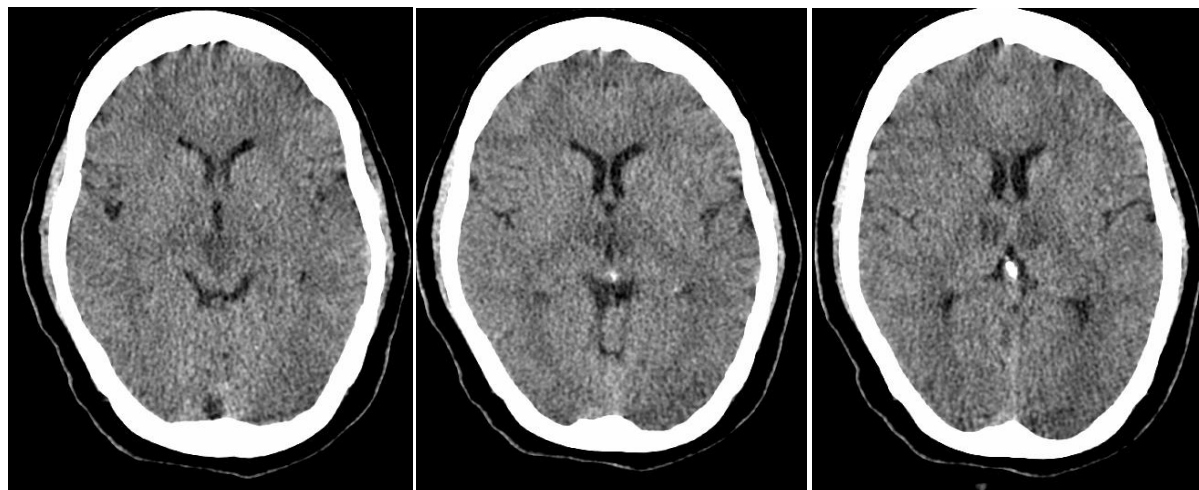


Figure 1: Non contrast CT imaging 8 hours after the onset of symptoms showed signs of infarct in paramedian regions of both thalamii and in rostral midbrain .

DISCUSSION

AOP infarcts accounts for 22-35% bilateral median thalamic infarction and 0.1 -0.3% of all ischemic stroke etiology^(1,2).

The most common etiology of bilateral thalamic infarctions is cardioembolism, atherosclerosis, atrial fibrillation, ventricular wall aneurysms, right-to-left shunts as well as hypercoagulable states, severely reduced left ventricular function, and vasoconstriction⁽³⁾. The mean age and sex predilection of bilateral thalamic infarcts secondary to occlusion of the Artery of Percheron are unknown due to its rarity. However, 58% of posterior cerebral artery infarcts affect men at a mean age of 61.5 years⁽³⁾.

The classic triad of symptoms includes hypersomnolence, vertical gaze paresis, amnesia. Atypical presentations include transient unconsciousness, transient III nerve dysfunction symptoms like ptosis, mydriasis .Other change seen after regaining of consciousness are mood changes, poor motivation, pseudobulbar palsy.

Understanding of thalamic anatomy and vascular territory of artery of percheron is important to explain the symptoms.

Historically, Percheron described three variations in the vascular supply to the paramedian thalami. Type I is the most common variant, where a perforating artery arises from each P1 segment^(4,5). Type II, the Artery of Percheron, arises from one P1 segment and splits to supply the bilateral thalami and rostral midbrain [Figure 2].Type III was described as an arcade of perforating arteries arising from an artery bridging the bilateral P1 segments⁽⁴⁾.

If occluded, the Artery of Percheron is the only variant that results in bilateral paramedian thalamic infarcts, with or without midbrain involvement⁽⁵⁾. Infarction of pial surface of midbrain has been described as ‘V’ sign⁽⁶⁾.

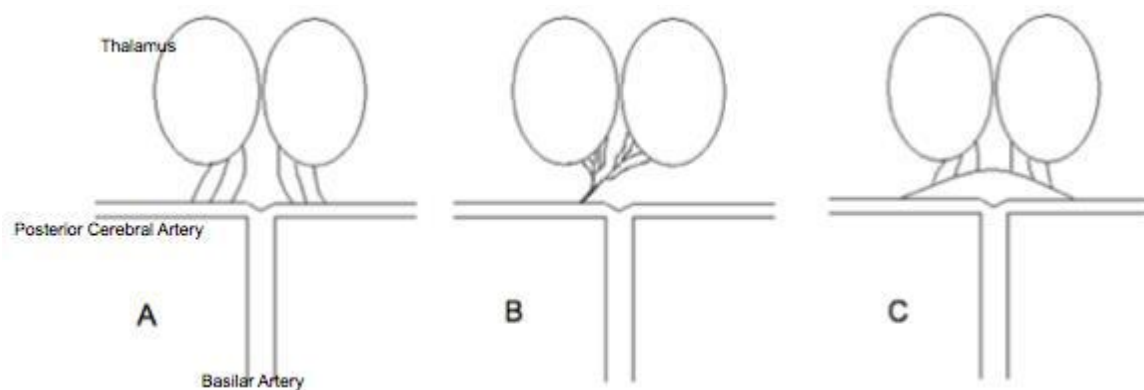


Figure 2 : Three types of paramedian thalamic-mesencephalic arterial supply described by Percheron.

Type I - Most common variant, where a perforating artery arises from each P1 segment.

Type II - The Artery of Percheron arises from one P1 segment and splits to supply the bilateral thalami and rostral midbrain.

Type III - An arcade of perforating arteries arising from an artery bridging the bilateral P1 segments.

Artery of percheron supplies paramedian and mesencephalic nuclei. Paramedian nuclei mainly constitutes dorsomedian and intralaminar nuclei. The intralaminar nuclei consist of parafascicular, centromedian, central medial, paracentral and central lateral nuclei. S maller nuclei of the 'midline', such as the paraventricular, rhomboid and reunions nuclei, are also included in the intralaminar group. Both nuclear groups are characterized by important and reciprocally activating connections with the anterior, orbitofrontal and medial prefrontal cortices through the thalamic peduncles ^(7,8), thus explaining the neuropsychiatric impairment, dysfunction of reticular activating system and the loss of self-activation characteristic of paramedian infarctions.

The rostral midbrain can also be involved after occlusion of the artery of Percheron. Manifestation of mydriasis, ptosis and exophthalmos are all suggestive of an effect at this level due to the periaqueductal gray matter involvement where the third cranial nerve nuclei are located. ⁽⁹⁾.

Patient vertical gaze limitation has been reported as part of thalamic syndromes, perhaps related to a remnant affecting the rostral interstitial nucleus of the medial longitudinal tract, precisely located between the diencephalon and the midbrain.

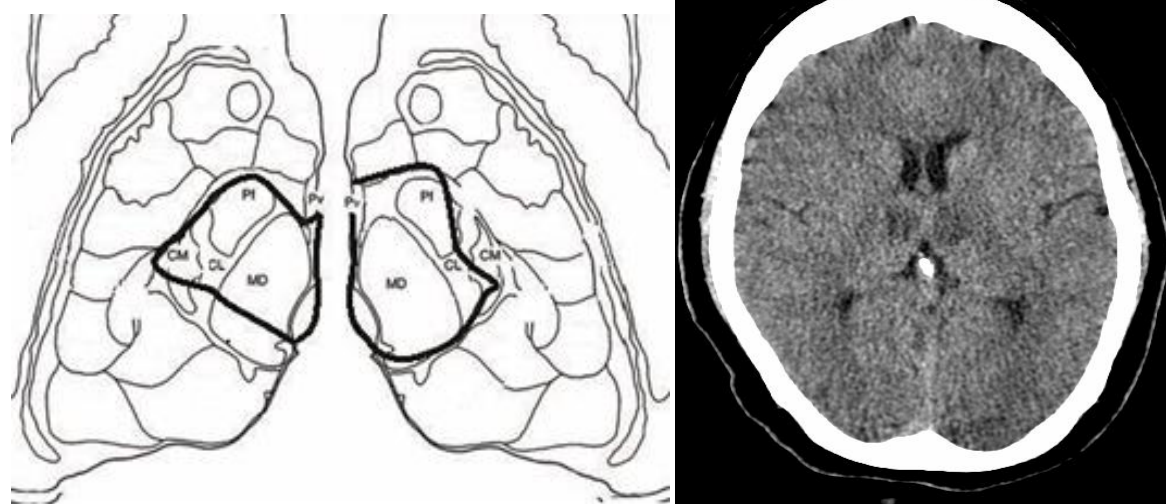


Figure 3: Schematic representation of affected thalamic nuclei in this case compared with CT image of the same patient. black line limits the area of infarction in paramedian regions. CM=centromedian, Pf=paraventricular, CL=central lateral, MD=dorsomedialis.

Treatment options include thrombolysis⁽⁶⁾ and medical therapy. Bilateral thalamic infarcts usually carry a favorable prognosis, although some patients experience persistent visual field deficits^(2,3).

DIFFERENTIAL DIAGNOSIS

Firstly, Top of the basilar syndrome, usually due to embolic disease, should be suspected in all patients who show the classic triad for this syndrome including complex ocular symptoms, impaired consciousness (agitation, memory dysfunction, coma) and long tract neurological signs⁽¹⁰⁾. When the basilar artery is occluded, there are typically infarcts of not only the bilateral thalami but the posterior cerebral, superior cerebellar artery and pontine territories as well.

Second important entity Deep cerebral venous thrombosis should be taken into consideration. Rarely, venous sinus thrombosis can present with isolated bilateral thalamic infarcts from occlusion of the internal cerebral veins, most notably the straight sinus.

Others Nonvascular etiologies⁽⁵⁾ such as metabolic causes like Wilsons disease, nutritional

causes like wernickes encephalopathy, electrolyte imbalance like extra pontine myelinolysis, neurodegenerative disease like creutzfeldt Jakobs disease and neoplasm like bilateral thalamic glioma may also present with bilateral thalamic lesions and can mimic bilateral thalamic infarctions on imaging. Patient history & specific imaging are key for diagnosis.

CONCLUSION

Artery of Percheron infarction should be kept in mind in cases of transient ischemic attacks with or without III nerve palsy apart from stroke with classic triad. The knowledge of this important anatomical variant should be kept in mind in considering the differential diagnosis for bilateral thalamic infarcts and in performing surgical clipping, endovascular treatment or operations involving interpeduncular fossa.

REFERENCES

1. Cassouret G, Prunet B, Sbardella F, Bordes J, Maurin O, Boret H. Ischemic Stroke of the Artery of Percheron with Normal Initial MRI: A Case Report. *Case Report Med.* 2010;2010:425734.
2. López-Serna R, González-Carmona P, López-Martínez M. Bilateral thalamic stroke due to occlusion of the artery of Percheron in a patient with patent foramen ovale: a case report. *Journal of Medical Case Reports.* 2009 Sep;3:7392.
3. Yamamoto Y, Georgiadis AL, Chang HM, Caplan LR. Posterior cerebral artery territory infarcts in the New England Medical Center Posterior Circulation Registry. *Archives of Neurolog.* 1999 July; 56 (7):824-32.
4. Matheus, MG, Castillo, M. Imaging of Acute Bilateral Paramedian Thalamic and Mesencephalic Infarcts. *American Journal of Neuroradiology.* 2003 Nov-Dec; 24(10):2005-8.
5. Bilateral thalamic infarcts due to occlusion of the Artery of Percheron and discussion of the differential diagnosis of bilateral thalamic lesions Rodriguez et al. *journal of radiology case reports Radiology Case.* 2013 Jul; 7(7):7-14
6. Kostanian V, Cramer SC. Artery of Percheron thrombolysis. *AJNR Am J Neuroradiol* 2007;28:870-1.
7. Siwek D, Pandya D: Prefrontal projections to the mediodorsal nucleus of the thalamus in the rhesus monkey. *J Comp Neurol* 1991, 312:509-524.
8. Groenewegen H, Berendse H: The specificity of the “nonspecific”midline and intralaminar nuclei. *Trends Neurosci* 1994,17:52-56.
9. Raúl López-Serna, Patricia González-Carmona and Manuel López-Martínez: Bilateral thalamic stroke due to occlusion of the artery of Percheron in a patient with patent foramen ovale: a case report, *journal of medical case reports* 2009,3: 7392
10. Hedge A, Mohan S, Lath N, Lim CC. Differential diagnosis of bilateral abnormalities of the basal ganglia and thalamus. *Radiographics.* 2011 Jan;31(1):5-30