

www.jmscr.igmpublication.org

Impact Factor 3.79

ISSN (e)-2347-176x



Journal Of Medical Science And Clinical Research

An Official Publication Of IGM Publication

Waardenburg Syndrome – A Case Report

Authors

Dr Shabana Borate¹, Dr Prasad Kulkarni², Dr S.D.Gangane³

¹Associate Professor, Genetics Division, Department of Anatomy, Grant Government Medical College and Sir J.J.Group of hospitals, Byculla, Mumbai 8,India.

Email: *drshabaana@gmail.com*

²Associate Professor, Genetics Division, Department of Anatomy, Grant Government Medical College, and Sir J.J.Group of hospitals, Byculla, Mumbai 8, India.

Email: *drpgkmumbai@yahoo.co.in*

³Ex Professor and Head, Genetics Division, Department of Anatomy, Grant Government Medical College and Sir J.J.Group of hospitals, Byculla, Mumbai 8, India.

Email: *gangane@gmail.com*

Corresponding Author

Dr Shabana Borate

Associate Professor, Genetics Division, Department of Anatomy, Grant Government Medical College, Byculla, Mumbai 8, India.

Email - *drshabaana@gmail.com*, Mobile no: 9223547812/9821907712

ABSTRACT

Waardenburg syndrome is an autosomal dominant disorder often characterised by pigmentary anomalies of skin and hair and various defects of neural crest tissues. It accounts for 1-3% of all cases of congenital deafness. Here we describe two siblings, congenitally mute and deaf with heterochromia irides. Case I; is one and half year old male with complete heterochromia irides and associated Hirschprung's disease. Case II is seven year old female with bilateral partial heterochromia irides.

Key Words: *Waardenburg syndrome (WS), Neural crest, Heterochromia irides, Hirschprung's disease, dystopia canthorum.*

INTRODUCTION

Waardenburg syndrome (WS) is an autosomal dominant disorder of neural crest cell differentiation, most commonly described in Western populations. It's main clinical manifestations include sensorineural hearing loss, pigmentary abnormalities of the eyes, hair and skin (e.g. heterochromia iridum, white forelock

and patchy hypopigmented skin and dystopia canthorum). The syndrome is named after a Dutch ophthalmologist, Petrus Johannes Waardenburg (1951), who first noticed that people with differently coloured eyes often had a hearing impairment.^[1] It accounts for 1-3% of all cases of congenital deafness. Its incidence is approximately 1 in 42000.

This syndrome is both clinically and genetically heterogeneous and is clinically classified into four types.

Type I (WS1) – Associated with lateral displacement of the medial canthi.

Type II (WS2) – Normally placed medial canthi

Type III (WS3) (Klein- Waardenburg syndrome) – The principal features of which are upper limb defects including hypoplasia of muscles and bones, flexion contractures and syndactyly, in addition to the oculoauditory and pigmentary abnormalities characteristics of type I.

Type IV (WS4) (Shah-Waardenburg syndrome) – Associated with Hirschsprung disease combined with features of type II^[1]

Mutations of the PAX3 gene have been identified in WS type I and III, cytogenetic location of this gene is 2q36.1. WS type II is a heterogeneous group, with about 10% of cases caused by mutations in MITF gene (Microphthalmia associated transcription factor). Cytogenetic location of MITF gene is chromosome 3p14-p13. WS 2B has been mapped to chromosome 1p and WS 2C has been mapped to chromosome 8p23. WS4 is genetically heterogeneous, is caused by mutations in the EDN3 gene on chromosome 20q13 and soxio gene on chromosome 22q13.^[2]

CASE REPORT

Here we report two siblings, referred to our Genetic Division for Karyotyping. Both were born full term by non consanguineous marriage and antenatal history was also uneventful.

Case I

One and half year old male child presented with complaints of differently coloured eyes, constipation and delayed milestones. The patient was born full term with weight 3.5 kg, pregnancy; labour and delivery were reported to be normal. Child passed meconium 4 days after birth with the help of enema. Weaning started at 1st yr of age, since then child had on and off constipation. Now a day's child passes stool only after enema. Developmental milestones were delayed. Head control developed at 11th month, sitting with support at 13th month, walking with support at 17th month. Until now he doesn't vocalise and do not respond to noise or vocal commands.

On clinical examination hair were depigmented (fig 1) and sparse, wide epicanthal distance, broad nasal root. Depigmented patches were present on abdomen and thighs. Mouth was constantly open with protruding tongue. There were total heterochromia irides with right eye completely brown and left eye completely blue (fig 2).

There was bilateral sensorineural hearing loss. Abdomen was distended. Barium enema and anal manometry revealed Hirschsprung's disease.

Case II

Seven year old female child, elder sister of case I, had profound deaf mutism and abnormal irides since birth. She was born full term with birth weight 3.2 kg, following an uncomplicated pregnancy and normal hospital delivery. Perinatal course was uncomplicated. Developing milestones were normal. She was studying in a deaf mute school and her performance in school was satisfactory.

On clinical examination patient had brown and sparse hair. Wide epicanthal distance and broad nasal root. There was partial heterochromia irides, right eye was brown with bluish patch in the iris at 2-3^o clock position. Left eye was blue with a large brown sectoral patch at 4-7^o clock position. Patient had profound bilateral sensorineural hearing loss and vision was normal (fig 2)

Family history – Pedigree analysis revealed no significant history. Parents did not exhibit the disease. There was one normal sib (female child, 5yrs old) and one intrauterine death of sib at the 8th month of gestation, cause of death was not known.

Karyotype of both cases revealed normal chromosomal complement i.e 46XY and 46XX respectively (fig 3&4).

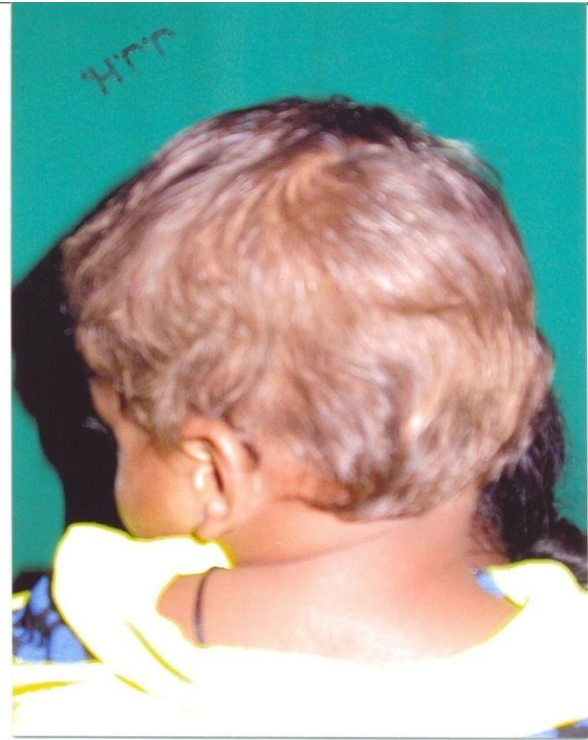

Fig 1 Case I showing hypopigmented hair.



Case I

Case II

Fig 2, Case I and II, showing heterochromia irides, lateral displacement of inner canthi and broad nasal bridge.

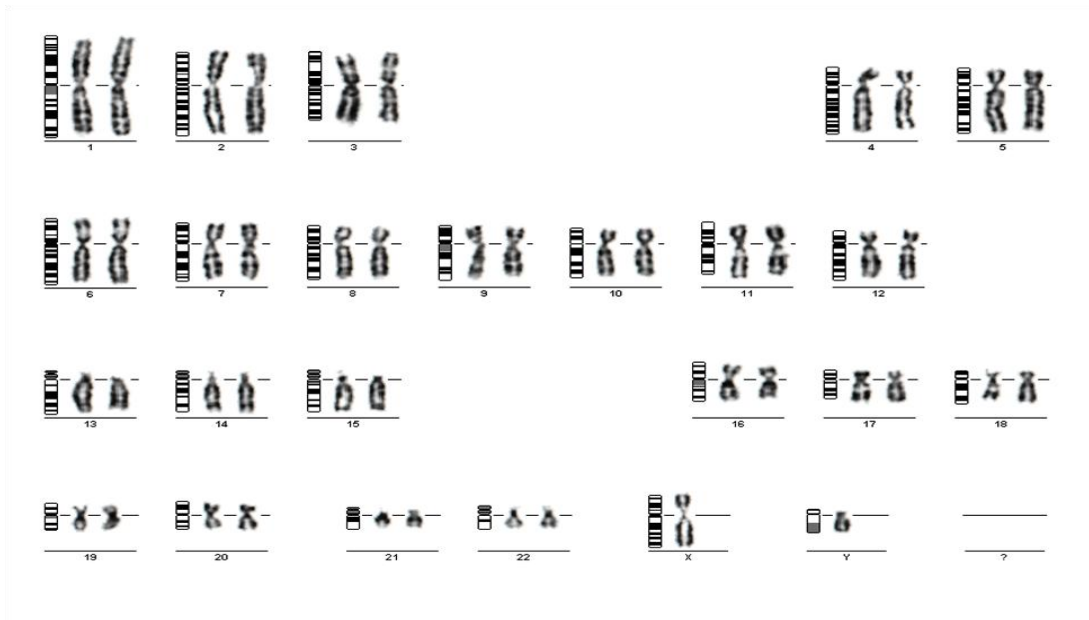


Fig 3: Showing 46XY Karyotype




Fig 4: Showing 46XX Karyotype.

DISCUSSION

All melanocytes, adrenal medulla, sympathetic ganglia, sensory components of the spinal and cranial nerves and membranous bones of the face and palate develop from neural crest cells during

the embryonic period. Hence various combinations of signs can occur in any hereditary defects of the neural crest cells [3]. Since the Meissner's and Auerbach's plexuses are derived from neural crest cells, white forelock, isochromia

irides and Hirschprung's disease may be manifestation of hereditary defects of the neural crest cells [3]. Complete heterochromia irides is noted rarely in the syndrome [4], our case I had complete heterochromia irides and case II had partial heterochromia irides. Congenital deafness is clinically the most serious symptom; it can be explained by lack of melanocytes in the stria vascularis of the cochlea. In piebaldism, the white forelock is present at birth and remains unchanged throughout life and the patches of depigmentation of skin are present from birth [4]. Hirschsprung's aganglionic megacolon is probably caused by a defect in migration of neuroblasts before 12th week of gestation [5]. The chances of a random coincidence of Hirschsprung's disease and Waardenburg syndrome is less than 1 in 5×10^7 children and males have a twofold higher risk of developing Hirschsprung disease as compared with females within the same family [6]. Several conditions are known to be associated with an increased risk of Hirschsprung's disease, including Down syndrome, neuroblastoma and several disorders with genetic basis [7].

CONCLUSION

In this family parents do not exhibit the disease and there is no family history. When genetic disease appears in two or more offspring with an autosomal dominant disease and there is no family history of the disorder, it is unlikely that multiple mutations would take place in the same family. The most likely mechanism in such cases would be germline mosaicism and it further increases the risk of future affected offspring. Here proper

genetic counselling and prenatal diagnosis plays an important role.

REFERENCES

1. Kenneth Lyons Jones, MD. Smith Recognizable Patterns of Human Malformation, 6th Ed. Elsevier Saunders. 2006; 278-279.
2. Br J Ophthalmol 2001;85:1384 (November), Letter to the editor, Waardenburg Syndrome type 2 in a Turkish family: implications for the importance of the pattern of fundus pigmentation.
3. Krishnakumar N Shah, Subhash J. Dalal, Meena P. Desai, "White forelock, pigmentary disorder of irides, and long segment Hirschsprung disease: Possible variant of Waardenburg syndrome," The Journal of Pediatrics, vol 99, number 3, pp 432-435, September 1981
4. Reynolds JE, Meyer JM, Landa B et al, "Analysis of variability of clinical manifestations in WS, Am J Med Genet, vol 57, pp 540-547, 1995
5. Okamoto E, Ueda T, "Embryogenesis of intramural ganglion of the gut and its relation to Hirschsprung disease", J Pediatr Surg, vol 2, pp 437, 1967.
6. Fraser GR, "The causes of profound deafness in childhood," Baltimore, Johns Hopkins Press, pp 90-132, 1976.
7. Passarge E, "Genetic heterogeneity and recurrence risk of congenital intestinal aganglionosis", Birth Defects, vol no 2, pp 63-67, 1972.